

Laryngeal Chondrosarcoma: A Case Report with Review of Literature

Chenna H*, Berhil H, Toulba H, Mezouri I, Zaidi H, Kouhen F, El Kacemi H, Hassouni K, Kebdani T, El Gueddari BK and Benjaafar N

Department of Radiotherapy, National Institute of Oncology, Rabat, Morocco

Summary

The chondrosarcoma is an exceptional malignant cartilaginous tumor of the larynx. It is usually located at the cricoid cartilage and is characterized by a low tendency to metastatic spread (low grade). It is a worrisome tumor because of its siege and the surgical difficulties that it imposes. The imagery is used to specify the origin of the cartilaginous tumor, its extension and the type of surgical treatment. The diagnosis often requires the use of a confrontation radiological, endoscopic and pathologic. Treatment is primarily surgical, endoscopic, which can be either a "partial open surgery".

This treatment is based on resections of large, sometimes mutilating, and requires in such a localization multidisciplinary collaboration between ENT, vascular surgeon and radiotherapist. The prognosis is generally good. In light of this new case of chondrosarcoma of the larynx and literature data, we'll provide an update on the clinical aspects, diagnosis and treatment.

Keywords: Chondrosarcoma; Laryngeal neoplasms; Imaging; Surgery; Radiotherapy

Introduction

Chondrosarcoma is a malignant cartilaginous tumor of the larynx exceptional. Frequency, compared to other cancers of the cartilage, is less than 1%, while that associated with cancer of the larynx is located between 0.07% and 0.2%. The pathogenesis is unknown. It can occur at any age but is most often described as an adult and there is a male predominance (sex ratio 5:1). Chondrosarcoma is a malignant tumor of very slow growth of the proliferation of hyaline cartilage. It is rarely found at the head and neck, and is normally described in the pelvis, femur, ribs, humerus, scapula, fibula, sacrum and sternum. Only 10-12% of chondrosarcoma are located at the head and neck. In the larynx, the most common location is posterolateral region of the cricoid cartilage. It is exceptionally described in the lower portion of the laryngeal surface of the thyroid cartilage or the arytenoid cartilages. The regional and distant metastases when tumors of low malignancy are uncommon. Surgery is the treatment of choice and can be either endoscopic or partial "open surgery" or a total laryngectomy, depending on the extension and histological grade of the tumor. Chondrosarcoma of the larynx generally has a good prognosis (low grade).

Case Report

This is Mr. BM, 55 years old, non smoking, who was sent from the ENT department, where he consulted for the first time for a progressive dysphonia, an anterior cervical mass of slow growth lasting for one year with laryngeal dyspnea why the patient had emergency tracheostomy. Indirect laryngoscopy showed a tumor of the right hemi-larynx interesting all three floors. Computed tomography of the larynx revealed a tumor of the larynx right hemi relevance to all three floors, measuring 35 mm in diameter and invading hyo-thyro-epiglottic space, thyroid cartilage, cricoid cartilage and the isthmus and the right thyroid lobe with mediastinal lymphadenopathy and neck (Figure 1). Staging and distance search of a primary cancer, including a CT scan of the chest and abdominal ultrasound was negative. Histological study of biopsy performed revealed a chondrosarcoma grade 2 classification O'Neal and Ackerman. Surgical treatment consisted of total laryngectomy with right mediastinal and récurrentiel lymph node dissection. The pathological study of the surgical specimen was in favor of a laryngeal chondrosarcoma infiltrating the thyroid and cervical soft tissues with 29 negative nodes. The postoperative course was uneventful. The

patient underwent adjuvant radiotherapy to the tumor bed by photons at a dose of 50 Grays, 2Grays/fraction of 5 weeks. This irradiation was without incident. After 30 months of follow up, the patient is in good locoregional and distance control.

Discussion

The cartilaginous tumors represent less than 1% of laryngeal tumors. Chondrosarcoma of low grade malignancy accounting for 95% of these tumors, they occur most often in men (sex ratio: 5/1), between 50 and 70 years, with an average age of 66. The preferred site is the cricoid cartilage (75%) followed by the thyroid cartilage (17%), the arytenoid (5%) and epiglottis (2%) [1].

The exact pathophysiology is not yet clear, some etiopathogenic hypotheses attribute the disease to the presence of local trauma, an abnormal ossification, chronic inflammation and metabolic disorders associated with vieillissement [2].

The clinical symptoms are often gradual, polymorphic and depend on the site of the tumor. The disease can remain asymptomatic for a long time and be discovered in the Assessment of the neck mass. Dyspnea and dysphonia are the most common presenting symptoms. Bradypnea on the two-time respiratory reflects a development of the intraluminal lesion. Dysphagia may be secondary to compression of the esophagus by the tumor. Other rarer clinical signs were reported: persistent dry cough, stridor, sleep apnea, or cervical lymphadenopathy [3-5].

The laryngotracheoscopy can study well the siege and the macroscopic appearance of the lesion, often lobular form of nodules whitish or bluish, sometimes translucent, sometimes grayish or opaque, which may include yellowish grains corresponding to calcifications.

*Corresponding author: Chenna Hanane, Department of Radiotherapy, National Institute of Oncology, Rabat, Morocco, E-mail: chennahanane@hotmail.fr

Received July 18, 2013; Published May 25, 2013

Citation: Chenna H, Berhil H, Toulba H, Mezouri I, Zaidi H, et al. (2013) Laryngeal Chondrosarcoma: A Case Report with Review of Literature. 2: 680. doi:10.4172/scientificreports.680

Copyright: © 2013 Chenna H, et al. This is an open-access article distributed under the terms of the Creative Commons Attribution License, which permits unrestricted use, distribution, and reproduction in any medium, provided the original author and source are credited.

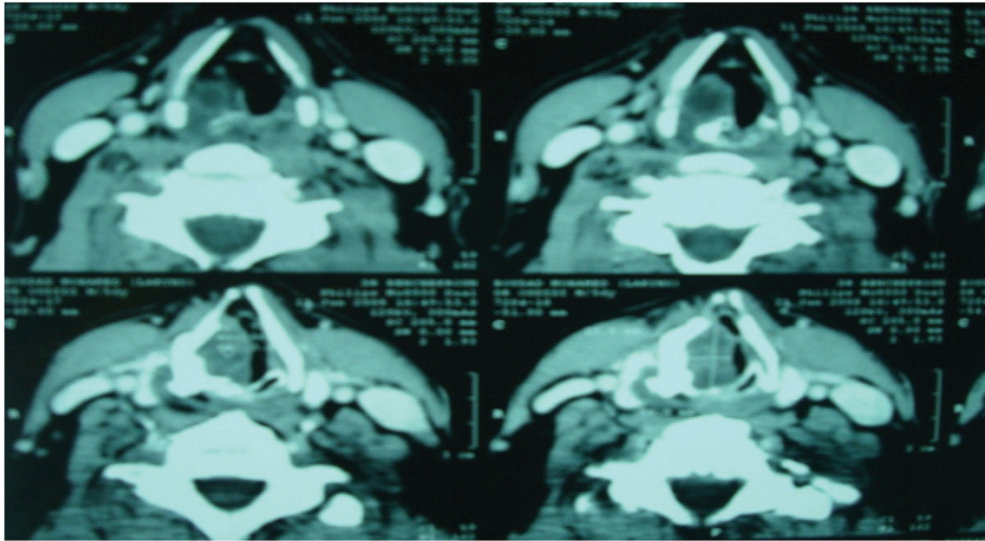


Figure 1: CT axial section: Process limited lesion poorly subglottic at the expense of the left posterolateral wall of the cricoid cartilage and containing calcifications in the center (CT scan).

Lesional surface is bumpy, covered with a pseudocapsule with an occasional break mucosa. This review is completed by multiple biopsies [6].

The radiographic appearance is variable, it provides to suspect the diagnosis in front of the aggressive nature of the lesion. Computed Tomography (CT) is the modality of choice to appreciate the nature, the location and extent of cartilaginous tumors. These tumors, focusing on the cartilage, are the smooth contours, well defined, hypodense with moderate contrast enhancement. Characteristics calcifications are found in 80% of cases. The cartilage lesion respects adjacent structures, pushing them back without invading its. CT can also determine the degree of laryngeal obstruction. Magnetic Resonance Imaging (MRI) is less specific but more precise in defining the extension and the relationship of the tumor with surrounding structures. Imaging cannot distinguish chondroma chondrosarcoma of low grade but, specifying the place and the extent of the tumor, it can determine the type of treatment (voice conservation or radical) [2,4,7,8].

Only the preoperative biopsy is required to confirm the diagnosis of chondrosarcoma showing many immature chondrocytes with atypia. Microscopic analysis also helps determine the histological grade of malignancy. Histologically, four types of chondrosarcoma can be identified: classic or myxoid, mesenchymal, dedifferentiated and clear cell. Compared to the classic type, the most common, the last three seem much more rare, aggressive and poor prognosis. The classification divides EVANS chondrosarcoma into three grades of malignancy: The low-grade (Grade 1): characterized by chondrocytes with small dense nuclei, binucleate cells, low mitotic activity and cellularity. Medium and high grade (Grade 2 and 3): characterized by increased cellularity, numerous multinucleated and binucleated cells and numerous mitoses. Other than moderately or undifferentiated chondrosarcoma (grade II and III), those who are very well differentiated, grade I, may pose the problem of differential diagnosis with benign cellular chondroma, firstly because of the lack of precise boundaries between low-grade chondrosarcoma and chondroma and other due to malignant transformation of chondroma [1,6].

The treatment of laryngeal chondrosarcoma is surgical, with

concern for conservation of function, while respecting the rules of cancer surgery. The main problems with this surgery are the risk of recurrence and postoperative stricture. The treatment of choice for symptomatic tumors is surgical in the absence of contraindications, in case of diagnostic uncertainty. The resection depends on the stage of the tumor extension and is subject to many controversies, the well limited tumors justify a tumor resection in healthy zone followed by a closure by local flap without calibration. In earlier position, the risk of stenosis is higher and has to consider a tummy army by the introduction of a silicone stent cricotracheal. For larger lesions (greater than 2 cm), the restoration of continuity is called to the establishment of a Montgomery tube or at the resection, anastomosis thyrotrachéale. Achieving unity cricoaryténoïdienne, imposes a subtotal laryngectomy Pearson type if the injury does not exceed the median line or total laryngectomy if the invasion is bilateral [9,10].

The place of radiotherapy is not yet very precise. However, for many authors, chondrosarcomas are radio- and chemoresistant. Radiation therapy can then be used only as palliative cases of residual tumor, recurrent or inoperable. Other authors have recently presented positive results with radiotherapy alone (60-70 Gy). A good local control of disease at three years, by the combination of neutrons and photons was achieved. According to most authors, radiotherapy should be performed only for the undifferentiated chondrosarcoma as adjuvant therapy after surgery. Chemotherapy does not seem to have a place in the curative treatment; it is reserved for palliative care in case of aggressive tumors with local invasion. Local recurrences of chondrosarcoma are common. Their reported incidence in literature varies from 35% to 40%. Metastases are not particularly common, and occur in 2-10% of cases. Lung and cervical lymph nodes are the sites most often affected. Due to the low metastatic potential and slowing tumor growth, survival at 10 years exceeds 95% and even the onset of recurrence did not significantly affect survival. The main prognostic factors are histologic grade, location, extent and quality of the initial resection [1,11,12].

Conclusion

Laryngeal chondrosarcoma is a rare tumor whose diagnosis is based

on the confrontation radiological, endoscopic and pathologic. It must be considered in any seemingly benign cartilaginous lesion, especially if the individual is age. The imagery is used to specify the origin of cartilage and tumor extension. Histological precise nature of the tumor and histological grade emerges as important prognostic factor. Its curative treatment is exclusively surgical. It is based on resections of extensive, sometimes disfiguring and requires in such a location multidisciplinary collaboration between ENT, vascular surgeon and radiotherapist. The prognosis is good even if metastases are described.

Conflict of Interests

The authors declare that there is no conflict of interests.

References

1. Rickert S, Buckmire R, Sulica L (2009) Cricoid chondrosarcoma presenting as breathy dysphonia. *Ear Nose Throat J* 88: 1144-1146.
2. De Cock M, Van Laer C, Vanwambeke K, Salgado R (2006) Chondrosarcoma of the larynx: a report of two cases and a review of the literature. *B-ENT* 2: 21-26.
3. Pignataro L, Peri A, Pagani D, Iudica F, Scaramellini G (2006) Cricoid chondrosarcoma coexisting with a thyroid mass: case report and review of the literature. *Tumori*, 92: 257-259.
4. Thompson LD, Gannon FH (2002) Chondrosarcoma of the larynx: a clinicopathologic study of 111 cases with a review of the literature. *Am J Surg Pathol* 26: 836-851.
5. Domenech Campos E, Navarro-Conde P, Campos Dana JJ, Fontal Alvarez M, Zaragosi Castelló JM, et al. (2002) Advanced stage laryngeal chondrosarcoma. *An Otorrinolaringol Ibero Am* 29: 473-481.
6. Faquin WC, Pilch BZ, Keel SB, Cooper TL (2000) Fine-needle aspiration of dedifferentiated chondrosarcoma of the larynx. *Diagn Cytopathol* 22: 288-292.
7. Wang SJ, Borges A, Lufkin RB, Sercarz JA, Wang MB (1999) Chondroid tumors of the larynx: computed tomography findings. *Am J Otolaryngol* 20: 379-382.
8. Obenauer S, Kunze E, Fischer U, Schmidberger H, Grabbe E (1999) Unusual chondrosarcoma of the larynx: CT findings. *Eur Radiol* 9: 1625-1628.
9. Merrot O, Gleizal A, Poupert M, Pignat JC (2009) Cartilaginous tumors of the larynx: endoscopic laser management using YAG/KTP. *Head Neck* 31: 145-152.
10. Coscarón Blanco E, Benito González F, Riva García B, Rico Marinas A, Kaiser Ramos C, et al. (2005) Chondrosarcomas of the larynx: diagnostic and therapeutic controversies. *An Otorrinolaringol Ibero Am* 32: 515-525.
11. Dailiana T, Nomikos P, Kapranos N, Thanos L, Papatheasiou M, et al. (2002) Chondrosarcoma of the larynx: treatment with radiotherapy. *Skeletal Radiol* 31: 547-549.
12. Leclerc JE (2008) Chondrosarcoma of the larynx: case report with a 14-year follow-up. *J Otolaryngol Head Neck Surg* 37: E143-147.