

## Cutaneous Malignant Melanoma in Calabar, South Nigeria

Asuquo ME<sup>1\*</sup>, Nwagbara VI<sup>1</sup>, Otei OO<sup>1</sup>, Bassey I<sup>2</sup> and Ugben T<sup>2</sup>

<sup>1</sup>Departments of Surgery University of Calabar Teaching Hospital, Calabar, Nigeria

<sup>2</sup>Departments of Pathology, University of Calabar Teaching Hospital, Calabar, Nigeria

### Abstract

**Background:** The incidence rates of malignant melanoma show substantial worldwide variations with the lowest rates reported in Asian populations. Plantar melanoma is common in sub-Saharan Africa.

**Methods:** Presented are patients with histologic diagnosis of malignant melanoma seen at the University of Calabar Teaching Hospital, Calabar from January 2000 to December 2009.

**Results:** Sixteen patients (12 males, 4 females and 15 darkly pigmented, 1 albino) whose ages ranged from 40-75 years (mean 56.0 years) accounted for 10% of skin malignancy. Plantar melanomas were observed on 15 patients while the albino had a lesion on the upper limb. Twelve nodular, 4 superficial spreading melanomas were observed, 4 patients had lymphadenopathy while one hospital mortality was recorded.

**Conclusion:** Plantar melanoma was the commonest form encountered possibly with trauma as a risk factor. This contrast sharply with the European pattern of presentation in which solar radiation is a major culprit. Education of patients, public and non-dermatologist regarding prevention, early detection and treatment of malignant melanoma would improve the outcome of the management.

**Keywords:** Malignant melanoma; Darkly pigmented; Albino

### Introduction

Over the past 20 years, the incidence of melanoma of the skin has increased throughout the world at the rate of approximately 5% per year [1]. In UK, the incidence of malignant melanoma (MM) the most malignant of all skin neoplasm has doubled in the past 10 years [2,3]. The incidence rates of MM show substantial worldwide variations [4]. The highest incidence in the world is found in Auckland, New Zealand [5]. The lowest rates are reported in Asian populations in China, Japan, and Singapore [4]. Twenty percent of the world's melanoma is seen in Black Africans and Asians [6]. Melanoma is an uncommon malignancy (8%) in our region of Calabar South Nigeria, in contrast with another region of the country, Kano, North Nigeria, where this aggressive tumour ranked second (34%) as the most prevalent malignancy [7] thus highlighting regional variation in prevalence. Plantar melanoma is common in sub-Saharan Africa [8,9]. This has prompted the speculation of trauma as an aetiological factor, as opposed to solar radiation, which is a major culprit in Whites [1,10]. We present this study to evaluate the pattern, possible risk factors and outcome of treatment in our facility and recommend measures for improved outcome.

### Patients and Methods

We evaluated patients with histologic diagnosis of MM who presented to the University of Calabar Teaching Hospital (UCTH), Calabar, Nigeria from January 2000 to December 2009 as part of our wider study of skin malignancies. The number of patients with MM was compared with total number of patients diagnosed with skin malignancy and total malignancies observed during the same period. The variables analyzed were age, sex, type and site of lesion, skin pigmentation together with outcome of treatment.

### Results

In total, 16 patients presented with MM were seen in the UCTH, Calabar during the study period (January 2000 to December 2009). These accounted for 10% of skin cancers observed during the same period and 1.2% of total malignancies. The ages ranged from 40 to 75 years (mean 56.0 years), 12 were males and 4 females (M: F =3:1). The

peak age was recorded in the 6th decade, and no lesion was observed in the first 3 decades, Table 1. Fifteen patients (94%) were darkly pigmented and the anatomical location of the lesions was on the foot while one albino (6%) with numerous actinic keratoses and a lesion located on the upper limb was observed. Four patients presented with groin lesions (lymphadenopathy), Figures 1 and 2. Twelve (75%) patients presented with nodular lesions while the superficial spreading melanoma (SSM) afflicted 4 (25%) patients. Late presentation with locally advanced lesions was a striking feature of this study with the largest foot lesion measuring 16 x 14cm. Majority of the patients volunteered a history of trauma, which was believed to be responsible for this lesion. All the patients presented first to tradomedical healers/chemist and this accounted for late presentation. The average period of

Age range (Years)	Gender		Total (%)
	M	F	
1 - 10			
11 - 20			
21 - 30			
31 - 40	2	1	3(19)
41 - 50	2		2(12)
51 - 60	4	2	6(38)
61 - 70	3	1	4(25)
71 - 80	1		1(6)
	12	4	16(100)

Table 1: Age/ Sex distribution.

\*Corresponding author: Dr. M E Asuquo, Department of Surgery, GPO Box 1891, Calabar, Nigeria, E-mail: [mauefas@yahoo.com](mailto:mauefas@yahoo.com)

Received September 18, 2010; Published August 28, 2012

**Citation:** Asuquo ME, Nwagbara VI, Otei OO, Bassey I, Ugben T (2012) Cutaneous Malignant Melanoma in Calabar, South Nigeria. 1:307. doi:10.4172/scientificreports.307

**Copyright:** © 2012 Asuquo ME, et al. This is an open-access article distributed under the terms of the Creative Commons Attribution License, which permits unrestricted use, distribution, and reproduction in any medium, provided the original author and source are credited.

presentation to our facility from when lesion was first noticed ranged from 3 to 48 months (mean 12 months).

Diagnosis was made by histology, which revealed 15 melanotic lesions described on the darkly pigmented while the albino had amelanotic melanoma, Figure 3. Fifteen patients had excision while 3 patients who presented with regional lymphadenopathy had in addition adjuvant chemotherapy (methotrexate, cisplatin). There was a fatal outcome in a patient who presented with a fungating right foot

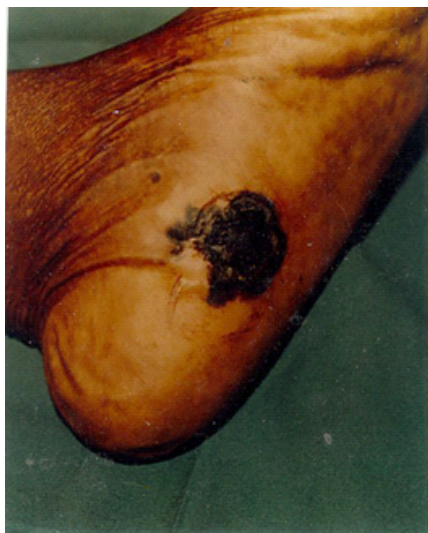

Figure 1: Clinical photograph of plantar melanoma.

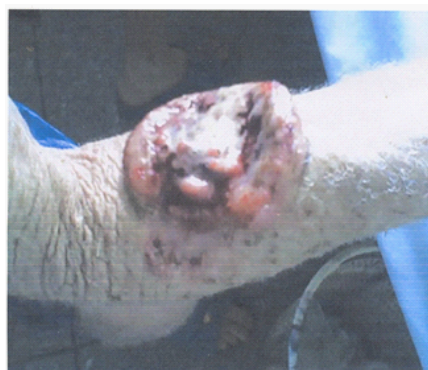

Figure 2: Clinical photograph of malignant melanoma in an albino.

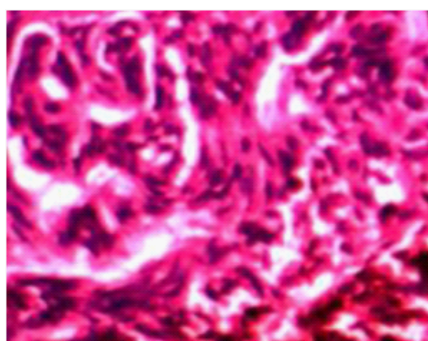


Figure 3: Photomicrograph of malignant melanoma, H&E, x 40.

lesion of 4 years duration. He also had inguinal lymphadenopathy, lymph oedema, and hepatomegaly. Follow up period was generally poor with a mean period of 4 months.

## Discussion

Malignant melanoma encountered in Calabar, south Nigeria accounted for 10% of skin malignancy, and this compared with our previous study (8%). These contrast with the northern region of Nigeria where it accounted for 34% (Kano), [8], 37.4% (Jos), [11]. However, melanomas are 10-20 times more common in fair-skinned Caucasians than in black individuals [1].

Our cases showed predominantly a male preponderance, while some reports from other parts of Nigeria showed a slight male preponderance [6,12,13]. However, a report from Cameroon found a female preponderance [14]. The peak age in our series was the 6th decade, which is similar to other reports [6,11,14]. Melanoma was not found in our study in the first 3 decades, a similar experience was recorded in Cameroon [14], which has a common border with Calabar, Nigeria. The rarity of this tumour before puberty suggests hormonal influences may be additional risk factor [11].

The location of skin cancer can be helpful in predicting the type of malignancy as well as the possible risk factors [6, 15]. All the lesions in this study were plantar and mostly nodular which is the usual pattern seen in Blacks and Asians [11], this highlights the role of non-solar risk factor. This form of MM associated with nonsolar factor such as trauma has also been found in African Americans and in Bantus resident in the urbanized townships of South Africa [11,16]. Studies in Africa suggest trauma as a major culprit in melanoma, which may arise from existing epidermal melanocytes [6,17,18]. It is also possible that lesions will arise from melanotic naevus and hyper-pigmented macules common on the plantar surface in blacks [19]. This is in contrast to the experience in United States and Canada where most of the lesions were observed on the upper limbs and trunk with solar radiation as the major culprit [4].

Albinism and solar radiations are known risk factors for skin cancer and high levels of solar radiation increase the risk of the three major forms of skin cancer [20]. The only lesion that was non-plantar in location was observed on an albino on the upper limb with clinical evidence of actinic keratoses highlighting solar radiation as the possible culprit in aetiopathogenesis of the lesion. This contrast sharply with the darkly pigmented patients who presented with plantar lesions. However, in the albinos the presentation was in keeping with the experience with the Caucasians [4]. This was the first case of MM in an albino of Negroid ancestry in our centre [21]. In deed, a review of medical literature failed to reveal any case of MM reported in Nigeria [22-24] and South Africa [25]. However, Luande et al in Dar-es-Salam, Tanzania reported a case of MM in an albino [26].

Late presentation was a common underlying issue in our patients who first presented to tradomedical healers/chemists. However, in other settings suspicious pigmented lesions may first present to their primary care physicians hence the need for both the public and non-dermatologist to be educated regarding prevention and early detection of MM [27].

Surgical removal remains the mainstay of treatment of patients with MM as indicated in all our patients except the one with a fatal outcome. Adjuvant, neoadjuvant, and palliative procedures such as radiotherapy, chemotherapy, and immunotherapy are additional treatment options [28]. Malignant melanoma is an uncommon skin

malignancy in our region when compared to Northern Nigeria. There was a male preponderance in our study. However, the presentation was similar to that reported in other parts of Nigeria and Africa with plantar lesions predominating thus highlighting possibly trauma as a possible risk factor. One Nigerian albino presented with MM on the upper limb with solar radiation as a possible risk factor in keeping with the pattern seen in European skin cancer. Late presentation was a common issue highlighted in this study.

## Conclusion

In conclusion, plantar melanoma was the commonest form encountered with trauma as a possible risk factor. Education of patients, the public and non-dermatologist regarding prevention and early detection of MM would improve the outcome of the management of this lesion.

## References

1. Koh HK (1999) Cutaneous melanoma. *N Engl J Med* 3: 171-182.
2. Dauda MM, Shehu SM (2005) Malignant melanoma: A Review. *Niger Postgrad Med J* 12: 125-130.
3. Mckay AJ (1997) Surgical management of malignant melanoma. *Br J Surg* 84: 5-7.
4. Desmond RA, Soong SJ (2003) Epidemiology of Malignant melanoma. *Surg Clin Nor Am* 83: 1-29.
5. Jones WO, Harman CR, Ng AKT (1999) Incidence of malignant melanoma in Auckland, Newzealand; highest rates in the world. *J Surg* 23: 732-735.
6. Samaila MOA, Rafindadi AH (2006) Pattern of Cutaneous Malignant melanoma in Zaria, Nigeria. *Ann Afr Med* 5: 16-19.
7. Asuquo ME, Ngim O, Ugare G, Omotoso J, Ebughe G (2008) Major Dermatological malignancies encountered in a Teaching Hospital surgical department in South Nigeria. *Am J Clin Dermatol* 9: 383-387.
8. Ochicha O, Edino ST, Mohammed AZ, Umar AB (2004) Dermatological malignancies in Kano, Northern Nigeria A histopathological review. *Ann Afr Med* 3: 188-191.
9. Asuquo ME, Ebughe G (2009) Cutaneous cancers in Calabar, Southern Nigeria. *Dermatol online J* 15: 11.
10. Diepgen TL, Mahler V (2002) The epidemiology of skin cancer *Br J Dermatol* 61: 1-6.
11. Mohammed AZ, Manasseh AN, Mandong BM, Edino ST (2003) Histopathological study of malignant melanoma in highlanders. *Nig J Surg Res* 5: 18-22.
12. Adigun IA, Buhari MO, Abubakar AM (2005) Malignant melanoma in Ilorin, Nigeria: Clinico-Pathological Pattern and Problems. *Nig J Surg* 11: 26-30.
13. Yiltok SJ, Igun GO (2004) Prognostic indices in advance malignant melanoma of the foot. *Nig J Surg* 10(2): 43-6.
14. Mbuagbaw Pisho C, Bengondo CM, Kagoum B, Takongino S (2007) Malignant melanoma in Cameroon. *The Internet J of Surg* 9.
15. Asuquo ME, Bassey EE (2009) Significance of the Anatomical distribution of major skin malignancies in Calabar, Southern Nigeria. *Sudan J Dermatol* 7: 14-20.
16. Edington GM, Gilles HM (1976) Miscellaneous disorders in: *Pathology in the tropics*. Arnold London 690-752.
17. Yakubu A, Mabogunje OA (1995) Skin cancer in Zaria, Nigeria. *Trop Doct* 25: 63-67.
18. Out AA (1985) Thorn injury preceding malignant melanoma of the foot in Nigerians. *Lancet* 26: 220-221.
19. Lewis MG (1967) Malignant melanoma in Uganda (The relationship between pigmentation and malignant melanoma on the soles of the feet). *Br J Cancer* 21: 488-495.
20. Asuquo ME, Ngim O, Ebughe G, Bassey EE (2009) Skin cancer amongst four Nigerian albinos. *Int J Dermatol* 48: 636-638.
21. Efem SEE, Asuquo ME, Ebughe G (2009) Malignant melanoma in an albino. *Sudan JMS* 4: 403-405.
22. Yakubu A, Mabogunje OA (1993) Skin cancer in African albinos. *Acta Oncol* 32: 621-622.
23. Datubo-Brown DD (1991) Primary malignant tumours in Nigerians. *J Natl Med Assoc* 83: 345-348.
24. George AD, Oqunbiyi AD, Daramola OOM, Campbell OB (2005) Albinism among Nigerians with malignant melanoma. *Trop Doct* 35: 55-56.
25. Kromberg JG, Castle D, Zwane EM (1989) Albinism and skin cancer in South Africa. *Clin Genet* 36: 45-52.
26. Luande J, Henschke CI, Mohammed N (1985) The Tanzania human albino skin. *Natural history*. *Cancer* 55: 1823-1828.
27. Lang PG Jr (1998) Malignant melanoma. *Med Clin North Am* 82: 1325-1358.
28. Gohl J, Hohenberger W, Merkel S (2009) Malignant melanoma. *Chirurg* 80: 559-567.