

## Delayed Posthypoxic Leucoencephalopathy: Is a Rare Condition in Patients after Episodes with Hypoxia Due to Drug Overdose with Opioids, Benzodiazepines and Barbiturates, Among Other Causes

Moshgan Amiri\* and Line Sofie Lunde Larsen

Department of Neurology, University Hospital of Copenhagen, Denmark

\*Corresponding author: Moshgan Amiri, Resident, Department of Neurology, University Hospital of Copenhagen, Denmark, Tel: 0045 23 64 01 77; E-mail: moshgan.amiri.02@regionh.dk

Received date: April 17, 2017; Accepted date: May 03, 2017; Published date: May 10, 2017

Copyright: © 2017 Amiri M, et al. This is an open-access article distributed under the terms of the Creative Commons Attribution License, which permits unrestricted use, distribution, and reproduction in any medium, provided the original author and source are credited.

### Abstract

Patients suffering from acute hypoxic episodes with respiratory failure and initial recovery, may in rare occasions present with neurological and neuropsychological symptoms occurring 2 to 4 weeks after recovery from the hypoxic episode. This rare entity is named Delayed Posthypoxic Leucoencephalopathy (DPHL). The patients present with typical MRI-findings of bilateral subcortical white matter lesions. The primary hypoxic episodes might, among other causes, be due to drug overdose with opioids, benzodiazepines and barbiturates. There is no evidence-based treatment for the condition and the majority of patients with DPHL recover spontaneously.

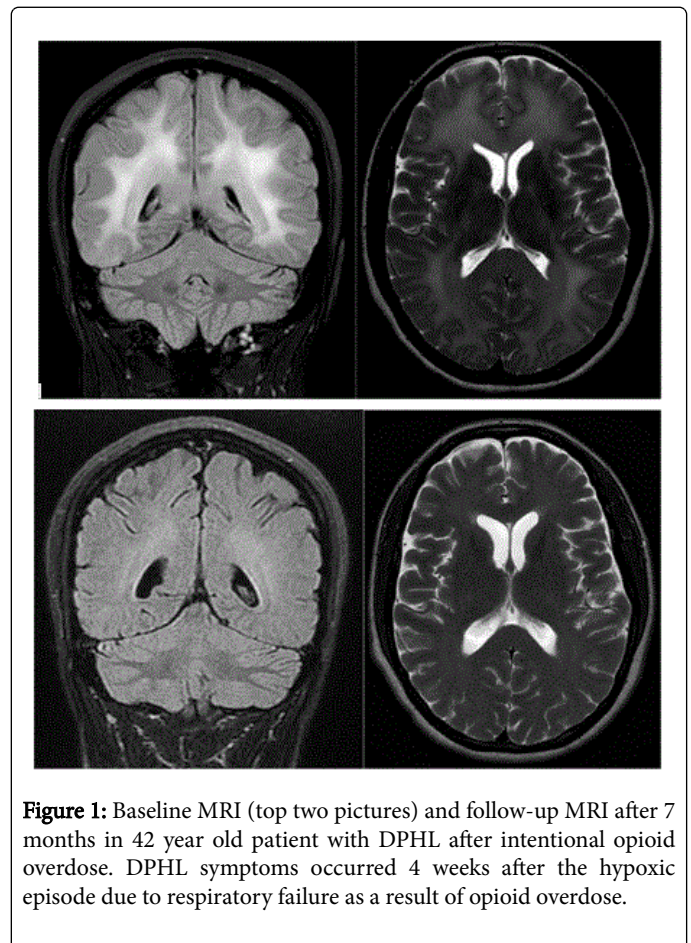
**Keywords:** DPHL, Drug overdose, Hypoxic episodes

### Introduction

Delayed Posthypoxic Leucoencephalopathy (DPHL) is a rare condition. Patients present with subacute onset of neurological and neuropsychological symptoms after an episode of acute hypoxia with initial recovery [1-3]. DPHL typically occurs 1 to 4 weeks after an episode of acute hypoxia. Hypoxia may be due to respiratory failure associated with an overdose of opioids, benzodiazepines or barbiturates [4-6]. Previous case reports of DPHL are after respiratory failure due to carbon monoxide intoxication, cardiac arrest or strangulation [3].

### Clinical presentation

DPHL is a rare condition primarily described in case reports, with the earliest reports from 1936 [1]. This makes detection of the condition challenging in a clinical setting, and may give rise to extensive and expensive paraclinical investigations. The presenting symptoms of DPHL is typically a subacute onset of neurological and neuropsychological symptoms like fluctuating cognitive impairment with memory- and attention deficit, parkinsonian symptoms with rigidity, tremor and unstable gait, psychiatric symptoms with delusions, hallucinations, mood swings, agitation and apathy. Other reported symptoms are hyper reflexia, increased tone, ataxia and global weakness. In the majority of case reports patients recover within a year to their baseline or near baseline neurological status [2-4].



**Figure 1:** Baseline MRI (top two pictures) and follow-up MRI after 7 months in 42 year old patient with DPHL after intentional opioid overdose. DPHL symptoms occurred 4 weeks after the hypoxic episode due to respiratory failure as a result of opioid overdose.

Figure 1 shows a typical MRI of the brain showing symmetrical bilateral, subcortical diffuse white matter lesions. The same figure also

illustrates remission of the white matter changes at a follow-up scan 7 months after initial presentation of symptoms [5].

DPHL after intentional opioid overdose. DPHL symptoms occurred 4 weeks after the hypoxic episode due to respiratory failure as a result of opioid overdose.

A thorough patient history is essential to identify DPHL. The condition is primarily based on a typical time course with hypoxia, initial recovery and sub-acute onset of neurological symptoms 2-4 weeks after initial hypoxic episode. Paraclinical work-up with MRI, lumbar puncture, EEG and blood samples play an important role in differentiating DPHL from other causes of neurological deterioration such as neuro-infections, metabolic encephalopathy and non-convulsive status epilepticus.

The pathophysiology of DPHL is not known. Myelin-related proteins as arylsulfatase A, ischemic-based necrosis of oligodendrocytes and inflammatory and oxidative processes are suspected to be involved [3].

There is no curative treatment for the condition. The treatment is in character supportive. Based on the theory of involvement of inflammatory and oxidative processes in the pathophysiology of DPHL, treatment with high dose anti-inflammatory drugs like prednisolone and antioxidants have been tried with various efficacies. None showing convincing effect [3,5-7].

## Conclusion

DPHL is a rare condition seen in patients with a previous history of acute hypoxic episodes with initial recovery and after a symptom free

interval of 1 to 4 weeks the development of a sub-acute onset of neurological and neuropsychological symptoms.

The hypoxic episodes may be due to drug overdose with opioids, benzodiazepines or barbiturates. The literature on the condition is primarily case reports. To identify this condition a thorough medical history is essential. Paraclinical work up is important to differentiate DPHL from other conditions that might cause a similar neurological deterioration.

## References

1. Shillito F, Drinker C, Shaughnessy T (1936) The problem of nervous and mental sequelae in carbon monoxide poisoning. *JAMA* 106: 669-674.
2. Shprecher D, Mehta L (2010) The syndrome of delayed post-hypoxic leukoencephalopathy. *NeuroRehabilitation* 26: 65-72.
3. Zamora CA, Nauen D, Hynecsek R (2015) Delayed posthypoxic leukoencephalopathy: A case series and review of the literature. *Brain Behav* 5: e00364.
4. Betts AM, Ritter JL, Kubal WS (2012) Reversible delayed posthypoxic leukoencephalopathy after drug overdose: MRI findings in a collection of patients. *Emerg Radiol* 19: 165-173.
5. Amiri M, Larsen LS (2016) Delayed posthypoxic leukoencephalopathy after suicide attempt with opioids. *Ugeskr Laeger* 19: 178.
6. Molloy S, Soh C, Williams TL (2006) Reversible delayed posthypoxic leukoencephalopathy. *AJNR Am J Neuroradiol* 27: 1763-1765.
7. King F, Morris NA, Schmahmann JD (2015) Delayed posthypoxic leukoencephalopathy: Improvement with antioxidant therapy. *Case Rep Neurol* 7: 242-246.