

## Reconstruction of Chronic Achilles Tendon Rupture by V-Y Gastrocnemius Flap and Peroneus Brevis Transfer

Yousuf M Khira\* and Mohammed A A Gheith

Faculty of Medicine, Zagazig University, Egypt

\*Corresponding author: Yousuf M Khira, Assistant professor, Faculty of Medicine, Zagazig University, Egypt, Tel: 00201005624590; E-mail: [yousufmmkh@gmail.com](mailto:yousufmmkh@gmail.com)

Rec date: Aug 17, 2016; Acc date: Sep 12, 2016; Pub date: Sep 19, 2016

Copyright: © 2016 Khira YM, et al. This is an open-access article distributed under the terms of the Creative Commons Attribution License, which permits unrestricted use, distribution, and reproduction in any medium, provided the original author and source are credited.

### Abstract

**Purpose:** Reporting the outcome of the modified peroneus brevis (PB) transfertechnique in treating 26 patients with chronic rupture of Achilles tendon (AT).

**Methods:** The diagnosis was neglected acute AT rupture in ten patients, ten with achronic rupture, re-rupture of the tendon in four cases, and Achilles xanthoma in two cases. The gap after debridement was 6 cm in average (range 4-8). The technique was V-Y gastrocnemius flaps of the ruptured AT in addition to peroneus brevis transfer. AOFAS score and isokinetic evaluation were used for functional assessment of ankle plantar flexion torque deficit in average 36 months follow up period (range 24-54 months).

**Results:** Significant improvement of the AOFAS score at latest follow up. No re-rupture nor major complication, particularly of wound healing, was observed, isokinetic testing at 30 degrees/second and 120 degrees/second revealed a significant average decrease of  $28 \pm 11\%$  and  $36 \pm 4\%$ , respectively, in plantar flexion peak torque. Although strength deficit persisted at latest follow up, functional improvement was significant without morbidity due to (PB) harvesting.

**Conclusion:** The surgical technique of V-Y myotendinous advancement of gastrosoleus tendon augmented by modified PB transfer for the treatment of chronic or neglected ruptures of AT with a gap of 6 cm length or more is a successful technique leading to high percentage of repair site healing and achieved excellent functional outcome.

### Introduction

The incidence of tendo-achilles rupture in the patients 30-40 years of age is increased specially in athletics to reach 75% of all cases [1]. The tendon rupture is called neglected when the treatment is delayed more than four weeks from the date of injury [2]. The percentage of misdiagnosis of Achilles tendon ruptures may reach 20% [3]. The delay in treatment of AT ruptures results in soft tissue retraction with degeneration of the tendon filling the gap between the ruptured ends with fibrotic scar tissue which leads to marked functional disability [4]. In neglected or chronic ruptures of Achilles Tendon (AT), the retraction and atrophy of the tendon ends create a gap filled with scar tissue and fibrosis which make the reconstruction difficult. The extent of the gap and the potential recovery of the muscle are factors that affect the repair after reconstruction [5-7].

In the literature, the V-Y myotendinous advancement of the (AT) augmented by multiple transfers like gastrocnemius soleus complex [1], Bosworth [7] technique (a "turndown" of proximal tissue of the (AT)). In the study of Us et al. [8], they reported 23% reduction in peak torque of the tendon after a V-Y lengthening technique for neglected AT ruptures. Therefore, tendon transfer for augmentation of the V-Y advancement was recommended to augment the repair which requires lengthening to approximate the tendon ends for repair to add strength to the plantar flexion of the ankle joint. Many techniques for tendon transfers that augment the AT repair as peroneus brevis (PB) tendon [9], flexor digitorum longus (FDL) tendon [10], flexor hallucis longus (FHL) tendon [11]. Different reports of these procedures have yielded

satisfactory clinical results but the ankle flexion strength and peak torque deficits were persisted [1,7,8,10-12].

The aim of this study was reporting the clinical results of the modified (PB) transfer for augmentation of V-Y myotendinous advancement in treatment of 26 patients presented with chronic AT rupture.

### Material and Methods

Through the period from March 2010 to September 2015, twenty six patients with chronic AT rupture were treated using the technique of V-Y advancement repair augmented with PB tendon transfer.

The mean age of patients at the time of surgery was 37.5 ranged from 25 to 50 years.

There were twenty men and six women with the right side affected in twenty patients and the left side in six without bilateral cases. The mean time elapsed from injury to surgery was six weeks ranged from four to ten (Table 1).

The diagnosis of patients was acute missed ruptures in ten patients, chronic rupture in ten patients (eight of them received initial treatment as physiotherapy and foot ankle orthosis in two), incomplete rupture in four patients followed by complete avulsion, tendinosis led to spontaneous rupture in two patients.

The mean pre-operative American orthopedic foot and ankle society (AOFAS) score was (66 ± 5.8 SD) ranged from 58-74 points from total 100 points.

### Surgical Procedure

All surgery were done in prone position under spinal anesthesia. After application of a tourniquet, the limb was draped, and a lazy S skin incision from the middle of the leg to the insertion of AT was made saving the sural nerve.

The paratenon was incised, followed by debridement of fibrous tissue in the gap between tendon ends (Figure 1).

Measuring of the gap after removal of fibrosis was done. The range of gap length was 4 to 8 cm with average 6 cm ± (1.4 SD).

The next step was the generation of the V incision from the myotendinous junction making the arms approximately 1.5 times the gap between the tendon ends.

The repair of V incision in a Y fashion was done after advancement of the proximal tendon ends to reach the distal end or calcaneal insertion permitting end-to-end repair for defects.

The next step was harvesting the (PB) muscle tendon after identification of the muscle and tendon.

A second short lateral incision was performed to identify and suture the distal stump of (PB) tendon to that of Peroneus Longus (PL).

Intraosseous tunnel in the calcaneal posterior cortex was made using a drill bit 4.5 mm. After pulling of the (PB) tendon from lateral to medial to suture the tendon on itself with the ankle in 40 degrees of planter flexion.

Non-weight bearing below-knee cast in plantarflexion for three weeks. After removal of stitches a new cast in a neutral position was done for all patients for three weeks.

The rehabilitation program was begun at six weeks postoperative for range of motion followed by gradual weight bearing and muscle strengthening and was begun.

The contribution in sports was allowed six months postoperative.

The follow up period was ranged from 24 to 54 months (average 30 months ± 3.7 SD). The clinical outcome, postoperative complications, the intervals to work and sports recovery were assessed and recorded at last follow up.

Clinically the gait assessment, pain, range of movements of the ankle joint of motion of the, tip-toe stance, eversion of the foot, active planter flexion strength of the ankle.

The total functional outcome was evaluated according to (AOFAS) score [13]. The surgical wound and calf atrophy were assessed and recorded.

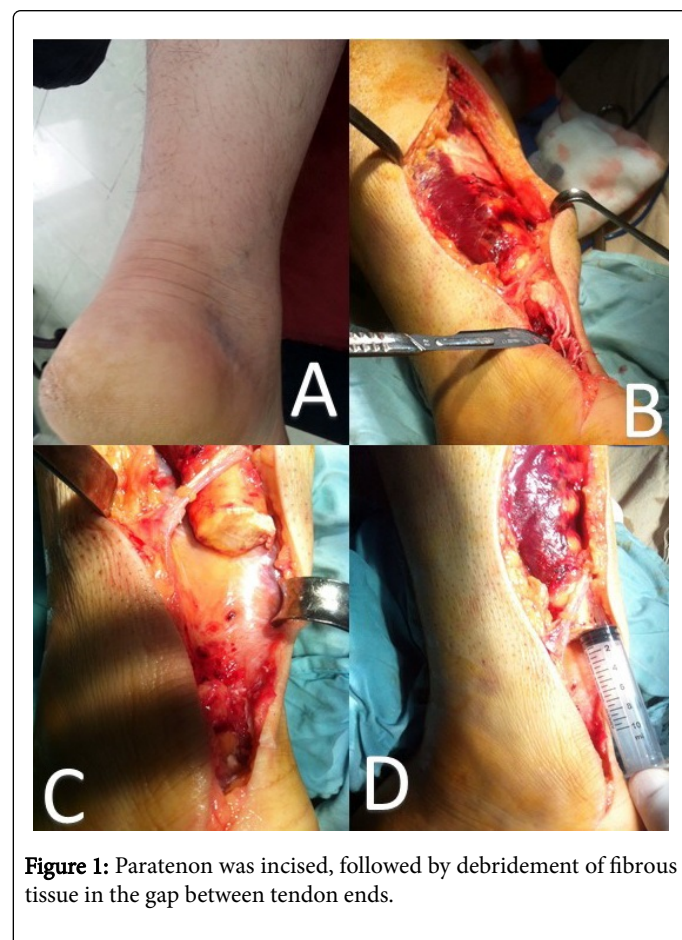
The isokinetic assessment was done using con-trex dynamometer (con-trex MJ; CMV AG, Dubendorf, Switzerland).

The standardized procedure was utilized via one independent operator.

Some authors used this technique to report the planter flexion and dorsiflexion isokinetic assessment and had good value [14,15]. Ten minutes before the test, warming up was done using an exercise bike with low resistance at (60 cycles per minute at 50 w).

Age (years)		Sex		Mean Time from injury (weeks)		Gap length(cm)		Follow up(months)	
Mean	Range	Male	Female	Mean	Range	Mean	Range	Mean	Range
37.5	25-50	20	6	6	4-10	6	4-8	30	24-54
Results									
(AOFAS) score (points)				Complications		Calf atrophy girth (cm)		Range of motion	
Preoperative		Postoperative		Wound infection	Reflex sympathetic dystrophy	Mean	Range	Dorsiflexion	Plantar flexion
Mean	Range	Mean	Range	4	2	1.2 cm	0.5-2	10 deg	45 deg
66	58-74	92.5	87-96					5-15	40-50

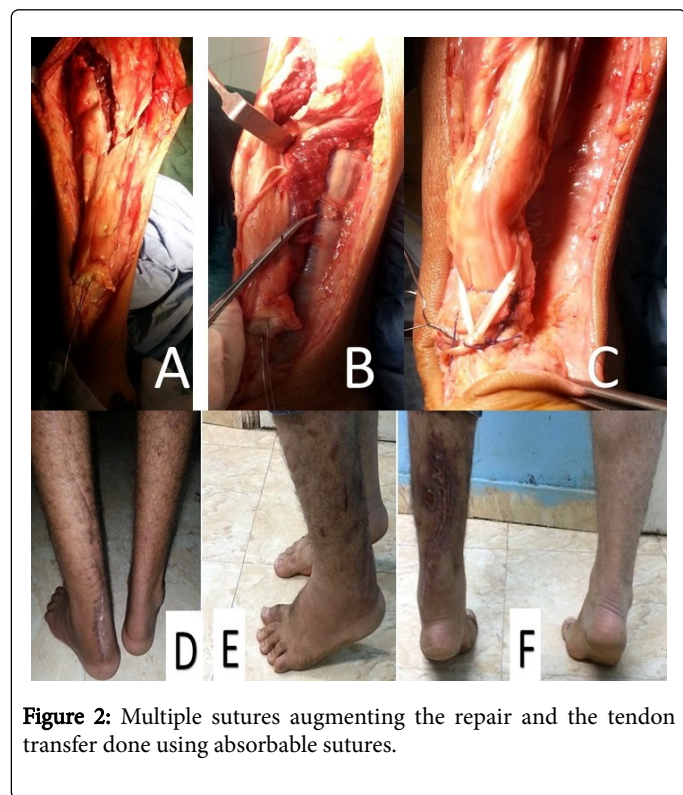
**Table 1:** Patient data and clinical results.



**Figure 1:** Paratenon was incised, followed by debridement of fibrous tissue in the gap between tendon ends.

Multiple sutures augmenting the repair and the tendon transfer were done using absorbable sutures (Figure 2), followed by the repair

of the paratenon, and then careful skin closure was done to avoid necrosis.



**Figure 2:** Multiple sutures augmenting the repair and the tendon transfer done using absorbable sutures.

The test begins with the patients in the prone position. The patient put his extended legs on the footplate. The lateral malleolus midpoint

was aligned with the mechanical axis of the dynamometer and taken as a fit axis of the ankle. The reference position of the foot is painless range from 90 degrees to maximum plantar flexion and from 90 degree to a maximal dorsiflexion for recording the range of motion comparing the normal to affected legs.

The test was done in two angular velocities, 30 (deg/sec) with five repetitions, and 120 (deg/sec) with 15 repetitions [16,17]. The noninvolved ankle was tested first then the affected. The data was then collected recording the Peak torque (N-m) for all angular velocities without gravity correction.

## Results

### Clinical outcome

The mean follow-up of the series was 36 months (range: 24 - 54). The mean AOFAS score was improved from  $66 \pm 5.8$  SD points (range 58-74) pre-operative to  $(92.5 \pm 6.2$  SD) points (range, 87-96) postoperative at latest follow-up which was significant ( $p=0.0001$ ) (Table 2). The range of motion was a mean of  $(10 \pm 2.8$  SD) degrees of dorsiflexion (range, 5-15 degrees) and a mean of  $(45 \pm 3.7$  SD) degrees of plantar flexion (range, 40-50 degrees) and was not significant ( $p=0.05$ ). The atrophy in calf was ranged from 0.5 cm to 2 cm with a mean of 1.2 cm of girth ( $p=0.045$ ).

All patients have no limitation of tip toe stance. The active foot eversion range was maintained during daily life activity, and during sports. Analysis of the results of isokinetic test was done and revealed that: when comparing the peak torque of plantar flexion of the affected ankle to the non-affected, there was decrease of  $28 \pm 11\%$  and  $36 \pm 4\%$ , in 30 deg/sec and 120 deg/sec respectively ( $p=0.0027$  and  $p=0.001$ ) (Table 2).

Plantar flexion 30 deg/ sec			Dorsiflexion 30 deg/ sec			Plantar flexion 120 deg/ sec			Dorsiflexion 120 deg/ sec		
Involved ankle	Non-ankle	Involved	Involved ankle	Non-ankle	Involved	Involved ankle	Non-ankle	Involved	Involved ankle	Non-ankle	Involved
84	93.4		35.6	35.6		43	50		22.8	22.8	
86	93.4		35.6	35.6		42	50		22.8	22.8	
90	93.4		35.6	35.6		40	50		22.8	22.8	
91	93.4		35.6	35.6		43	50		22.8	22.8	
92	93.4		35.6	35.6		40	50		22.8	22.8	
93	93.4		35.6	35.6		36	50		22.8	22.8	
86	93.4		35.6	35.6		40	50		22.8	22.8	
88	93.4		35.6	35.6		42	50		22.8	22.8	
90	93.4		35.6	35.6		43	50		22.8	22.8	
91	93.4		35.6	35.6		38	50		22.8	22.8	
92	93.4		35.6	35.6		40	50		22.8	22.8	
93	93.4		35.6	35.6		42	50		22.8	22.8	
90	93.4		35.6	35.6		40	50		22.8	22.8	
93	93.4		35.6	35.6		36	50		22.8	22.8	



91	93.4	35.6	35.6	38	50	22.8	22.8
84	93.4	35.6	35.6	43	50	22.8	22.8
86	93.4	35.6	35.6	42	50	22.8	22.8
92	93.4	35.6	35.6	40	50	22.8	22.8
93	93.4	35.6	35.6	36	50	22.8	22.8
90	93.4	35.6	35.6	43	50	22.8	22.8
91	93.4	35.6	35.6	38	50	22.8	22.8
93	93.4	35.6	35.6	36	50	22.8	22.8
86	93.4	35.6	35.6	40	50	22.8	22.8
86	93.4	35.6	35.6	40	50	22.8	22.8
88	93.4	35.6	35.6	42	50	22.8	22.8
90	93.4	35.6	35.6	43	50	22.8	22.8

**Table 2:** Isokinetic test results in comparison to normal side in 2 test speeds.

The overall rate of complications in this study was 23% and found in six patients. Four cases had superficial infection treated by dressing and intravenous cephalosporin. Reflex sympathetic dystrophy was diagnosed in two patients two months postoperative but improved at the end of the follow up. None of the patients has re-rupture through the follow-up period. The time elapsed postoperative for patients to return to work ranged from 2 to 6 months with a mean of 4 months, and recovery to sports was ranged from 4 to eight months with a mean of 6 months. Comparing the ability of patients to participate in sports to the level before injury, all patients have lower level of sports activity at the end of follow up period.

## Discussion

In this work 26 patients with Tendo-Achilles chronic rupture were treated with V-Y advancement augmented by a Peroneus Brevis (PB) transfer. The clinical outcome and function of the ankle were recorded in a mean follow-up of 36 months. The AOFAS was used to evaluate the all functional outcome with significant improvement of 34 points at the end of follow up. These results are comparable to other results in the literature [8,12,17-20].

Iso-kinetic assessment was recommended to be reliable in previous studies [14,15]. In this series, the peak torque value of planter flexion was significantly decreased (10%) in the affected ankle in relation to the non-affected one with the test at 30 deg/sec. Wapner et al. [17] using the same test recorded an average decrease in plantar flexion peak torque (41.8%). Hahn et al. [21] in a cohort study on 13 patients recorded a decrease in plantar flexion peak torque of 35% from normal side with the test at 60 deg/sec. They had ten patients with chronic ruptures of AT and three of them with tendinopathies followed up for average (46.5) months [21]. The same results were reported in another two studies on patients with chronic tendo-achilles rupture with some limitations [20,22]. Monroe et al. [23] have report on a small series of seven patients and had a decrease of (28%) in the peak torque with the iso-kinetic test at velocity of 30 deg/sec, 19 months after surgery. Wilcox et al. [20] in their study of 20 patients seventeen of them had tendinopathies, and the other three had chronic tendo-achilles

ruptures. They recorded a decrease in plantar flexion strength by 7% after an average of fourteen months follow-up. The test was performed at high speed (120 deg/sec) without recording the peak torque [20]. The differences in the results of this study may be due to PB transfer augmentation using V-Y myotendinous advancement of the ruptured AT.

Compared to FHL and FDL, the PB is a stronger in plantar flexion, this may owe to the direction of contractile force which resemble that of tendo-achilles, the fire phase of PB occurs with that of gastrocnemius-soleus complex, and the neurovascular bundle is safe due to its anatomical proximity. The reinforcement of planter flexion added by PB is superior benefit to the fascial advancement alone [24]. One of the main advantages of the PB muscle transfer is the increased blood supply to the area of repair through its muscle belly which extends distally into the avascular zone of AT. Otherwise, the FHL transfer has the advantage of maintaining the normal balance in the ankle movements because the donor and recipient muscles have the same function.

In the study of Hahn et al. [21] they reported complete integration of the FHL tendon in 60% of the patients. There was functional incorporation of the transferred muscle into plantar flexion. They owed this incorporation to hypertrophy more than 15% of FHL in 80% of all patients without degeneration in the muscle [21]. The mean disadvantage of FHL transfer reported by other authors is insufficiency for defects greater than 5 cm [18,19,24,25].

Some authors reported that the scar tissue between the stumps of the tendon can be reserved to keep the original length of the tendon and acts as a scaffold for the FHL transfer [3,18,21,24,26].

In this work, the fibrous tissue between the stumps of the tendon rupture ends of the tendon was excised to restore end to end healing of AT with suture on the PB transfer as this interposition scar tissue can interfere with the tendon healing.

The incidence of AT re-rupture after reconstruction in acute or chronic cases in the literature is 1.4-3.7% [27-31]. There was no case of re-rupture in our work through the follow up period. This series of 26

patient treated by PB transfer to augment the V-Y myotendinous advancement. All cases were diagnosed after 4 weeks of injury and classified chronic rupture of AT with main follow-up of 30 months which can be considered a long period compared to other studies in literature [8,32]. The limitation of this study may be in lack of control group.

## Conclusion

The surgical technique of V-Y myotendinous advancement of gastro-soleus tendon augmented by modified PB transfer for the treatment of chronic or neglected ruptures of AT with a gap of 6 cm length or more is a successful technique leading to high percentage of repair site healing and achieved excellent functional outcome.

## Ethics Approval and Consent to Participate

This prospective study was approved by our ethical committee for research according to the ethical standards of Helsinki 1964 declaration and its later amendments.

## Funding

The authors state that there has been no conflict of interest.

## References

1. Abraham E, Pankovich AM (1975) Neglected rupture of the Achilles tendon: treatment by v-y tendinous flap. *J Bone Joint Surg* 57: 253-255.
2. Park YS, Sung KS (2012) Surgical reconstruction of Chronic Achilles tendon ruptures using various methods. *Orthopedic* 35: e213-e218.
3. Lee KB, Park YH, Yoom TR, Chung JY (2008) Reconstruction of neglected Achilles tendon rupture using the flexor hallucis longus tendon. *Knee Surg Traumatol Arthrosc* 17: 316-320.
4. Lepow GM, Green JB (2006) Reconstruction of a neglected achilles tendon rupture with an Achilles tendon allograft: a case report. *J Foot Ankle Surg* 45: 351-355.
5. Boyden EM, Kitaoka HB, Cahalan TD, An KN (1995) Late versus early repair of Achilles tendon rupture: Clinical and biomechanical evaluation. *Clin Orthop Relat Res* 317: 150-158.
6. Thermann H, Hufner T, Tscherne H (2000) Achilles tendon rupture. *Der Orthopade* 29: 235-250.
7. Bosworth DM (1956) Repair of defects in the tendon achillis. *J Bone Joint Surg* 38: 111-114.
8. Us AK, Bilgin SS, Aydin T, Mergen E (1997) Repair of neglected Achilles tendon ruptures: procedures and functional results. *Arch Orthop Trauma Surg* 116: 408-411.
9. Teuffer AP (1974) Traumatic rupture of the Achilles Tendon: Reconstruction by transplant and graft using the lateral peroneus brevis. *Orthop Clin North Am* 5: 89-93.
10. Mann RA, Holmes GB, Seale KS, Collins DN (1991) Chronic rupture of the Achilles tendon: a new technique of repair. *J Bone Joint Surg Am* 73: 214-219.
11. Hansen ST (1991) Trauma to the heel cord. In: Jahss MH (ed.). *Disorders of the foot and ankle* (2nd edn.) W. B. Saunders, Philadelphia. pp: 2357.
12. Sebastian H, Data B, Maffulli N, Neil M, Walsh WR (2007) Mechanical properties of reconstructed Achilles tendon with transfer of peroneus brevis or flexor hallucis longus tendon. *Foot Ankle Surg* 46: 424-428.
13. Kitaoka HB, Alexander JJ, Adelaar RS, Nunley JA, Myerson MS, et al. (1994) Clinical rating systems for the ankle, hindfoot, midfoot, hallux and lesser toes. *Foot Ankle* 15: 349-353.
14. Cheseter R, Costa ML, Shepstone L, Donell ST (2003) Reliability of isokinetic dynamometry in assessing plantar flexion torque following Achilles tendon rupture. *Foot Ankle Int* 24: 909-915.
15. Woodson C, Bandy WD, Curis D, Baldwin D (1995) Relationship of isokinetic peak torque with work and power for ankle plantar flexion and dorsiflexion. *J Orthop Sports Phys Ther* 22: 113-115.
16. Kangas J, Pajala A, Ohtonen P, Leppilahti J (2007) Achilles tendon elongation after rupture repair: a randomized comparison of 2 postoperative regimens. *Am J Sports med* 35: 59-64.
17. Wapner KL, Pavlock GS, Hecht PJ, Naselli F, Walther R (1993) Repair of chronic Achilles tendon rupture with flexor hallucis longus tendon transfer. *Foot Ankle* 14: 443-449.
18. Elias I, Besser M, Nazarian LN, Raikin SM (2007) Reconstruction for missed or neglected Achilles tendon rupture with v-y lengthening and flexor hallucis longus tendon transfer through one incision. *Foot Ankle Int* 28: 1238-1248.
19. Kann JN, Myerson MS (1997) Surgical management of chronic ruptures of the Achilles tendon. *Foot Ankle Clin* 2: 535-545.
20. Wilcox DK, Bohay DR, Anderson JG (2000) Treatment of chronic Achilles tendon disorders with flexor hallucis longus tendon transfer/augmentation. *Foot Ankle Int* 21: 1004-1010.
21. Hahn F, Meyer P, Maiwald C, Zanetti M, Vienne P (2008) Treatment of chronic Achilles tendinopathy and ruptures with flexor hallucis tendon transfer: clinical outcome and MRI findings. *Foot Ankle Int* 29: 794-802.
22. Cetti R, Christensen SE, Jested R, Jensen NM, Jorgensen U (1993) Operative vs non operative treatment of Achilles tendon rupture: A prospective randomized study and review of the literature. *Am J Sports Med* 21: 791-799.
23. Monroe MT, Dixon DJ, Beals TC, Pomeroy G, Growley DL, et al. (2000) Plantar flexion torque following reconstruction of Achilles tendinosis or rupture with flexor hallucis longus augmentation. *Foot Ankle Int* 21: 324-329.
24. Den Hartog BD (2008) Surgical strategies: delayed diagnosis or neglected achilles tendon ruptures. *Foot Ankle Int* 29: 456-463.
25. Kissel CG, Blackledge DK, Crowley DL (1994) Repair of neglected Achilles tendon rupture: procedure and functional results. *J Foot Ankle Surg* 33: 46-52.
26. Young A, Redfern D J (2008) Simple method of local harvest and fixation of F H L in Achilles tendon reconstruction: technique tip. *Foot Ankle Int* 29: 1148-1150.
27. Stefan R, Cristian S, Fabienne G, Farshad M, Buck Fm, et al. (2013) Operative treatment of chronic irreparable achilles tendon rupture with large flexor hallucis longus. *Foot and Ankle Int* 34: 1100-1110.
28. Chih CW, Leou CL, Chao KH, Pei SH, Shiu BL, et al. (2009) Anatomic reconstruction of neglected Achilles tendon rupture with autogenous peroneal longus tendon by Endo Button fixation. *J Trauma* 67: 1109-1112.
29. Coull R, Flavin R, Stephens MM (2003) Flexor hallucis longus tendon transfer: evaluation of postoperative morbidity. *Foot Ankle Int* 24: 931-934.
30. Maffulli N, Waterston SW, Squair J, Reaper J, Douglas AS (1999) Changing incidence of Achilles tendon rupture in Scotland: a 15-year study. *Clin J Sport Med* 9: 157-160.
31. Myerson M S (1999) Achilles tendon ruptures. *Instr Course Lect* 48: 219-230.
32. Porter DA, Mannarino FP, Snead D, Gabel SJ, Ostrowski M (1997) Primary repair without augmentation for early neglected Achilles tendon ruptures in the recreational athlete. *Foot Ankle Int* 18: 557-564.