

## Dental Considerations in Dandy-Walker Malformation

Rungnapa Warotayanont<sup>1\*</sup>, Samuel Huang<sup>2</sup>, Ram Vaderhobli<sup>2</sup>, Juei Kao<sup>1</sup> and Thuan Le<sup>1</sup>

<sup>1</sup>Division of Pediatric Dentistry, Department of Oro-facial Sciences, University of California San Francisco, San Francisco, USA

<sup>2</sup>Department of Preventive and Restorative Dental Sciences, University of California San Francisco, San Francisco, USA

### Abstract

Dandy-Walker malformation is a rare congenital cystic malformation of the posterior cranial fossa. Patients with Dandy-Walker malformation show signs and symptoms of complex clinical manifestations, ranging from cranial nerve and cerebellar dysfunctions to extracranial abnormalities, which may pose challenges in dental management. In the current report, an 11 year-old boy with Dandy-Walker malformation presented with fracture of previously root canal-treated right maxillary central incisor. He was developmentally delayed, hearing and visually impaired, and presented with ataxic gait. Following clinical examination and behavioral assessment, dental treatments including gingivectomy, fiber post bonding and coronal restoration were planned and completed under the use of oral sedative medications. Patient tolerated the procedure well with no complications during and after the treatment. Despite the complexity of Dandy-Walker malformation, the careful review of medical history and proper behavioral assessment suggests that dental treatment can be achieved in the dental chair.

**Keywords:** Congenital cystic malformation; Cranial fossa; Extracranial abnormalities; Gingivectomy; Central incisor

### Introduction

Dandy-Walker malformation (DWM) is a congenital abnormality of the posterior cranial fossa with reported incidence of 1:25,000 to 1:35,000 live births [1,2]. The classic clinical trials of the DWM are absence of cerebellar vermis, cystic dilatation of the fourth ventricle, and the enlargement of posterior cranial fossa [3]. In approximately 80% of diagnosed DWM cases, the syndrome is accompanied by hydrocephalus and developmental delay [4]. Other posterior fossa malformations such as Dandy-Walker variant, mega-cisterna magna, Blake's pouch, and arachnoid cyst, show overlapped clinical features with DWM and are believed to be parts of the continuum of the syndrome [5-7]. The term Dandy-Walker Complex has been suggested to describe the diseases as spectrums opposed to separate entities [8].

The pathogenesis of DWM results from the disturbance of the cerebellar development during the fourth to seventh weeks of fetal development [3]. The etiology of DWM is unclear but is believed to result from the combination of environmental and genetic factors. Environmental factors including prenatal exposure to alcohol, teratogenic agents, certain types of medicines, maternal infection, and maternal diabetes, have been shown to contribute to the cause of DWM [9] more recently, the DWM causative genes *FOXC1* on human chromosome 6p25 and linked *ZIC1* and *ZIC4* on human chromosome 3q24 have been identified [10,11]. Affected individuals exhibit clinical presentations associated with the severity of the intracranial and extracranial anomalies. The enlargement of posterior fossa and the tumor mass compression causes an increase in intracranial pressure, which manifests clinically as headache, nausea, vomiting, and irritability. The dysfunction of cerebellum manifests as gait disturbance, ataxia, and hypotonia. Cranial abnormalities detected in DWM are spenium hypoplasia, abnormal cerebral gyri, aqueduct stenosis, dolichocephaly, and malformation of dentate nucleus in the brain stem [12,13]. The intracranial abnormalities include clinical manifestations of delayed motor development, cranial nerve dysfunction, visual and auditory impairment, abnormal breathing patterns, or impaired intellectual development, depending on the degree of affected intracranial structure [14,15] In 26-38% of DWM cases, the patients also present with extracranial manifestations including congenital heart defects (ventricular septal defects, patent ductus arteriosus, atrial septal

defects, pulmonary stenosis, AV canal defect), intestinal anomalies, renal defects (polycystic kidneys, cryptorchidism), and syndactyly [16] in the head and neck area, DWM patients may present with cleft lip and/or cleft palate, high arch palate, strabismus, macrocephaly, frontal bossing, hypertelorism, facial angioma, and dysmorphic facies [13,17]. In addition, DWM has been reported to associate with many syndromes affecting craniofacial regions including the oral-facial-digital syndrome type I, PHACE syndrome (posterior fossa brain malformations, hemangiomas, arterial anomalies, coarctation of aorta and cardiac defects and eye abnormalities), and Ellis-van Creveld syndrome [18,19].

The ages at diagnosis varies depending on the degree of anomalies. Although nonspecific, the early signs of DWM including macrocephaly, enlargement of skull in the occipital area and apnea, may be observed in the newborns [20]. The diagnosis of DWM is made by the first year of life in 80% of the DWM cases by using computed tomography (CT) and/or magnetic resonance imaging (MRI) [21]. Prenatal DWM can be detected and confirmed as early as 18 weeks of gestation by the use of three-dimensional ultrasound and fetal MRI [22]. Undiagnosed DWM in adult is usually detected by incidental findings during diagnostic imaging following head trauma or in the presence of other neurological symptoms including headaches and seizures [23,24]. The treatment options for DWM are the traditional shunt placement, posterior fossa craniectomy, and endoscopic third ventriculostomy [25].

Dental management of DWM can be challenging due to complexity of the syndrome and the variability of the clinical presentations. Previous reports show the dental management of the DWM patients under general anesthesia [26,27]. Here, we report for the first time the

**\*Corresponding author:** Warotayanont R, Division of Pediatric Dentistry, Department of oro-facial Sciences, University of California, San Francisco, California, USA; Tel: (415) 476-3276; FAX: (415) 514-2561; E-mail: [Rungnapa.Warotayanont@ucsf.edu](mailto:Rungnapa.Warotayanont@ucsf.edu)

**Received** May 03, 2016; **Accepted** May 11, 2016; **Published** May 17, 2016

**Citation:** Warotayanont R, Huang S, Vaderhobli R, Kao J, Le T (2016) Dental Considerations in Dandy-Walker Malformation. *Pediatr Dent Care* 1: 108.

**Copyright:** © 2016 Warotayanont R, et al. This is an open-access article distributed under the terms of the Creative Commons Attribution License, which permits unrestricted use, distribution, and reproduction in any medium, provided the original author and source are credited.

dental management of a pediatric DWM case under oral conscious sedation. An 11-year old child presented with DWM presented with the chief complaint of a fractured anterior tooth following endodontic treatment. The restorative options and dental management modalities are discussed.

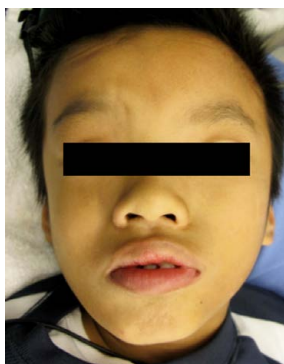## Case Report

An 11 year-old Asian male presented at University of California, San Francisco Graduate Pediatric Dental Clinic with a fractured anterior tooth as his chief complaint. The patient medical history was Dandy-Walker malformation, which was diagnosed after birth along with hydrocephalus. At 1 year of age, the hydrocephalus and the cystic malformation were self-resolved with no history of shunt insertion or endoscopic interventions. However, the DWM had caused impairment in vision and hearing on the left side. In addition, he had ataxic gait with left sided imbalance. He had no current medications and had no known drug allergies. His intellectual development was delayed. He was in his third grade at the time of his presence at the clinic.

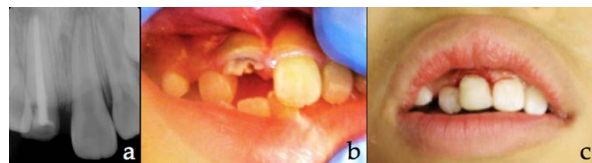
For dental history, he had history of complicated crown fracture on maxillary right central incisor following trauma when he was 10 years old. The root canal treatment was completed by a local dentist, using oral sedative medications (30 mg hydroxyzine and 20 mg midazolam) in two consecutive appointments. Coronal coverage was restored by composite restoration, but was fractured shortly after the treatment was completed. The tooth was asymptomatic. He had been having routine check-up appointment at the local dental office.

On physical examination, the patient appeared to have left side imbalance and ataxic gait as he walked. His airway assessment was Mallampati classification II and Brodsky's tonsil classification II. He had negative history of snoring or sleep apnea. The patient exhibited Frankl behavioral rating scale II. Although he was able to sit in chair, allowing for examination and prophylaxis treatment, he was reluctant to accept the treatment and his attention span was short.

The extraoral examination showed a concave facial profile, orbital hypertelorism, flattened nasal bridge, thick upper and lower lips, incompetent lips, slightly asymmetric face and chin deviation to the right (Figure 1). The patient was unable to completely close his left eye and was dependent on eye drops. Intraoral examination showed dental age-appropriate late mixed dentition with no missing teeth. The occlusal relationship was Angle's Classification II Division 1



**Figure 1:** Craniofacial presentations of dandy-walker malformations. An 11 year-old Asian male with the history of Dandy-Walker Malformation shows craniofacial features including brachycephaly, frontal bossing, orbital hypertelorism, flattened nose bridge, thick upper and lower lips, incompetent lips, downward corners of the mouth, and deviation of chin to the right.



**Figure 2:** Preoperative and postoperative clinical presentation of maxillary right central incisor. The preoperative periapical radiograph of maxillary right central incisor shows intact root canal filling with absence of periapical pathologies (a). The clinical finding shows complicated crown fracture and facial discoloration (b). The tooth was restored using fiber-reinforced composite as a monoblock post system and the composite crown as a final coronal restoration (c).

malocclusion with anterior single tooth crossbite, anterior crowding, deep overbite (5 mm) and 3 mm overjet. His mandibular midline was shifted 2 mm to the right side. There was no sign of soft tissue pathology (Figure 2a). The right maxillary central incisor was previously root canal treated and was restored with composite resin material. The composite restoration was fractured to the gingival one third of the crown. Dark brown discoloration was observed on the facial surface of the maxillary right central incisor (Figure 2b). The tooth was non-mobile, negative to percussion, and negative to palpation. Periapical radiographs showed no signs of root fracture, intact root canal filling material and the absence of periapical pathologies (Figure 2a). The examination of other teeth in dental arches revealed no dental caries.

The decision was made to restore the coronal portion of the right maxillary central incisor under the use of oral sedative medications. The purposed treatment plans were gingivectomy to increase clinical crown length and bonding surface area, bonding of a custom post system using fiber-reinforced composite (Ribbond, Seattle, WA), and fabrication of a composite crown as coronal restoration.

On the day of appointment, the patient was instructed to limit intake of food and liquids before the sedation according to the AAPD guideline [28]. On physical examination, patient weighed 23.7 kilograms. The airway evaluation showed clear bilateral lung sound and the absence of upper respiratory infections. The baseline vital signs were as followed: heart rate 94 beats per minute, oxygen saturation 97%, and blood pressure 96/69. The medications given via a cup and a syringe included 800 mg chloral hydrate, 50 mg meperidine and 50 mg hydroxyzine. The medication was wasted 40-50% due to the patient's uncooperative behavior. The wait time was 45 minutes before starting the procedure. The protective stabilizer was used during the time of treatment. Nitrous oxide and oxygen (3L:3L) at the flow rate of 5 L/min was introduced to the patient as he was seated in the dental chair. The right maxillary central incisor was anesthetized by local infiltration of 34 mg 2% lidocaine containing 1:100,000 epinephrine. Gingivectomy was performed on free gingival of right maxillary central incisor. Using Nd:YAG laser (Pulse Master 2000, American Dental Technology, Christi, TX) at 1.5 W, 15 Hz with fiber aimed away from the tooth, the free gingiva was removed approximately 1.5 mm on the facial, and 2 mm on the lingual of the right maxillary central incisor. All safety and precautions was followed according to Academy of Laser Dentistry guideline. Subsequently, the root canal filling was removed 2/3 of the working length by using Touch n' Heat (SybronEndo, Orange, CA) and the gate glidden drills. The fiber-reinforced composite was bonded into the canal following manufacturer's protocol (Ribbond, Seattle, WA). The coronal portion was restored by composite resin followed by removal of occlusal interferences (Figure 2c). At the end of procedure, 100% oxygen was administered for 5 minutes. The vital signs including heart rate, blood pressure, respiratory rate, oxygen saturation and

breathing sound were monitored every 5 minutes throughout the treatment time.

The behavior of the patient during the treatment was very cooperative. He was awake, easily arousable, and was able to follow instructions well. There was minimal movement during the treatment. The vital signs were stable during and after the treatment. The post-operative instructions were given to parents regarding concerns of anesthesia and sedation. The patient met the discharge criteria according to AAPD guideline [28]. The evening follow-up call suggested that patient was able resume his normal activities and tolerate regular diets. There was absence of pain, nausea, vomiting, bleeding, swelling and any other discomfort. The patient was instructed to follow up 1 month, 3 months and 6 months after the procedure; however, he had not shown up due to long travel time and the unavailability of parents' schedule.

## Discussion

Dandy-Walker malformation (DWM) is a rare congenital abnormality of posterior cranial fossa. Affected individuals show a range of clinical manifestations depending on the extent intracranial and extracranial anomalies. Previous studies suggest the dental management of DWM patients under general anesthesia and IV sedation [26,27]. In the current report, we presented the dental management of an 11-year-old patient with DWM, who required coronal restoration of the previously endodontic-treated maxillary right central incisor, under oral conscious sedation. Clinically, patient presented with auditory and visual impairment, as well as cerebellum dysfunction as shown in ataxic gait. Review of patient's medical history showed the absence of extracranial manifestations. Assessment of his airway and his behavior, as well as the amount of required dental restoration, suggested that he was a candidate for dental treatment under oral sedation. The patient tolerated the procedure well and was able to cooperate during the treatment. He recovered and met the discharge criteria after the procedure. This report suggested that patient with Dandy Walker Malformation can be safely managed in the dental chair despite the medical complexity of the syndrome.

CNS tumors are the most common solid tumors in pediatric population with the highest incidence in the children under the age of 5 years old [29,30]. The location of the primary CNS tumors in children is commonly found in the posterior cranial fossa as opposed to the supratentorial tumors in cerebral hemispheres in adults [31]. The development of the posterior fossa tumors has been found associated with genetic disorders and maternal exposure to teratogens. The clinical presentations of DWM vary depending on the severity of the affected organs. The increased intracranial pressure due to the tumor mass and hydrocephaly accounts for cerebellar and cranial nerve dysfunction, neurological complications, as well as intellectual impairment. Nearly half of the affected children with posterior fossa syndromes also presented with extracranial symptoms including cardiac anomalies, renal dysfunction, craniofacial malformations, and abnormal limb development [32].

In the current report, there was negative family history of known genetic abnormalities. The patient presented with the clinical signs and symptoms similar to the previous case report [17] including visual and hearing impairment, ataxic gait, developmental delay, brachycephaly, hypertelorism and flattened nasal bridge. The absence of other extracranial abnormalities may be related to his early resolution of the hydrocephalus and the tumor mass by 1 year of age. The dental findings of Angle's Class II malocclusion with anterior single tooth

crossbite and crowding are similar to the dental findings in DWM reported previously [27]. The increased overjet may be associated with the increased susceptibility to trauma as seen in the current patient.

The dental management of the patients with DWM should involve review of medical history, consultation with physicians for associated extracranial abnormalities, craniofacial examination, oral examination and behavioral assessment. Due to the clinical presentations of DWM as well as potential delay intellectual development, the dental treatment planning should emphasize on preventive strategies. Because of a wide range of the clinical presentations of DWM, the restorative treatment options, if necessary, should be considered based on assessment of individual's clinical presentations and behavior.

In the current report, although the patient required restoration of only one tooth, the patient's attention span was not adequate to allow for dental treatment in the regular dental chair. After reviewing of his medical history, the decision was made to treat him with under oral sedative medications. The triple cocktail was chosen as the oral sedative regimen based on the patient's behavior and the length of treatment. The use of fiber-reinforced composite as a mono block post system in place of the conventional post system allowed for greater adaptation and flexibility to the canal, the incorporation of the restorative material into the post system, as well as better time management under the oral sedative medications.

To our knowledge, this is the first report of the dental management of a pediatric patient who presents with Dandy-Walker malformation, using oral conscious sedation. Due to the complexity of the syndrome, as well as the heterogeneity of the Dandy-Walker complex, affected individuals may present with distinct clinical presentations and varied intellectual development, which may be challenging to the dental management. The review of medical history of the current patient shows no contraindication for the dental treatment under oral sedative medications and the patient was successfully treated in the dental chair. Future studies on clinical signs and symptoms of DWM patients in the same and different age groups who require dental treatment will contribute to better understanding of dental management and clinical decision making.

## References

1. Alexiou GA, Sfakianos G, Prodromou N (2010) Dandy-Walker malformation: analysis of 19 cases. *J Child Neurol* 25: 188-191.
2. Marinov M, Gabrovsky S, Undjian S (1991) The Dandy-Walker syndrome: diagnostic and surgical considerations. *Br J Neurosurg* 5: 475-483.
3. Shekdar K (2011) Posterior fossa malformations. *Semin Ultrasound CT MRI* 32(3): 228-241.
4. Warf BC, Dewan M, Mugamba J (2011) Management of Dandy-Walker complex-associated infant hydrocephalus by combined endoscopic third ventriculostomy and choroid plexus cauterization. *J NeurosurgPediatr* 8: 377-383.
5. Parisi MA, Dobyns WB (2003) Human malformations of the midbrain and hindbrain: review and proposed classification scheme. *Mol Genet Metab* 80: 36-53.
6. Patel S, Barkovich AJ (2002) Analysis and classification of cerebellar malformations. *AJNR Am J Neuroradiol* 23: 1074-1087.
7. Sasaki-Adams D, Elbabaa SK, Jewells V, Carter L, Campbell JW, et al. (2008) The Dandy-Walker variant: a case series of 24 pediatric patients and evaluation of associated anomalies, incidence of hydrocephalus, and developmental outcomes. *J NeurosurgPediatr* 2: 194-199.
8. Barkovich AJ, Kjos BO, Norman D, Edwards MS (1989) Revised classification of posterior fossa cysts and cystlike malformations based on the results of multiplanar MR imaging. *AJR Am J Roentgenol* 153: 1289-1300.

9. Murray JC, Johnson JA, Bird TD (1985) Dandy-Walker malformation: etiologic heterogeneity and empiric recurrence risks. *Clin Genet* 28: 272-283.
10. Aldinger KA, Lehmann OJ, Hudgins L, Chizhikov VV, Bassuk AG, et al. (2009) FOXC1 is required for normal cerebellar development and is a major contributor to chromosome 6p25.3 Dandy-Walker malformation. *Nat Genet* 4: 1037-1042.
11. Grinberg I, Northrup H, Ardinger H, Prasad C, Dobyns WB, et al. (2004) Heterozygous deletion of the linked genes ZIC1 and ZIC4 is involved in Dandy-Walker malformation. *Nat Genet* 36: 1053-1055.
12. Alexiou GA, Sfakianos G, Prodromou N (2010). Dandy-Walker malformation: analysis of 19 cases. *J Child Neurol* 25: 188-191.
13. Cornford E, Twining P (1992) The Dandy-Walker syndrome: the value of antenatal diagnosis. *Clin Radiol* 45: 172-174.
14. Hirsch JF, Pierre-Kahn A, Renier D, Sainte-Rose C, Hoppe-Hirsch E (1984) The Dandy-Walker malformation. A review of 40 cases. *J Neurosurg* 61: 515-522.
15. Imataka G, Yamanouchi H, Arisaka O (2007) Dandy-Walker syndrome and chromosomal abnormalities. *Congenit Anom (Kyoto)* 47: 113-118.
16. Golden JA, Rorke LB, Bruce DA (1987) Dandy-Walker syndrome and associated anomalies. *Pediatr Neurosci* 13: 38-44.
17. Tadakamadla J, Kumar S, Mamatha GP (2010). Dandy-Walker malformation: An incidental finding. *Indian J Hum Genet* 16: 33-35.
18. Rossi A, Bava GL, Biancheri R, Tortori-Donati P (2001) Posterior fossa and arterial abnormalities in patients with facial capillary haemangioma: presumed incomplete phenotypic expression of PHACES syndrome. *Neuroradiology* 43: 934-940.
19. Toriello HV, Franco B (1993). Oral-Facial-Digital Syndrome Type I.
20. Kollias SS, Ball WS Jr., Prenger EC (1993) Cystic malformations of the posterior fossa: differential diagnosis clarified through embryologic analysis. *Radiographics* 13: 1211-1231.
21. Lavanya T, Cohen M, Gandhi SV, Farrell T, Whitby EH (2008) A case of a Dandy-Walker variant: the importance of a multidisciplinary team approach using complementary techniques to obtain accurate diagnostic information. *Br J Radiol* 81: 242-245.
22. Klein O, Pierre-Kahn A, Boddaert N, Parisot D, Brunelle F (2003) Dandy-Walker malformation: prenatal diagnosis and prognosis. *Childs Nerv Syst* 19: 484-489.
23. Mendelson SG (2011) Maternal grand mal seizure leads to a surprising diagnosis of Dandy-Walker variant. *J Obstet Gynecol Neonatal Nurs* 40: 458-462.
24. Sato K, Kubota T, Nakamura Y (1996) Adult onset of the Dandy-Walker syndrome. *Br J Neurosurg* 10: 109-112.
25. Kohler BA, Ward E, McCarthy BJ, Schymura MJ, Ries LA, Ehemann C, et al. (2011) Annual report to the nation on the status of cancer, 1975-2007, featuring tumors of the brain and other nervous system. *J Natl Cancer Inst* 103: 714-736.
26. Hitosugi T, Tsukamoto M, Fujiwara S, Yokoyama T (2016) [Intravenous Sedation and Repeated "the Same Day General Anesthesia" for a School-age Boy with Dandy-Walker Syndrome and Dentinogenesis]. *Masui. Jpn J Anesthesiol* 65: 304-307.
27. Kusumoto Y, Shinozuka O (2014) Oral findings and dental treatment in a patient with Dandy-Walker syndrome: a case report. *Special care in dentistry: official publication of the American Association of Hospital Dentists, the Academy of Dentistry for the Handicapped, and the American Society for Geriatric Dentistry* 34: 151-155.
28. DeLancey JO, Thun MJ, Jemal A, Ward EM (2008) Recent trends in Black-White disparities in cancer mortality. *Cancer Epidemiol Biomarkers Prev* 17: 2908-2912.
29. American Academy of Pediatrics and the American Academy of Pediatric Dentistry (2008) Guideline for monitoring and management of pediatric patients during and after sedation for diagnostic and therapeutic procedures. *Pediatric dentistry* 30: 143-159.
30. Jemal A, Siegel R, Xu J, Ward E (2010) Cancer statistics. *CA Cancer J Clin* 60: 277-300.
31. Khatua S, Sadighi ZS, Pearlman ML, Bochar S, Vats TS (2012) Brain Tumors in Children- Current Therapies and Newer Directions. *Indian J Pediatr*. 79: 922-927.
32. Ecker JL, Shipp TD, Bromley B, Benacerraf B (2000) The sonographic diagnosis of Dandy-Walker and Dandy-Walker variant: associated findings and outcomes. *Prenat Diagn* 20: 328-332.