

## Fracture Dislocation of Metatarsal Bones I-V in 4 Year Old Girl

Igor Frangež\*, Jure Kos, Matej Cimerman and Dragica Maja Smrke

Department of Traumatology, Surgery Clinic, University Medical Centre Ljubljana, Zaloska cesta 2, 1000 Ljubljana, Slovenia

\*Corresponding author: Igor Frangež, Department of Traumatology, Surgery Clinic, University Medical Centre Ljubljana, Zaloska cesta 2, 1000 Ljubljana, Slovenia, Tel: +386 1 522 3255; E-mail: ifrangez@gmail.com

Received date: Jan 30, 2016; Accepted date: Mar 16, 2016; Published date: March 26, 2016

Copyright: © 2016 Frangež I, et al. This is an open-access article distributed under the terms of the Creative Commons Attribution License, which permits unrestricted use, distribution, and reproduction in any medium, provided the original author and source are credited.

### Abstract

A case study of a 4-year-old girl who sustained a dislocated fracture of all 5 metatarsal bones when a table fell on her left foot is presented. Due to substantial sagittal displacement, operative treatment was required. After open reduction, we fixed the fractures with K-wires. Four weeks after the operation, the bones had healed in their anatomic positions and the patient was able to walk without pain.

**Keywords:** Metatarsal fracture; Children; Open reduction; Sagittal displacement; K-wire; Multiple fractures

### Introduction

Fractures of metatarsal (MT) bones are the most frequent fractures of foot bones in children [1], and represent 3.7% of all fractures in children [2,3]. Treatment is usually conservative and includes 3-6 weeks of immobilization and protected weight bearing [1,2,4,5]. In adults, some authors recommend reposition and fixation in cases with bone fragment displacement in the sagittal plane and/or shortening. Dislocations of 3-4 mm and angulation of over 10% are also among the criteria for operative treatment [1]. Similar guidelines are advised in children, with significant displacement being set at angulation of over 10%, displacement of more than half of shaft, and shortening of more than 0.5 cm [6]. For simple II-IV MT fracture, percutaneous retrograde intramedullary pinning with K-wires was suggested [1,5], and open reduction with K-wires was recommended in cases where percutaneous technique is not possible [5,6].

### Case Report

A 4-year-old Caucasian girl was admitted to the emergency department after a table had fallen on her left foot. Following the accident, she was unable to weight bear the injured foot. Clinical examination revealed a swollen and painful left foot. Active movement was not possible. X-ray (Figure 1) showed fractures of all 5 metatarsals in the region of metaphysis with a dislocation of II-V MT. The amount of dislocation was largest at the 2<sup>nd</sup> metatarsal space, where the MT was dislocated plantarly in sagittal plane with no contact between bone fragments. The 3<sup>rd</sup> MT also had almost no contact with sagittal plane dislocation, whereas the 4<sup>th</sup> and 5<sup>th</sup> MTs had a milder dislocation.

After examination, the patient was admitted and received a below-knee cast for pain management. Five days after hospitalisation, operative treatment was scheduled so that soft tissue could recover from extensive edema. The operation was performed in general anaesthesia and with local ischemia. Open reduction using dorsocentral incision over the 3<sup>rd</sup> MT and the 3<sup>rd</sup> cuneiform was performed, followed by fixation with retrograde K-wires (Figure 2). Wound closure drainage was enabled for two days following the

operation. In addition, immobilisation with short non-walking leg cast was achieved.

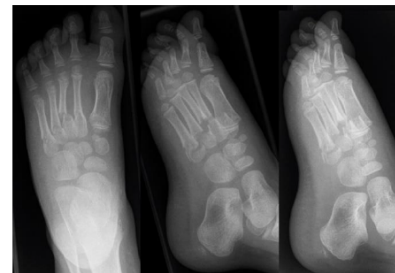

Figure 1: X-ray at admission.

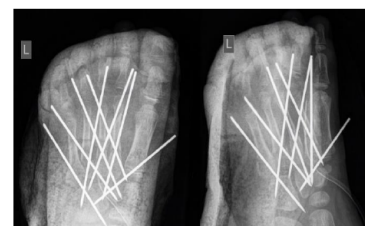


Figure 2: Position of K-wires.

Three days after the operation, the patient was discharged because she was able to walk using crutches. Week 1 follow-up revealed suitable bone healing. Later, week 4 X-ray revealed healed fractures, so we decided to remove the K-wires in short general anaesthesia. The patient received a personalized orthopaedic shoe that enabled full weight bearing and started with physiotherapy. At the last check-up 3 months after the operation, the patient was walking without any pain or visible gait disturbances and the X-ray revealed fully healed fractures (Figure 3).

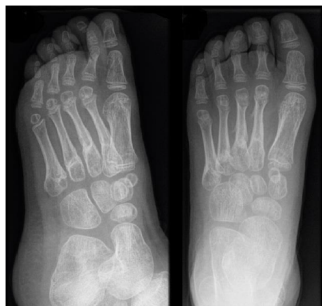

Figure 3: Final X-ray after 4 weeks.

## Discussion

Reports on MT bone fractures are rare, especially in children. To our knowledge, few articles were published that focus specifically on MT fractures in children [2,3]. These study results showed that the most common mechanisms are different in younger compared to older children. Children under the age of 5 are usually injured from a fall from height, while older children usually suffer twisting injuries in sports activities [2,3]. These are the two most common aetiologies, followed by crush damage as the third most common reason for fractures [2,3]. Different mechanisms mean that different MTs get fractured. In younger children, it is usually the 1st MT, while in older children it is the 5th MT [2,3]. In 11-18% of cases, more than one MT gets broken [2,3]. In a study of 125 children with MT fractures, fractures of more than one MT were most common when II-IV MT were involved, while fractures of the 1st and 5th MT were often isolated. Study results also showed that only 2% of cases involved fractures dislocated for more than the width of the shaft [2].

MT fractures are usually treated conservatively, with cast immobilisation being performed for 3-6 weeks [1,2,5]. Surgical treatment is suggested in cases with significant displacement (angulation of over 10%), displacement of more than half of the shaft, and shortening of more than 0.5 cm [6].

Such displacements can change the distribution of body weight on the foot, which may lead to painful complications later on in life [4].

A retrospective review of 337 children who suffered from a MT fracture showed that returning to sports took longer in the operated group, while the non-operated group had a few more cases of residual post-treatment pain. In this report, none of the patients under 12 years was operated on [5].

In our case report, we discuss a 4-year-old girl who fractured all 5 MT bones when a table fell on her foot. Substantial sagittal fracture

dislocation in II-IV MT bones was present. Even though operative treatment at this age is rare [5], open reduction and fixation with K-wires were needed to restore the anatomic position between fracture fragments. The operation and post-op hospitalization were uneventful; we removed the wires and allowed full weight bearing after one month. At the last check-up, the patient walked without pain or limping.

When deciding on the type of treatment for MT fractures, force distribution should always be considered. In children fractures generally allow more displacement, so full sagittal displacement should not be overlooked. Even though percutaneous fixation is suggested in most cases, open reduction can also be considered in the case of a severe injury like ours. With open reduction, the anatomic position of bone fragments was achieved. Returning to daily and sports activities-reported to take longer in the operated group included in the largest review-was short in our case and comparable to recovery times in cases of conservative treatment.

Such extensive injuries in small children are rare and their long-term consequences unknown due to a lack of reports. Therefore, we opted for open reduction that enabled anatomic reconstruction. In our case report, we wanted to show that operative treatment, especially open reduction which is sometimes avoided in children, can yield better reconstruction and rehabilitation period, comparable to cases where only the conservative treatment was needed.

## Conclusion

Our case study discusses an extremely rare case of a 4-year-old girl who required open reduction and internal fixation in order to correct the force distribution in her foot. At 1-year follow-up, the patient is still pain free and fully active in her daily activities.

## References

1. Rammelt S, Heineck J, Zwipp H (2004) Metatarsal fractures. *Injury* 35 Suppl 2: SB77-86.
2. Singer G, Cichocki M, Schalamon J, Eberl R, Höllwarth ME (2008) A Study of Metatarsal Fractures in Children. *J Bone Joint Surg Am* 90: 772-776.
3. Owen RJT, Hickey FG, Finlay DB (1995) A study of metatarsal fractures in children. *Injury* 26: 537-538.
4. Zwipp H, Rammelt S (2002) *Frakturen und Luxationen. Orthopädie und Orthopädische Chirurgie.* Georg Thieme Verlag, Stuttgart, New York. pp: 531-618.
5. Robertson NB, Roocroft JH, Edmonds EW (2012) Childhood metatarsal shaft fractures: treatment outcomes and relative indications for surgical intervention. *J Child Orthop* 6: 125-129.
6. Laer LV (2004) *Pediatric Fractures and Dislocations.* Thieme.