

## The Approach to Proximal Fifth Metatarsal Fractures in Athletes

Ryan Churchill W<sup>1\*</sup>, Thomas Sherman I<sup>1</sup>, Matthew Carpinello<sup>2</sup> and William F Postma<sup>1</sup>

<sup>1</sup>Department of Orthopaedic Surgery, MedStar Georgetown University Hospital, 3800 Reservoir Road NW Washington DC, USA

<sup>2</sup>Department of General Surgery, Mount Sinai St Luke's Roosevelt Hospital Center, 10 Amsterdam Avenue, NY, USA

\*Corresponding author: Ryan Churchill, Department of Orthopaedic Surgery, MedStar Georgetown University Hospital, 3800 Reservoir Road NW Washington, DC 20007, USA, Tel: 551-206-4922; Fax: 202-444-7455; E-mail: ryan.w.churchill@gmail.com

Received date: Dec 14, 2015; Accepted date: Feb 27, 2016; Published date: Mar 10, 2016

Copyright: ©2016 Ryan Churchill W, et al. This is an open-access article distributed under the terms of the Creative Commons Attribution License, which permits unrestricted use, distribution, and reproduction in any medium, provided the original author and source are credited.

### Abstract

Fractures of the proximal fifth metatarsal are injuries that occur more frequently in the elite athlete population and have the potential to significantly impact the ability of the athlete to return to play if not treated appropriately. These fractures can be separated into three types: tuberosity fractures, Jones fractures and diaphyseal stress fractures. For the treating physician, a thorough understanding of the bony and vascular anatomy, mechanism of injury and treatment options are vital to provide the elite athlete with the optimal outcome. Most fractures of the tuberosity can be treated non-surgically with a stiff soled shoe or controlled ankle motion boot with most athletes returning to play by 8 weeks. When treating the Jones fracture in the high level athlete the trend in the literature is towards intramedullary screw placement for immediate fixation and subsequent faster return to play. This is also the case for diaphyseal stress fractures of the fifth metatarsal. This paper provides a critical review of the current literature with the author's preferred method of treatment of these injuries in the elite athlete population to provide the orthopaedic surgeon with a basis for treatment of these injuries based on the most recent literature.

**Keywords:** Fifth metatarsal fracture; Jones fracture; Athlete; Intramedullary screw

### Introduction

Fractures of the proximal aspect of the fifth metatarsal were first described by Sir Robert Jones in 1902 in a case series of four patients that also included the author himself [1]. The injury he described, which became known as the eponymous Jones fracture, is defined as a fracture of the fifth metatarsal at the meta-diaphyseal junction that involves the fourth-fifth metatarsal articulation. This same location is also a vascular watershed zone, which has implications for both healing and treatment. However, fractures of the proximal fifth metatarsal other than Jones fractures are common and include proximal tubercle avulsions, also known as Dancer's or pseudo-Jones fractures, and proximal diaphyseal fractures. These fractures are often difficult to distinguish based upon radiographic appearance but are very distinct injuries in terms of treatment, prognosis, and potential complications. Thus, precise and accurate diagnosis of fractures of the proximal fifth metatarsal is required to ensure appropriate patient care.

The incidence of fifth metatarsal fractures in the general population is estimated as 1.8 per 1000 person-years [2]. However, these injuries occur with greater frequency in certain populations, such as athletes. The mechanism by which this fracture occurs is from a laterally directed force to the forefoot while the tibiotalar joint is plantar flexed [3]. As an example, this can occur in the athlete while he is pivoting in a basketball or football game. It is thought that athletes sustain these fractures more than the general population because they are involved in more running and jumping activities that places them at risk for this fracture [3]. In fact, one study reported that Jones fractures and proximal diaphyseal stress fractures comprised 17.8% of all foot and ankle injuries sustained by elite football players over a five-year period [4]. Given the frequency with which these injuries occur, fractures of

the fifth metatarsal require careful consideration in the athletic population.

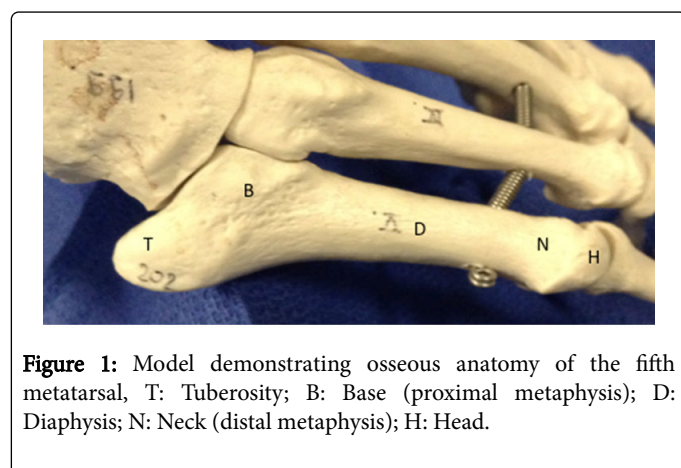
Historically, all patients with fractures of the proximal fifth metatarsal were treated with cast immobilization and a prolonged period of non-weight bearing. Such a treatment strategy may be particularly difficult for an athlete to adhere to as this invariably necessitates significant time away from sport, which may result in deterioration in skill, fitness, and performance. These deleterious sequelae are made more severe in the setting of a nonunion or delayed union, in which return to sport is further delayed [5,6]. For the pre-professional or professional athlete, missed time has potential financial implications as well. To this end, Donaldson et al. reported that 50.9% of National Hockey League (NHL) players missed at least one game per season due to a sports-related injury at an estimated total cost of \$218 million [7]. Thus, to expedite recovery through faster and more reliable healing, as well as mitigation of potential complications and pitfalls associated with fractures of the proximal fifth metatarsal, there is a general trend towards early surgical intervention for athletes with these injuries, particularly Jones fractures [2,8-10].

The basis of the changing treatment paradigm in the athletic population is largely provided by several studies that have reported more favorable results with surgical intervention compared to traditional, non-operative methods [5,11,12]. However, careful consideration must be given to how these studies' cohorts of "athletes" are defined before treatment recommendations are extrapolated to individual patients. To this end, the terms "athlete" and "elite athlete" are inconsistently and heterogeneously defined in many of these studies. Despite the heterogeneity of these definitions, the underlying theme across these studies is relatively consistent. Thus our definition of an elite athlete is an active individual in whom athletic participation is highly valued and expeditious return to sport is desired. In this patient, he may benefit most by a surgical treatment strategy that differs from the general population. This paper aims to critically review

the literature regarding fractures of the proximal fifth metatarsal in athletes and present the reader with concise treatment recommendations for this population.

## Anatomy

As with all injuries encountered by the orthopaedic surgeon, knowledge of the relevant anatomy is critical. The osseous anatomy of the fifth metatarsal is typically characterized by its tuberosity, base (proximal metaphysis), shaft (diaphysis), neck (distal metaphysis), and head [13]. The fifth metatarsal flares plantarly and distally as one travels from the tuberosity to distal metatarsal neck. This bears importance for positioning a screw at the correct starting point to obtain an appropriate length when intramedullary fixation is used [13]. The fifth metatarsal has three articulations: fourth-fifth intermetatarsal joint, fifth metatarsal-cuboid tarsometatarsal articulation and the metatarsal phalangeal articulation. The fifth metatarsal is stabilized by its attachments to the intermetatarsal ligament as well as several other ligamentous and tendinous structures (Figure 1). These include the peroneus tertius, which attaches along the proximal diaphysis, as well as the peroneus brevis and lateral cord of the plantar aponeurosis, both of which attach to the proximal tuberosity [14].



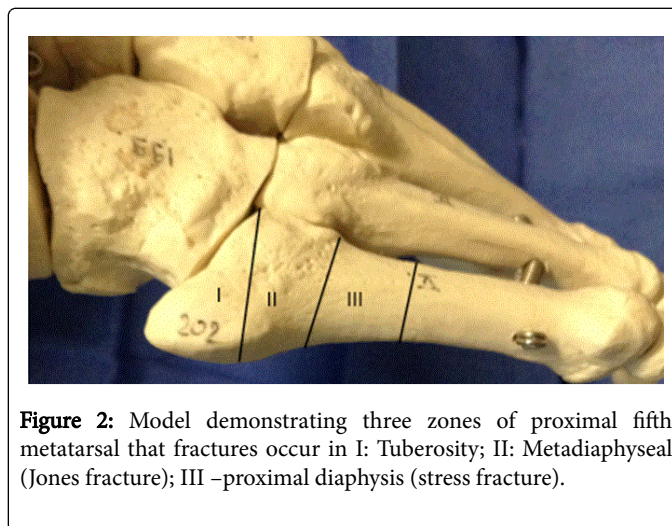
**Figure 1:** Model demonstrating osseous anatomy of the fifth metatarsal, T: Tuberosity; B: Base (proximal metaphysis); D: Diaphysis; N: Neck (distal metaphysis); H: Head.

Jones fractures occur in an area of the proximal fifth metatarsal that is considered a vascular watershed zone due to the unique vascular anatomy of this region. The metaphyseal arteries enter the base of the proximal fifth metatarsal and supply the proximal tuberosity, while a proximal branch of the diaphyseal nutrient artery extends across the metadiaphyseal junction to supply the base. The resultant watershed zone predisposes the area to fractures as well as delayed union and non-union once the injury occurs [15]. Thus, to optimize treatment, it is essential that fractures involving the proximal fifth metatarsal are precisely characterized so appropriate treatment strategies can be selected.

## Classification

Fractures of the proximal fifth metatarsal are classified into three zones. Zone I refers to fractures occurring within the tuberosity also known as Dancer's or pseudo-Jones fractures, Zone II describes fractures of the proximal metadiaphyseal junction, including the Jones fracture, and Zone III fractures are those which involve the proximal 1.5 cm of the diaphysis [9,16,17]. Zone I fractures are the most common and occur proximal to the fourth-fifth metatarsal joint and

typically extend from the lateral aspect of the tuberosity towards the cuboid [13]. They occur with inversion of the foot as the attachments of the plantar aponeurosis lateral cord and peroneus brevis avulse the tuberosity (Figure 2). Type II fractures or Jones fractures are those that begin at the lateral aspect of the fifth metatarsal and extend obliquely into the fourth-fifth intermetatarsal joint. This pattern is produced when a plantar flexed foot experiences a significant adduction force. Type III fractures are typically due to stress injuries related to repetitive overload that occur in the diaphysis just distal to the fourth-fifth intermetatarsal joint [17,18].



**Figure 2:** Model demonstrating three zones of proximal fifth metatarsal that fractures occur in I: Tuberosity; II: Metadiaphyseal (Jones fracture); III –proximal diaphysis (stress fracture).

A classification proposed by Torg and colleagues further categorized fractures occurring distal to the tuberosity into three types based on acuity, as determined by radiographic appearance. Type I fractures are acute fractures characterized by a narrow fracture line without evidence of medullary sclerosis. Type II fractures are delayed union fractures with a widened fracture line and evidence of intramedullary sclerosis. Type III fractures are nonunions identified by obliteration of the medullary canal. This temporal characterization serves to direct treatment and provide accurate prognoses, as patients with Type II or III injuries were significantly more likely to require surgical intervention [17,19].

## Treatment

### Type I: Tuberosity/avulsion fractures

Zone I fractures are avulsion-type fractures of the tuberosity, and the most common fracture type of the fifth metatarsal injuries [9]. Although both the lateral cord of the plantar fascia and peroneus brevis have both been implicated as the avulsing structure, studies have found that it is the lateral cord of the plantar fascia that is most responsible [14,20]. Most of these fractures heal uneventfully with nonoperative treatment. Thus, the vast majority of tuberosity fractures can be managed with progressive weight bearing as tolerated in a walking boot, hard soled shoe or short leg cast. Clinical and radiographic union is typically expected at 4-8 weeks post-injury, at which point the patient may begin to return to unrestricted activity [14]. Many of these may not unite radiographically but rarely cause discomfort. However, return to activity may be postponed in some cases of delayed union. For athletes, this may necessitate surgical treatment if it continues to be symptomatic

Treatment of nonunions typically consists of surgical excision of the avulsed fragment. Ritchie et al. described excision of the tuberosity fragment for symptomatic nonunions in six elite athletes (2 NFL, 4 Division I college athletes). All six athletes returned to full competition at an average of 11.7 weeks and were asymptomatic at a mean follow-up of 3.7 years [14]. Although their results were favorable with fragment excision, the authors advocated for internal fixation with a bicortical compression screw for nonunions with greater than 50% articular extension into the fifth metatarsal-cuboid joint. They contended that excision of these larger fragments might have greater functional implications, as significant portions of the PB insertion may be sacrificed. Similarly, Rettig et al. recommended fixation of avulsion nonunions that involve greater than 30% of the fifth metatarsal-cuboid articulation so as to avoid disruption of the PB insertion [21].

**Author's preferred treatment:** Initial nonoperative management is recommended for all patients with Type I injuries. Progressive weight bearing in a stiff-soled shoe or controlled ankle motion (CAM) boot is recommended until the symptoms abate, typically 1-2 weeks. Patients are then transitioned to normal shoe wear over 4-6 weeks, and radiographs are repeated. Once the patient is asymptomatic with weight bearing and ambulation, they are permitted to return to sport with the transition closely monitored by the athletic trainer.

For athletes with the symptomatic nonunions, we recommend excision of the nonunion for the majority of cases. Consideration may be given to bicortical screw fixation of nonunions that involve greater than 30% of the metatarsal-cuboid articulation, but this is not our practice. There is a paucity of literature to support the use of supplemental bone grafting in nonunions that are amenable to bicortical screw fixation, and as such we do not recommend the routine use of bone graft supplementation.

## Type II: Jones fractures

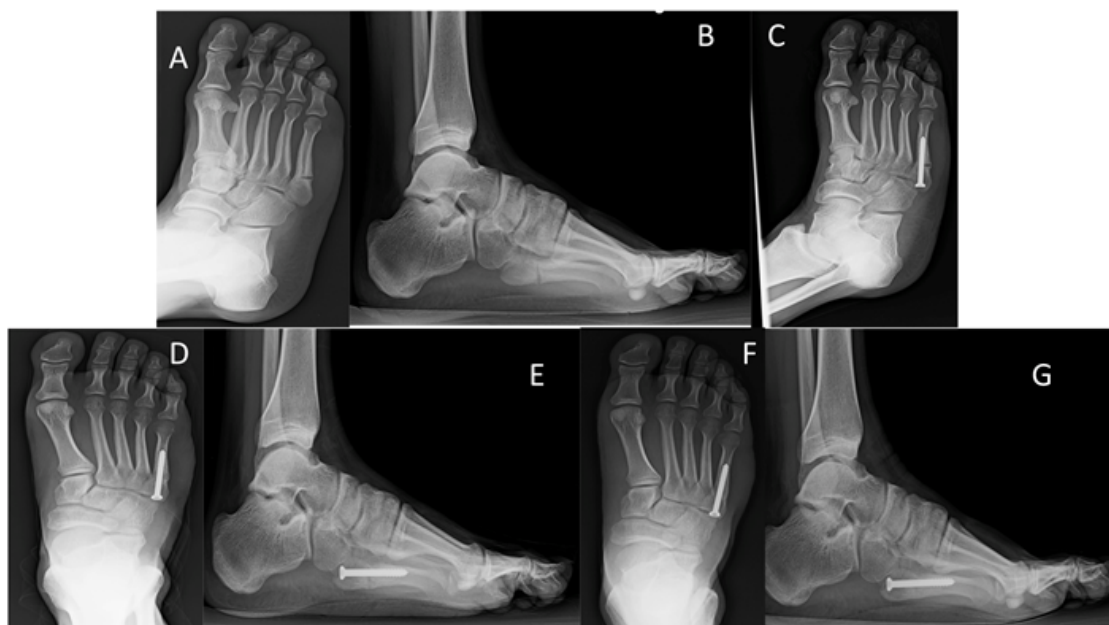The standard treatment of the Type II or "true" Jones fracture in the elite athlete is surgical fixation with an intramedullary screw [2,5,9,11,22,23]. This should not be taken to mean that athletes with nondisplaced or Torg Type I fractures cannot be treated non-operatively. In one of the original studies by Torg and colleagues, they treated twenty-five Type I Jones fractures with a short leg casting and non-weight bearing for 3-12 weeks. Six ended up requiring surgery but the remaining nineteen went onto union and return to full activities without complications [19]. Josefsson et al. reported good long term long term results in forty patients with Jones fractures treated non-operatively with short leg casting. At an average of seventeen years follow up thirty-three patients had gone onto union and seven had delayed union or refracture with only one patient still reporting pain [24]. Several studies have demonstrated superior results with surgical intervention compared to traditional nonoperative management, both in terms of more expeditious return to sport and less complications. To this end, Mologne et al. performed a prospective randomized study comparing cast immobilization to surgical fixation with an intramedullary screw in athletes with acute Jones fractures including non-displaced as well as displaced fractures. The median time to union was 7.5 weeks for the surgical group, and only one of 19 patients developed a nonunion. The nonsurgical group had a median time to union of 14.5 weeks and return to sport at 15 weeks with a 44% failure

rate [5]. Another study by Low, retrospectively evaluated the treatment outcomes over a 14-year period of 86 NFL players with Jones fractures. They reported a 94% union rate for players treated with surgical intervention compared to 80% for those treated non-operatively [4]. Two recent systematic reviews of the literature also concluded that more favorable outcomes were associated with surgical intervention in athletes. One, by Roche and Calder reported a pooled 96% union rate for Jones fractures managed with surgical intervention compared to a pooled union rate of 76% with nonoperative strategies [11]. Likewise, Kerkhoffs et al. reported similar results with a trend towards more delayed unions and nonunions with nonoperative management in athletes [12].

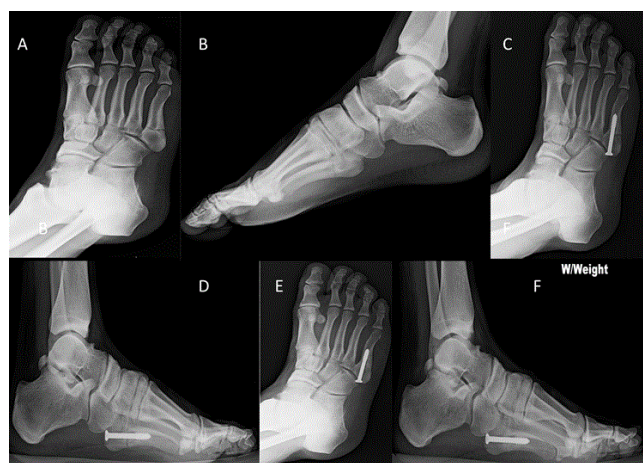
Preferred methods of fixation vary even as several studies have attempted to elucidate the most effective technique. Intramedullary screw fixation is the most common technique employed, but screw characteristics to be considered include: (1) partially or fully threaded (2) cannulated or noncannulated, (3) washer or no washer, (4) headless or traditional, and (4) and screw size. With regards to screw diameter size, use the largest fitting screw is advisable, and the most common screw diameter size used range from 4.5 mm to 6.5 mm. Kelly et al. evaluated fracture stiffness and pull out strength of 5.0 mm and 6.5 mm screws in a simulated cadaveric model of Jones fractures. They reported no difference in the bending stiffness of the two screw sizes but found that the 6.5 mm screws had significantly higher pullout strength [23]. Pietropaoli et al. compared 4.5 mm cannulated to 4.5 malleolar screws in a cadaveric model and reported no significant difference in the forces required for initial displacement and failure using the two screws [25]. Porter et al. compared 4.5 mm to 5.5 mm cannulated stainless steel screws in two groups of athletes and found three failures secondary to bent screws in the 4.5 mm group [6]. Along these lines, Wright suggested that larger size screws should be used in the athlete with a larger body habitus, as greater forces are transmitted through the construct, and he noted that 4.5 or 5.0 mm screws had been used in NFL players who had sustained refractures in his study. Ochenjele et al. recently evaluated the osseous anatomy of 119 patients using computerized-tomography (CT) to determine the optimal intramedullary screw length. They reported that the mean straight segment length (base of the metatarsal to beginning of shaft curvature) was 52 mm and that the shape of the shaft is more elliptical than circular, with the coronal plane having the smallest diameter that was on average 5.0mm at the isthmus. From this, they concluded that screws greater than 4.5 mm might be required to gain adequate fixation [26].

Orr et al. compared traditional partially threaded screws to variable pitch headless compression screws in a cadaveric model, found greater fracture site compression and decreased fracture site angulation using the partially threaded screws [27]. Reese et al. retrospectively evaluated the outcomes of intramedullary screw fixation with a cannulated construct in 15 athletes (Figure 3). They found that the cannulated screws provided favorable clinical outcomes with an average time to return to sport of 7.9 weeks in their cohort. In a separate biomechanical arm, they also compared resistance to fatigue failure of stainless steel and titanium cannulated and noncannulated screws of varying sizes. They found that solid stainless steel screws of larger diameters provided the greatest resistance to fatigue failure [28].





**Figure 3:** Nineteen-year-old female who sustained injury seen in (A) and (B), treated operatively with a 4.5mm partially threaded non-cannulated screw. Post-operative radiograph is seen in (C). Patient was kept non-weight bearing for 2 weeks, and then allowed to weight-bear in a boot until 6 weeks post-op. Antero-posterior and lateral images of foot at 5 weeks post-op are seen in (D) and (E). The patient was then allowed to return to sport at 8 weeks post-op. Final post-op films at 12 weeks are seen in (F) and (G) (Figure 4).



**Figure 4:** Eighteen-year-old male who sustained injury seen in (A) and (B). Post-operative radiographs are seen in (C) and (D). Seven-week post- radiographs are seen in (E) and (F), showing a well healed fracture.

The postoperative recovery in the athlete involves a delicate balance of expeditious return to sport and mitigation of the potential complications and risk of re-injury. Consideration may be given to protective equipment and orthoses, as well as physical therapy and activity restriction. Recommendations regarding this aspect of care vary in the literature. A systematic review of the literature by Roche and Calder revealed a lack of consensus for weight bearing restrictions

(range 1-6 weeks), post-operative immobilization or rehabilitation protocol for return to sport by the 26 studies included [11]. However, several studies have described and recommended specific protocols. Porter et al. thoroughly detailed their rehabilitation protocol in their study. They allowed weight bearing in a CAM boot at post-operative day 3-5. At this time the patients were allowed to begin stationary biking in the boot. At week three the patients were given a rigid orthotic for their shoes and if they had no pain while ambulating in the CAM boot they were allowed to begin weaning to normal shoes with the orthotic. The patients also began a stair stepper program at week 3 and if they were pain free at week 4-5 they were allowed to begin running. If they were able to run pain free they were started in a functional progression program for their sport [6]. Although these authors advocated for a relatively quick return to sport following surgical fixation, this may portend a greater risk of re-fracture. Two separate studies reported a temporal relationship between failure and return to play in athletes treated with intramedullary screw fixation. In one of these, Wright retrospectively evaluated 6 athletes (4NFL, 1 Division I College basketball, and 1 recreational basketball) who had been treated with intramedullary screw fixation. Three of the NFL players re-fractured 1 day after return to full activity and the remaining three re-fractured at an average of 3.6 months after return to play. Larson reported 6 failures (2 refractures and 4 symptomatic nonunions) in a retrospective review of 15 patients who had undergone intramedullary screw fixation for Jones fractures. Five of the six failures were in professional soccer players, Division I collegiate basketball players and Division I collegiate track and field athletes. These failures occurred at a mean of 3.8 months after return to play. The authors in both studies recommended that premature return to play was one of the greatest risk factors for failure and that athletes should not return to play until they had both clinical and radiographic

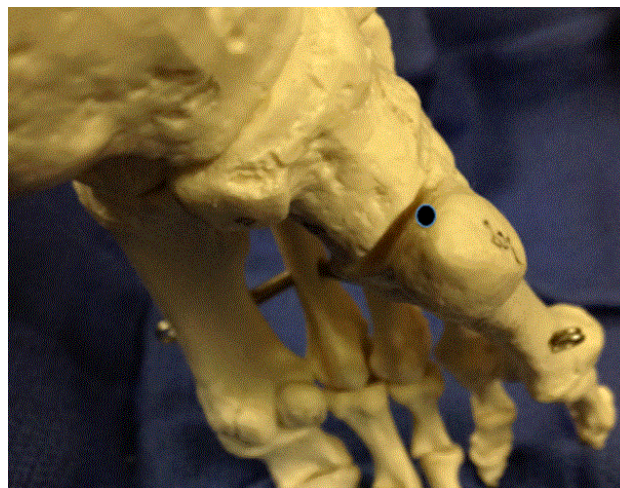union. They recommended that if there was any question about radiographic union on plain films then CT should be considered [29,30].

Modes of immobilization and protection for the immediate postoperative period and during the transition to return to play are also debated. Porter et al. placed all their patients in a CAM walker boot in the immediate post-operative period and allowed weight bearing in the boot with crutches at 3-5 days. They had a 100% union rate with an average return to sport of 7.5 weeks. They advocated for the use of a semi-rigid orthosis for the remainder of the athlete's career to decrease the risk of re-fracture [31]. Raikin et al. retrospectively reviewed the outcomes of 21 patients treated with intramedullary screw fixation. They evaluated hindfoot alignment of all patients and recommended custom orthoses that consisted of a lateral hindfoot wedge with an extended forefoot lateral post so as to unload the lateral column of the foot and prevent re-fracture for those with a varus hindfoot. This strategy yielded a 100% union rate with an average return to play of 12.4 weeks and no re-fractures [3].

It is important that the orthopaedist discuss the potential for delayed union with the athlete prior to initial intervention, as this will invariably result in further missed time. Treatment strategies for re-fracture or nonunion in athletes vary, and there is a paucity of literature to support one over another, but surgical intervention is almost always required. Wright reviewed the outcomes of 6 elite athletes treated for re-fracture after intramedullary screw fixation. Three were treated operatively, two with placement of larger intramedullary screws and one with bone grafting, while the remaining three patients were treated non-operatively with limited activity. Treatment of delayed union or nonunion was largely dictated by the timing of the injury to the playing season. Surgery was performed for those individuals that were symptomatic shortly before the season or towards the end of the season, whereas those treated non-operatively were in the off-season. Regardless of treatment, all six patients went on to union and return to sport [30]. Hunt and Anderson looked at treatment of nonunion or re-fracture in 21 elite athletes. Sixteen of the patients had undergone prior surgery for treatment of the Jones fracture. All patients underwent intramedullary screw fixation and all but one patient had additional bone graft or bone mineral substitute placed. All patients went on to union and returned to sport at their preinjury level of play at an average of 12.3 weeks [8].

**Author's preferred treatment:** Once the diagnosis of Jones fracture is made, an extensive discussion is had with the athlete, athletic trainer, and coach regarding treatment options, return to play, as well as potential sequelae. Attempts at reaching consensus for timing treatment with regards to the athletic season are made with all parties, but ultimately it is the decision of the patient. All athletes should undergo preoperative evaluation of hindfoot alignment with a clinical assessment as described by Raikin et al. This includes evaluation of the Achilles-calcaneal axis, the presence of the "peek-a-boo" heel sign, hindfoot varus, and Coleman block testing [3]. Patients with hindfoot varus are prescribed an orthotic (lateral hindfoot wedge with an extended forefoot lateral post) to be worn for the remainder of their careers during play. All displaced fractures are treated operatively while the vast majority of nondisplaced fractures in the athlete are treated surgically as well in order for a more expeditious return to play. That being said, the vast majority of non-displaced fractures heal reliably with casting and non-weight bearing, but the return to play is significantly slower. Preference is given to non-cannulated partially threaded screws, which are stiffer than cannulated screws, although we

have been using headless compression screws recently as well. Pre-operatively the medullary canal is measured and the largest sized screw that can be safely placed is recommended. We have found 6.5 screws generally to be too large in many cases, but 5.0 screws typically can be placed with relative ease. The screw is placed in the "high and inside" position in order to optimize screw length. Failure to achieve this starting point predisposes to shorter screw length with insufficient purchase distal to the fracture compromising stability and risking non-union (Figure 5).



**Figure 5:** A model demonstrating the correct starting point (black dot) for the guidewire for an intramedullary screw in the "high and inside" position.

Postoperatively, patients are instructed to remain non-weight bearing for 2 weeks in a CAM boot. Progression to weight bearing in the boot is then permitted over a 1-week period. At the 3 week point the athlete is allowed to begin exercises with the stationary bike and if pain free at week 4 the patient is allowed to begin to transition from the boot to a normal shoe equipped with a rigid orthosis as described above. If the patient is pain free with normal shoe wear, then they may begin straight line running at week 5. At week 6, a sport-specific functional training program under the supervision of the athletic trainer is commenced if they are pain free with running. Transition to full athletic activity is typically allowed at the 8th week with close monitoring by the athletic trainer, so long as the patient is asymptomatic with full activity and radiographs do not demonstrate any hardware complications or evidence of delayed union. If the patient is not in midseason, we typically take a slower progression in order to minimize the risk of refracture.

CT scans are recommended for patients with equivocal signs of healing or continued pain with weight bearing. Treatment of nonunions is largely dictated by the timing of surgery. For athletes in season that are able play in the setting of a symptomatic nonunion or those that are suspected of having a delayed union during the off season, consideration may be given to delaying treatment or close observation. Early surgical intervention is recommended for the athlete who is unable to play due to symptomatic nonunion regardless of the playing season or in those whom are symptomatic early in the paying season. We recommend revision of intramedullary screw fixation with a larger diameter screw and addition of bone graft.

### Type III: Diaphyseal stress fractures

These fractures occur in the diaphysis distal to the fourth-fifth intermetatarsal articulation. These fractures are typically the result of repetitive overload and potentially over training in the athlete. These injuries are often difficult to diagnose on standard radiographs. Thus, if patients continue to have pain over the proximal fifth metatarsal, particularly with weight bearing, then consideration should be given to Magnetic Resonance Imaging (MRI). Surgical intervention with intramedullary screw fixation is most typically recommended for athletes, given the prolonged time to healing and return to sport associated with this fracture type [2]. DeLee et al. described their experience treating ten athletes with this injury using percutaneous intramedullary screw fixation. They reported an average time to union of 7.5 weeks and a return to sport at an average of 8.5 weeks [32]. Likewise, Pecina et al. reported a 95% union rate using intramedullary screw fixation in 20 elite athletes with Zone III fractures. Although they reported one case of re-fracture and one athlete who failed to return to play at the same level prior to the injury their overall results with this treatment strategy were favorable [33].

The role of bone grafting for treating these injuries is unclear. Popovic et al. evaluated 17 high level soccer players with Zone III fractures and separated them into two groups: those treated with 4.5mm intramedullary screw fixation and those treated with intramedullary screw fixation with cancellous autograft. They achieved union in all patients with an average return to sport of 12 weeks for both groups. Three patients in the group without autograft and none in the group with autograft had refractures [34]. They surmised that the addition of autograft for these injuries was a reasonable option for primary surgical intervention. However, Thevendran et al. performed a review of the literature to elucidate the role of primary bone grafting with intramedullary screw fixation and concluded that there was insufficient evidence to support its routine use in the primary setting [2].

**Author's preferred treatment:** If there is a high suspicion that a patient may have a Type III stress fracture but the patient has normal radiographs, then an MRI is obtained. Once the diagnosis of a diaphyseal stress fracture is made, a discussion is had with the athlete, athletic trainer and coach regarding treatment options, return to play, as well as potential sequelae. Most typically, surgical intervention in the form of intramedullary screw fixation is recommended for those fractures seen on x-ray. For those identified via MRI only, we will typically treat an off-season athlete with a trial of non-weight bearing while in-season athletes are typically treated surgically. We do not use bone graft supplementation regularly unless it is a chronic stress fracture. Postoperatively the patient is placed in a controlled ankle motion boot and kept non-weight bearing for 2 weeks. We use the same post-operative protocol as that used for Jones fractures. As above, we recommend a CT scan for patients who continue to be symptomatic or do not have radiographic signs of union. For those with a symptomatic nonunion, we perform revision intramedullary screw fixation with a larger diameter screw with bone graft supplementation. Generally bone graft harvest from the distal or proximal tibia is used.

### Conclusion

Fractures of the proximal fifth metatarsal are injuries that are routinely encountered by the orthopaedic surgeon caring for high-level athletes. The morphology and location of the fracture, the goals of the

athlete, and timing of the injury in relation to the athletic season dictate the approach to treatment of these patients. Fractures of the tuberosity can be reliably treated non-operatively in the vast majority of patients with reliable return to play for most in less than 8 weeks. While Type I Jones fractures can be treated with non-operative measures, there is a trend towards early operative treatment and the discussion must had with athlete discussing the risks and benefits as well as taking into account the timing of injury in relation to the athletic season. There is an increasing amount of literature showing that Jones fractures in athletes treated with intramedullary screw fixation have faster return to play with better overall results. For the diaphyseal stress fracture the accepted treatment and our standard is operative treatment with intramedullary screw fixation. Overall fractures of the proximal fifth metatarsal are injuries that can be reliably treated with recent improvements in treatment resulting in quicker return to play than ever before.

### References

1. Jones R (1902) Fracture of the Base of the Fifth Metatarsal Bone by Indirect Violence. *Ann Surg* 35: 697-700.
2. Thevendran G, Deol RS, Calder JD (2013) Fifth metatarsal fractures in the athlete: evidence for management. *Foot Ankle Clin* 18: 237-254.
3. Raikin SM, Slenker N, Ratigan B (2008) The association of a varus hindfoot and fracture of the fifth metatarsal metaphyseal-diaphyseal junction: the Jones fracture. *Am J Sports Med* 36: 1367-1372.
4. Low K, Noblin JD, Browne JE, Barnhouse CD, Scott AR (2004) Jones Fractures in the elite football player. *J Surg Orthop Adv* 13: 156-160.
5. Mologne TS, Lundeen JM, Clapper ME, O'Brien TJ (2005) Early screw fixation versus casting in the treatment of acute Jones fractures. *Am J Sports Med* 33: 970-975.
6. Porter DA, Rund AM, Dobslaw R, Duncan M (2009) Comparison of 4.5- and 5.5-mm cannulated stainless steel screws for fifth metatarsal Jones fracture fixation. *Foot Ankle Int* 30: 27-33.
7. Donaldson L, Li B, Cusimano MD (2014) Economic burden of time lost due to injury in NHL hockey players. *Inj Prev* 20: 347-349.
8. Hunt KJ, Anderson RB (2011), Treatment of Jones fracture nonunions and refractures in the elite athlete: outcomes of intramedullary screw fixation with bone grafting. *Am J Sports Med* 39: 1948-1954.
9. Den Hartog, Bryan D (2009) Fracture of the proximal fifth metatarsal. *J Am Acad Orthop Surg* 17: 458-464.
10. Sarimo J, Rantanen J, Orava S, Alanen J (2006) Tension-band wiring for fractures of the fifth metatarsal located in the junction of the proximal metaphysis and diaphysis. *Am J Sports Med* 34: 476-480.
11. Roche AJ, Calder JD (2013) Treatment and return to sport following a Jones fracture of the fifth metatarsal: a systematic review. *Knee Surg Sports Traumatol Arthrosc* 21: 1307-1315.
12. Kerkhoffs GM, Versteegh VE, Siersevelt IN, Kloen P, Dijk CN (2012) Treatment of proximal metatarsal V fractures in athletes and non-athletes. *Br J Sports Med* 46: 644-648.
13. Rosenberg GA, Sferra JJ (2000) Treatment strategies for acute fractures and nonunions of the proximal fifth metatarsal. *J Am Acad Orthop Surg* 8: 332-8.
14. Ritchie JD, Shaver JC, Anderson RB, Lawrence SJ, Mair SD (2011) Excision of symptomatic nonunions of proximal fifth metatarsal avulsion fractures in elite athletes. *Am J Sports Med* 39: 2466-2469.
15. Smith JW, Arnoczky SP, Hersh A (1992) The intraosseous blood supply of the fifth metatarsal: implications for proximal fracture healing. *Foot Ankle* 13: 143-152.
16. Quill GE (1995) Fractures of the proximal fifth metatarsal. *Orthop Clin North Am* 26: 353-361.
17. Dameron TB (1995) Fractures of the Proximal Fifth Metatarsal: Selecting the Best Treatment Option. *J Am Acad Orthop Surg* 3: 110-114.



18. Torg JS, Balduini FC, Zelko RR, Pavlov H, Peff TC, et al. (1984) Fractures of the base of the fifth metatarsal distal to the tuberosity. Classification and guidelines for non-surgical and surgical management. *J Bone Joint Surg Am* 66: 209-214.
19. Torg JS (1990) Fractures of the base of the fifth metatarsal distal to the tuberosity. *Orthopedics* 13: 731-737.
20. Richli WR, Rosenthal DI (1984) Avulsion fracture of the fifth metatarsal: experimental study of pathomechanics. *AJR Am J Roentgenol* 143: 889-891.
21. Rettig AC, Shelbourne KD, Wilckens J (1992) The surgical treatment of symptomatic nonunions of the proximal (metaphyseal) fifth metatarsal in athletes. *Am J Sports Med* 20: 50-54.
22. Leumann A, Pagenstert G, Fuhr P, Hintermann B, Valderrabano V (2008) Intramedullary screw fixation in proximal fifth-metatarsal fractures in sports: clinical and biomechanical analysis. *Arch Orthop Trauma Surg* 128: 1425-1430.
23. Kelly IP, Glisson RR, Fink C, Easley ME, Nunley JA (2001) Intramedullary screw fixation of Jones fractures. *Foot Ankle Int* 22: 585-589.
24. Josefsson PO, Karlsson M, Redlund-Johnell I, Wendeberg B (1994) Closed treatment of Jones fracture Good results in 40 cases after 11-26 years. *Acta Orthop Scand* 65: 545-547.
25. Pietropaoli MP, Wnorowski DC, Werner FW, Fortino MD (1999) Intramedullary screw fixation of Jones fractures: a biomechanical study. *Foot Ankle Int* 20: 560-563.
26. Ochenjele G, Ho B, Switaj PJ, Fuchs D, Goyal N, et al. (2015) AR2Radiographic study of the fifth metatarsal for optimal intramedullary screw fixation of Jones fracture. *Foot Ankle Int* 36: 293-301.
27. Orr JD, Glisson RR, Nunley JA (2012) Jones fracture fixation: a biomechanical comparison of partially threaded screws versus tapered variable pitch screws. *Am J Sports Med* 40: 691-698.
28. Reese K, Litsky A, Kaeding C, Pedroza A, Shah N (2004) Cannulated screw fixation of Jones fractures: a clinical and biomechanical study. *Am J Sports Med* 32: 1736-1742.
29. Larson CM, Almekinders LC, Taft TN, Garrett WE (2002) Intramedullary screw fixation of Jones fractures. Analysis of failure. *Am J Sports Med* 30: 55-60.
30. Wright RW, Fischer AD, Shively RA, Heidt RS, Nuber GW (2000) Refracture of proximal fifth metatarsal (Jones) fracture after intramedullary screw fixation in athletes. *Am J Sports Med* 28: 732-736.
31. Porter DA, Duncan M, Meyer SJ (2005) Fifth metatarsal Jones fracture fixation with a 4.5-mm cannulated stainless steel screw in the competitive and recreational athlete: a clinical and radiographic evaluation. *Am J Sports Med* 33: 726-733.
32. DeLee JC, Evans JP, Julian J (1983) Stress fracture of the fifth metatarsal. *Am J Sports Med* 11: 349-753.
33. Pecina M, Bojanic I, Smoljanovic T, Ivkovic A, Mirkovic M, et al. (2011) Surgical treatment of diaphyseal stress fractures of the fifth metatarsal in competitive athletes: long-term follow-up and computerized pedobarographic analysis. *J Am Podiatr Med Assoc* 101: 517-522.
34. Popovic N, Jalali A, Georise P, Gillet P (2005) Proximal fifth metatarsal diaphyseal stress fracture in football players. *Foot Ankle Surg* 11: 135-141.