

Extraskelatal Osteochondroma of the Heel: A Case Report

Bilgin Y, Karademir G*, Anarat B and Salduz A

Istanbul University, Istanbul Faculty of Medicine, Istanbul, Turkey

Abstract

Osteochondroma is the most common benign bone tumor and usually occurs in the metaphyseal region of the long bones around the knee. This is a cartilage-capped bony tumor, which outgrows on the surface of the bone. Extraskelatal osteochondroma is a variant of extraskelatal chondromas that are uncommon soft-tissue cartilaginous tumors. This report describes the case of a 56-year-old woman with an extraskelatal osteochondroma of the heel.

Keywords: Extraskelatal osteochondroma; Soft-tissue chondroma; Foot; Heel

Introduction

Osteochondroma are present approximately 10–15% of all bone tumors [1]. Usually represent as cartilage capped tumor around the knee such as proximal tibia and distal femur. Extraskelatal osteochondromas also seen rarely. Peak occurrence is during the 3rd and 6th decades [2]. Extraskelatal osteochondromas are often benign tumors and local excision is known as the Standard treatment if tumor is symptomatic [3]. With only few data on literature, treatment choice may depend on the risk of malignant transformation. This article presents a case of an extraskelatal osteochondroma arising of heel.

Case Report

A 56-year-old woman was admitted with gradually increasing right heel pain, recent swelling and difficulty walking. Patient's pain had been present for 5 years and have increased over the last 3 months. She had been treated with physical therapy with a diagnosis of calcaneal spurs for a year. Clinical examination revealed a nodule measuring 5×2 cm, localized swelling in the heel, cavus of foot, and tenderness to palpation located on the heel of right foot (Figure 1). X-ray showed soft tissue mass near by calcaneus at the plantar face of foot (Figure 2), which has central ossification and does not reach cortical space. Routine laboratory tests were within normal limits. Magnetic resonance imaging (MRI) showed a mass lesion has seen approximately 46×23 mm hypointense (centrally isointense) in T1 weighted images and heterogeneous hyperintense in T2 weighted images.

Excisional biopsy planned for this mass on plantar face with pre-diagnosis of osteochondroma and heterotopic ossification. The tumor was completely resected under general anesthesia (Figure 3), revealing a yellowish mass with a thin capsule loosely connected to the soft tissues around heel but without any adhesion to the bone. Histologic examination showed benign osteochondromatous lesion, circumscribed lobulated nodular lesion covered with a fibrous capsule (Figure 4). The layers from outside to inside; Fibrous capsule, mature hyaline cartilage, central ossification area. After removal of mass, patient relieved. Recurrence didn't happen 18 months followup.

Discussion

Extraskelatal osteochondromas, are slow growing solitary nodules of hyaline cartilage seen rarely [4]. It presents as cartilage covered bone mass in soft tissue. Hands, specifically fingers is the most common site for this tumor, foot comes the second. Also researches showed widerange of locations for extraskelatal osteochondromas [3] in 2013 [4]. In 2010 reported similar cases in the plantar aspect of foot [5].

in 2008 reported single case of osteochondroma in infrapatellar fat pad [6]. In 2012 showed one in elbow joint [7]. In 2010 reported an extraskelatal osteochondroma near hip joint in a pediatric patient [8]. In 2006 reported a osteochondroma in the nape of the neck.

There is couple theories for development of heel pad osteochondromas, some researchers come up with idea that it might

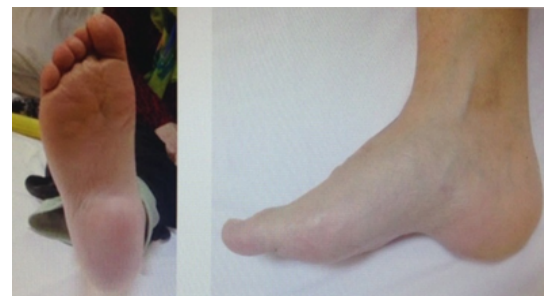

Figure 1: Nodule located at heel, localized swelling, cavus of foot.

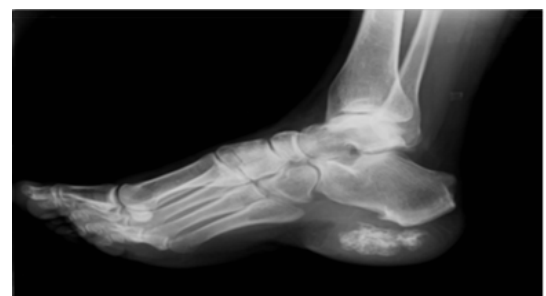

Figure 2: Soft tissue mass nearby calcaneus at the plantar face of foot with central ossification areas and does not reach cortical space.

*Corresponding author: Dr. Karademir G, Istanbul University, Istanbul Faculty of Medicine, Istanbul, Turkey, Tel: 269724111; E-mail: dr@gokhankarademir.com

Received October 08, 2015; Accepted October 24, 2015; Published November 02, 2015

Citation: Bilgin Y, Karademir G, Anarat B, Salduz A (2015) Extraskelatal Osteochondroma of the Heel: A Case Report. J Orthop Oncol 1: 101. doi: 10.4172/2472-016X.1000101

Copyright: © 2015 Bilgin Y, et al. This is an open-access article distributed under the terms of the Creative Commons Attribution License, which permits unrestricted use, distribution, and reproduction in any medium, provided the original author and source are credited.

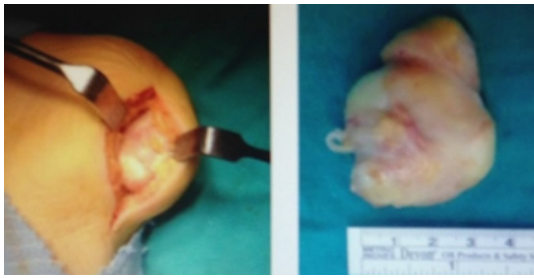


Figure 3: Sugical image (left side) - Gross specimen (right side) with a thin capsule loosely connected to the soft tissues.

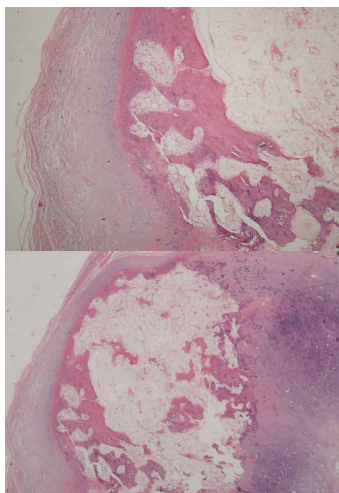


Figure 4: Findings of an HE-stained specimen, showed circumscribed lobulated nodular lesion covered with a fibrous capsule.

develops as metaplasia of plantaraponeurosis [4,8]. Also, Singh et al. said it can form as separation from calcaneal osteochondroma in one of their case report [4].

An extraskelletal osteochondroma often presents with central calcification or ossification are as that are not reaching cortex of bone in radiologic images. Other cases in literature shows MRI is the best for seeing the borders of the mass clearly, which is important for distinguish it from malignant tumors. On MRI, extraskelletal osteochondrom appears as intermediate intensity on T1-weighted images, whereas it appears as a high signal intensity on T2-weighted images [9].

The differential diagnosis includes myositis ossificans, tumoral calcinosis, extraskelletal osteosarcoma, synovial chondromatosis, soft tissue osteochondromas and extraskelletal osteosarcoma, pseudomalignant osseous tumor and an ossifying fibromyxoid tumor [10]. Mature ossification is usually associated with benign lesion.

There is 1-2% malignant transformation risk in classic osteochondromas [11,12]. Similar to our case report, there was no malignant transformation or recurrence at this sporadic cases [3]. In 2013 reported lesion with 6×3×3 cm size, no recurrence had developed by 5 month follow-up [13]. In 2013 reported a large extraskelletal osteochondroma of heel with 10×8 cm size, followed up by 30 months and still no recurrence or malignant formation had occurred. Even so it is hard to discuss about malignant transformation as there is only few cases reported, and most of them are without follow up. For

this reason, like other osteochondromas, conditions as large mass, cartilage cap thicker than 1-2 cm, rapid growth and new onset of pain which increases the risk of malignant transformation in extraskelletal osteochondromas and it should be considered for excision [12,14,15]

Conclusion

Osteochondromas, is the most common benign tumor of bone and rarely seen extraskelletally. It has been reported that they have low risk of malignant degeneration. We think, no surgical treatment is needed as long as these osteochondromas does not have risk factors for malignant transformation and stay asymptotically, otherwise surgical excision should be the choice of treatment.

References

1. Dahlin DC, Unni KK (1986) *Bone Tumors*. (4th edn), Charles C Thomas Publication, Springfield.
2. Dahlin DC, Salvador AH (1974) Cartilaginous tumors of the soft tissues of the hands and feet. *Mayo ClinProc* 49: 721–726.
3. Estil JC Jr, Yeo ED, Kim HJ, Cho WT, Lee JJ (2013) A large extraskelletal osteochondroma of the foot. *J Foot Ankle Surg* 52: 663–665.
4. Singh R, Jain M, Siwach R, Sen R, Rohilla RK, et al. (2010) Soft-tissue osteochondroma of the heel pad: a case report and review of literature. *Foot Ankle Surg* 16: e76–e78.
5. Lim SC, Kim YS, Kim YS, Moon YR (2003) Extraskelletal osteochondroma of buttock. *J KoreanMedSci* 18: 127–130.
6. Narula R, Arya A, Verma L, Singh S (2012) Soft Tissue Osteochondroma in Elbow Joint: A case report. *Malays Orthop J* 6: 53–56.
7. Liu ZJ, Zhao Q, Zhang LJ (2010) Extraskelletal osteochondroma near the hip: a pediatric case. *J Pediatr Orthop B* 19: 524–528.
8. Singh R, Sharma AK, Magu NK, Kaur KP, Sen R (2006) Extraskelletal osteochondroma in the nape of the neck: a case report. *J Orthop Surg (Hong Kong)* 14: 192–195.
9. Kransdorf MJ, Meis JM (1993) From the archives of the AFIP. Extraskelletal osseous and cartilaginous tumors of the extremities. *Radiographics* 13: 853–884.
10. Turhan E, Doral MN, Atay AO, Demirel M (2008) A giant extrasynovial osteochondroma in the infrapatellar fat pad: end stage Hoffa's disease. *Arch Orthop Trauma Surg* 128: 515–519.
11. Nakanishi H, Araki N, Mukai K, Ohno H, Matsui Y (2001) Soft-tissue osteochondroma in the calcaneal pad: a case report. *J Foot Ankle Surg* 40: 396–400.
12. Batra S, Garg B, Arora S (2013) Large soft tissue osteochondroma of the heel: a case report and literature review. *Musculoskelet Surg* 97: 255–258.
13. Malik R, Kapoor N, Malik R (2004) Transformation of solitary osteochondroma calcaneum to chondrosarcoma—a case report. *Indian J Pathol Microbiol* 47: 42–43.
14. Sheff JS, Wang S (2005) Extraskelletal osteochondroma of the foot. *J foot Ankle Surg* 44: 57–59.
15. Weiss SW, Goldblum JR (2007) *Cartilaginous soft tissue tumors*. In: Enzinger and Weiss's *Soft Tissue Tumors* (5th edn). St. Louis: Mosby 1017–1036.