

Diagnosis of Pericardial Cyst Using Multiple Cardiac Imaging Modalities

Julia Zheng¹, Patrick O'Beirne², Edward Wroblewski², Kenneth Khaw², John Saia², Gerald Ukrainski², Chad Bousanti², LJ Wehner^b and Jingsheng Zheng^{2*}

¹Department of Neuroscience, University of Pittsburgh, USA

²AtlantiCare Medical Center, Pomona, New Jersey, USA

*Corresponding author: Jingsheng Zheng, Medical Director, Non-invasive Cardiovascular Imaging, AtlantiCare Regional Medical Center, Pomona, New Jersey 08205, USA, Tel: 609-561-8500; Fax: 609-567-0432; E-mail: jszheng@comcast.net

Received date: October 02, 2015; Accepted date: October 23, 2015, 2015; Published date: October 26, 2015

Copyright: © 2015 Zheng J, et al. This is an open-access article distributed under the terms of the Creative Commons Attribution License, which permits unrestricted use, distribution, and reproduction in any medium, provided the original author and source are credited.

Abstract

Pericardial cysts are rare mediastinal abnormalities. We report on a 54-year-old male, who was found to have a large right-sided pericardial cyst incidentally. Multiple imaging modalities including 2D echocardiography, contrast echocardiogram with DEFINITY, transesophageal echocardiography and CT scan were used to delineate the features of the pericardial cyst. Patient was asymptomatic and was managed conservatively.

Keywords: Pericardial cyst; Echocardiography; Transesophageal echocardiography; Contrast echocardiography

Introduction

Pericardial cysts are a rare benign anomaly in the mediastinum. They are often found in either cardiophrenic angle. It is postulated that pericardial cysts are derived from failed fusion of one of the mesenchymal lacunae normally forming the pericardial sac [1]. Incidence of pericardial cysts is estimated to be 1:100,000 [2]. Pericardial cysts consist of about 7% of all mediastinal masses [2,3].

Most commonly, they have no associated symptoms and are discovered incidentally during a routine chest X-ray or echocardiography. Episodes of chest pain, shortness of breath, cough or persistent arrhythmia have been described. Other complications, such as congestive heart failure, right ventricular outflow tract obstruction, infection and pulmonary stenosis have been reported. CT scan, MRI and transesophageal echocardiography are the common imaging modalities of choice for diagnosis and follow up.

Case Presentation

This is a 54-year-old white male with past medical history of hypertension, who was admitted to a local hospital with chief complaint of diarrhea, vomiting and epigastric pain. He denies chest pain or shortness of breath. He has "fullness" feeling at the epigastric area for several years. In the emergency room, patient underwent CTA of the chest to rule out pulmonary embolism.

CTA of the chest revealed a thin-walled, sharply defined and oval homogenous right mediastinal mass, measuring $5.9 \times 4.0 \text{ cm}^2$, suggestive of a pericardial cyst (Figure 1).

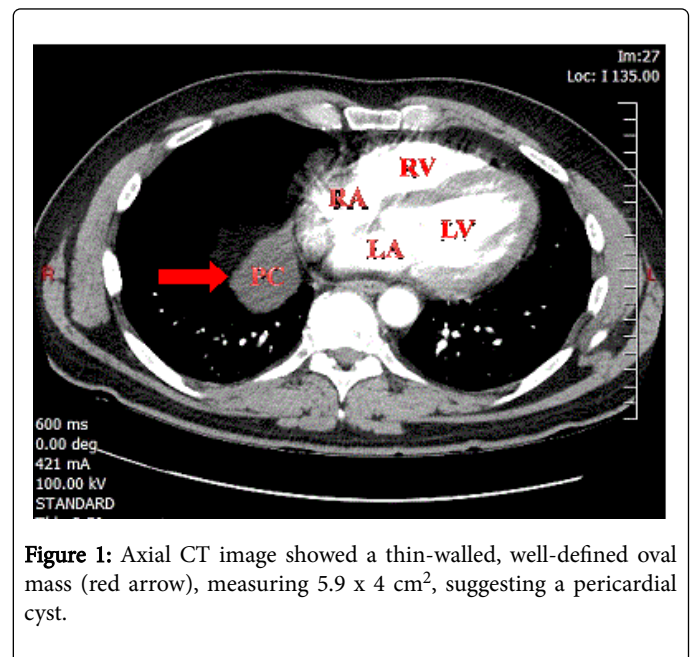


Figure 1: Axial CT image showed a thin-walled, well-defined oval mass (red arrow), measuring $5.9 \times 4 \text{ cm}^2$, suggesting a pericardial cyst.

Patient was discharged from the emergency room and was referred to us due to the pericardial cyst. Patient was asymptomatic. Routine transthoracic echocardiogram (2D echo) revealed a $4.1 \times 4.4 \text{ cm}^2$ cystic structure (red arrow) adjacent to the right atrium, consistent with possible pericardial cyst (Figure 2).

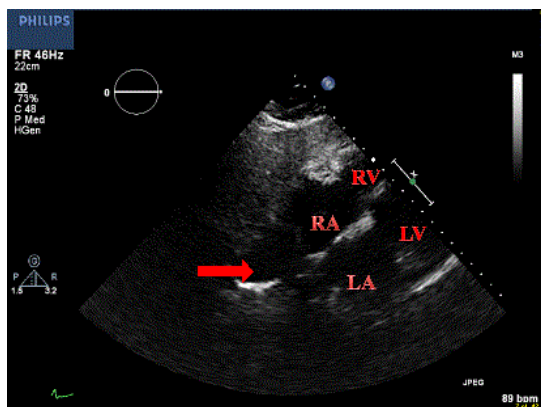


Figure 2: Subcostal echocardiographic view revealed 4.1 x 4.4 cm² cystic structure (red arrow) adjacent to the right atrium, which may represent pericardial cyst. 2D echocardiogram was performed using Philips iE33 xMatrix with X5-1 probe.

DEFINITY is a perflutren lipid microsphere and is injected intravenously to opacify cardiac chambers and to improve the delineation of the endocardial border. Figure 3 shows DEFINITY opacifies the right atrium and the right ventricle. However, the pericardial cyst, which is adjacent to the right atrium, does not fill with the contrast agent. This study suggests that there is no communication between pericardial cyst and the heart.

To further delineate the structure of the pericardial cyst, a transesophageal echocardiogram (TEE) was performed. TEE revealed a large pericardial cyst adjacent to the right atrium which had no direct communication with the pericardial space (Figure 4). Since the patient was asymptomatic from a cardiac point of view, he was offered conservative management.

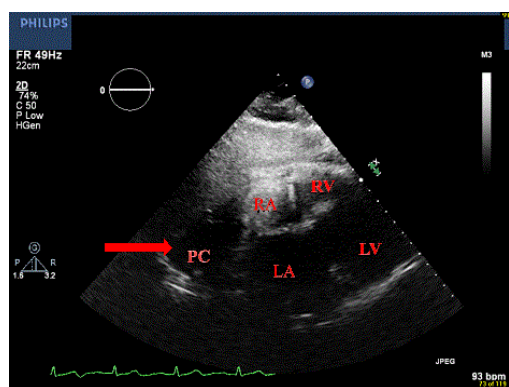


Figure 3: 2D echocardiography with subcostal echocardiographic view using a contrast agent DEFINITY, which opacifies right atrium and right ventricle. However the pericardial cyst, which is adjacent to the right atrium, does not fill with contrast agent.

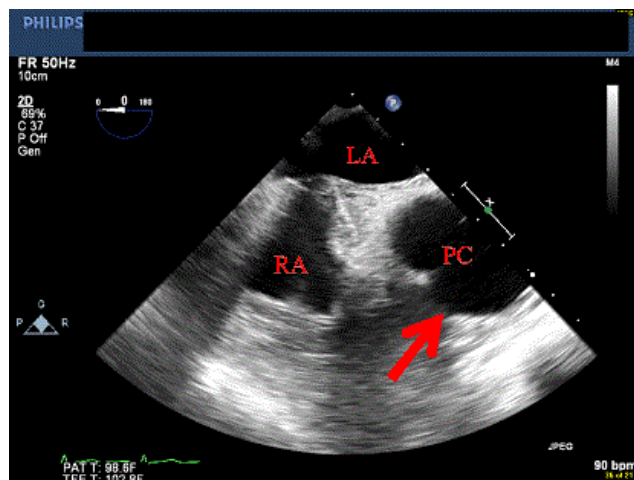


Figure 4: TEE with mid-esophageal bicaval view revealed large pericardial cyst (red arrow, PC). TEE was performed on the same setting as the 2D TEE using Philips iE33 xMATRIX with X7-2t probe in this study.

Discussion

Pericardial cysts are a rare congenital abnormality that occurs in the middle mediastinum. Pericardial cysts range from 1 to 5 cm in size [4]. They are rarely found in children and are more commonly found in the third or fourth decade of the life [3]. They usually have no communication with the pericardial space. They are unilocular, have smooth walls with an outer layer of endothelial or mesothelial cells. They are usually asymptomatic and are often discovered incidentally on chest X-ray. Echocardiography can further delineate the cardiac structures as it can differentiate other possible cardiac abnormalities, such as left ventricular aneurysm, aortic aneurysm, prominent fat pad or a loculated pericardial effusion. 2D echo with contrast agent and TEE may provide incremental value in the diagnosis of pericardial cyst. In this case report, we used multiple imaging modalities, including 2D echo, TEE and CT scan to characterize the pericardial cyst. To the best of our knowledge, this is the first report, using contrast agent (DEFINITY) to further characterize a pericardial cyst.

The management of pericardial cysts depends on the appearance of the cysts and symptoms of the patient. Asymptomatic patients can be managed conservatively with close follow up. Some pericardial cysts may resolve spontaneously, the probable mechanism being the rupture of the cyst. For patients with pericardial cysts who develop symptoms, percutaneous aspiration or surgical excision with either a thoracotomy or video-assisted thoracoscopic surgery should be considered [5-7].

References

1. Elamin WF, Hannan K (2008) Pericardial cyst: an unusual causes of pneumonia. Cases Journal 1: 26.
2. Hynes JK, Tajik AJ, Osborn MJ, Orszulak TA, Seward JB (1983) Two-dimensional echocardiographic diagnosis of pericardial cyst. Mayo Clin Proc 58: 60-63.
3. Jabr FL, Skeik N (2010) Pericardial cyst. Intern Med 49: 805-806.

-
4. Frisoli T, Grosu H, Paul S, Eden E (2011) Recurrent rupture of a pericardial cyst presenting as syncope, pleuropericarditis, and pneumonitis. *Chest* 140: 90A.
 5. Najib MQ, Chaliki HP, Raizada A, Ganji JL, Panse PM, et al. (2011) Symptomatic pericardial cyst: a case series. *Euro J Echo* 12: E43.
 6. Butz T, Faber L, Langer C, Wiemer M, Horstkotte D, et al. (2007) Echocardiography-guided percutaneous aspiration of a large pericardial cyst. *Circulation* 116: e505-e507.
 7. Patel J, Park C, Michaels J, Rosen S, Kort S (2004) Pericardial cyst: case reports and a literature review. *Echocardiography* 21: 269-272.