

Resection of Bilateral Giant Achilles Tendon Xanthomas with a Tendon Sparing Technique- A Case Report

Wouter Eilander* and Frank Faber

Resident Orthopaedic Surgeon, Haga Hospital, The Hague, The Netherlands

*Corresponding author: Dr. Wouter Eilander, Resident Orthopaedic Surgeon, Haga Hospital, The Hague, The Netherlands, Tel: 0031638329621; E-mail: wouter104@hotmail.com

Received date: May 21, 2014, Accepted date: Jul 29, 2014, Published date: Jul 31, 2014

Copyright: © 2014 Eilander W, et al. This is an open-access article distributed under the terms of the Creative Commons Attribution License, which permits unrestricted use, distribution, and reproduction in any medium, provided the original author and source are credited.

Abstract

Xanthomatosis is a disease in which large tendon tumors can occur, especially in the Achilles tendon. We report a case of a seventy-five year old patient with giant bilateral Achilles tendon xanthomas in which both tumors were resected. Approximately fifty percent of both Achilles tendons could be spared, so no reconstruction using autograft tendon was necessary. Postoperative treatment consisted of six weeks lower leg cast immobilization. After 12 weeks the patient was able to walk pain free en wear footwear without any difficulties. It has been suggested that a subtotal resection leads to a higher recurrence rate of the tumor. On the other hand, it is associated with fewer complications compared to total excision with augmentation. 18 months after surgery our patient had no signs of recurrence of Achilles tendon swelling.

Keywords: Xanthomatosis; Tendon tumors; Achilles tendon; Benign tumors

Introduction

Large benign tumors in tendons are uncommon. Xanthomatosis is a disease in which such large tumors can occur. They are usually slowly growing. The cause is an accumulation of fatty lipids in tendons, especially the Achilles tendons. No data have been published on the incidence, but the benign bilateral Achilles tendon fat accumulation is a rare disease [1,2]. It is mainly found in patients with heterozygous familial hypercholesterolaemia (FH) or, less common, in patients with cerebro tendinosis xanthomasis [3]. In patients with FH, xanthomatosis becomes increasingly common from the third decade of life [4]. FH is characterized by increased LDL cholesterol, tendon xanthomas, coronary disease and autosomal dominant transmission [1].

We report a case of a patient with giant bilateral Achilles tendon xanthomas, not known with FH, in which both tumors were resected with a tendon sparing technique. This contrasts other reports that described the necessity of tendon reconstruction when resecting large xanthomas [3,5].

Case Report

A seventy-five year old woman presented at our clinic for a second opinion. She had complaints of pain and swelling in both Achilles tendons. The swellings began several years ago and were progressive. Finally she had difficulties wearing footwear and increasing pain sensation especially during long distance walking (> 3km) or while playing tennis. Medical history showed one episode of coronary heart disease several years ago. She was not known with FH. The primary treating orthopedic surgeon performed a non-invasive work up: the results of an ultrasonography and MRI scan (Figure 1) of both tumors were inconclusive. Subsequently a biopsy from the right Achilles tendon tumor was taken, which showed signs of an old hematoma.

Although a malignancy was excluded, no clear diagnosis could be made. Conservative treatment with non-steroid anti-inflammatory drugs and cast immobilization did not cause any improvement and the patient was referred to us. Because the diagnosis was highly suggestive for xanthomatosis, we decided to excise both tumors in two separate sessions, with the intention only to augment the Achilles tendon when it appeared necessary to remove more than fifty percent of the Achilles tendon. This was not the case in both procedures. Postoperative treatment consisted of two weeks non-weight bearing lower leg cast immobilization followed by four weeks with lower leg weight bearing cast. After this period the patient was treated by a physiotherapist to regain muscle strength and ankle mobility. Twelve weeks after the second procedure the patient had full range of motion of the ankle and was able to walk pain free en wear footwear without any difficulties. She could perform a bilateral single foot heel raise. 18 months later the swellings did not recur and patient was able to walk long distances and play tennis without any pain. Strength assessment of ankle plantar flexion with a hand-held dynamometer revealed a strength of 197 Newton at the right ankle and 205 Newton at the left ankle. This corresponds to normal plantar flexion strength for an older woman [6].

Pathology report after surgery confirmed that the characteristics of both excised tumors were consistent with those of xanthomas. Patient's serum LDL cholesterol was obtained after the second surgical procedure. In our laboratory this was at the higher limits of normal (3.5 mmol/L).

Operative Technique

Surgery was performed with the patient in prone position and under spinal anesthesia. An upper limb tourniquet inflated to 300 mm Hg was used. A midline incision over the tumor was made. Subsequently, the tumor was mobilized and very carefully resected from the tendon until vital tendon tissue appeared. For both legs approximately fifty percent of the tendon could be spared, so no augmentation was necessary. In the left leg, the tendon of the plantaris

muscle was resected. The wound was closed in layers. See figure 2 for photographs of the procedure and the clinical end result.

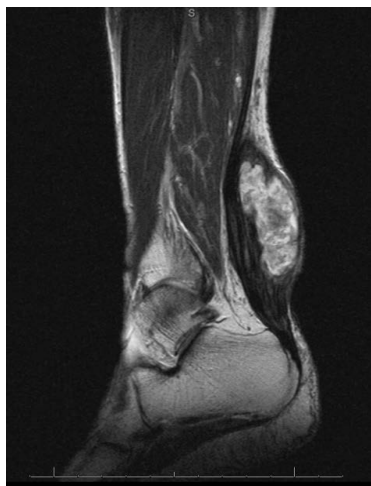

Figure 1a: Sagittal MRI view of the xanthoma in the right Achilles tendon.

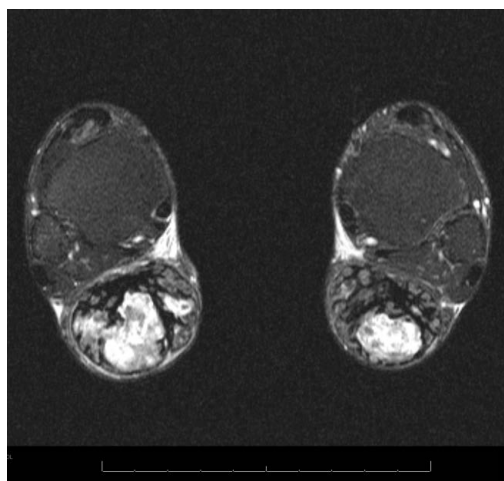


Figure 1b: Transversal view of the Achilles tendon xanthomas in both legs.

Discussion

Achilles tendon xanthomatosis is a rare disease. It is strongly linked to FH. Interestingly, our patient was not known with FH and possessed only two of the main characteristics of FH. She suffered coronary heart disease and developed Achilles tendon xanthomas. A raise of serum LDL cholesterol could not be found in multiple serum samples. However, this does not exclude a dyslipidemia because we did not perform a detailed lipid analysis [7].

Junyent et al. compared Achilles tendon sonography in patients with FH and in patients with non-FH dislipidemias. It appeared that sonographic xanthomas were only found in patients with FH. Therefore, they concluded Achilles tendon xanthomatosis might be

helpful in diagnosing FH [8]. Moreover, it may also be helpful in preventing cardiovascular disease as several authors suggested that xanthomas are associated with a high risk for cardiovascular disease in patients with FH [4,9]. This is supported by a review of Fahey et al in which the authors showed that a majority of patients with Achilles tendon xanthomas had a family history of coronary disease [3].

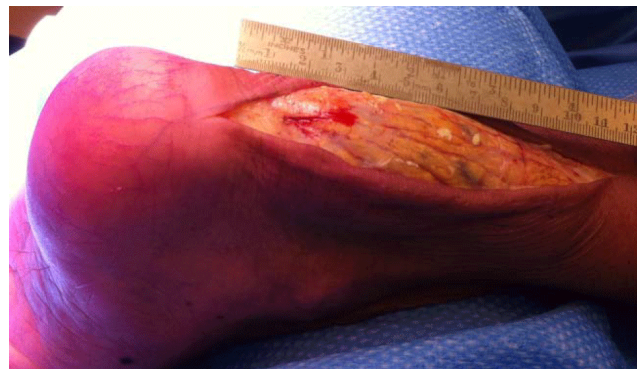

Figure 2a: The tumor of the left Achilles tendon exposed.

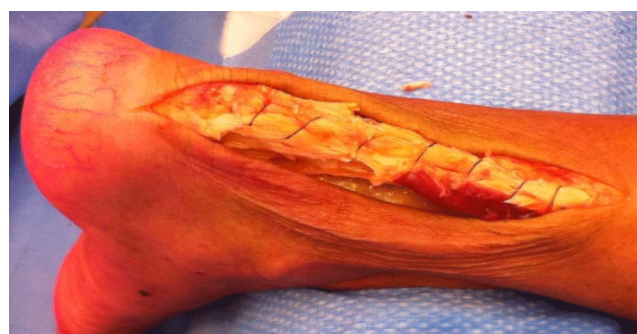

Figure 2b: After resection approximately 50% of the tendon was intact.

We decided to perform a tendon sparing resection of the xanthomas. However macroscopically both tumors were excised in total, its infiltration into the tendon made a subtotal resection inevitable. Carranza-Bencano et al. stated, in case of severe xanthomas infiltration, total resection is the best surgical technique [1] to avoid the risk of recurrence. As summarized by Huang et al. there are several procedures for Achilles tendon reconstruction. Autogeneous tendon grafts such as the peroneus brevis or flexor hallucis longus (FHL) are commonly used. The authors described a reconstruction with a tibialis posterior autograft, which was necessarily because of a large tendon defect after extensive resection [5]. We also performed an extensive resection resulting in a partial tendon defect, but decided to qualify the procedure as 'tendon sparing' (without reconstruction) when at least fifty percent of the cross-section tendon was saved. We believe this technique is a less invasive procedure, especially because other tendons (FHL, tibialis posterior and peroneus brevis tendon) and their functions remain intact, resulting in faster recovery. The patient started weight bearing after two weeks where others reported non-weight bearing periods of six weeks [3] or almost nine weeks [5].

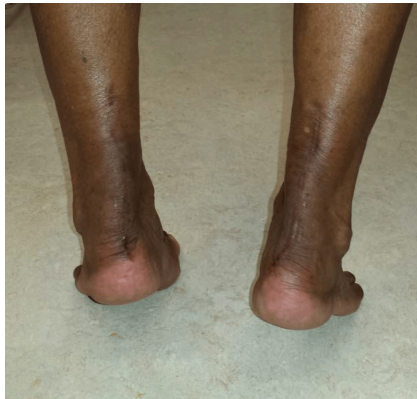

Figure 2c: Clinical result after 18 months. The patient is able to perform a heel raise.

Moreover, a subtotal tendon resection is associated with fewer complications compared to total excision with reconstruction [10]. For example, reconstruction of the Achilles tendon with the FHL tendon may lead to impaired flexion at the hallux interphalangeal joint and first metatarsophalangeal joint [3].

It has been suggested that a subtotal resection leads to a higher recurrence rate of the tumor [3]. In a follow-up period of 18 months, our patient had no signs of recurrence of Achilles tendon swelling. However, recurrence of the tumors in the next years cannot be excluded. But with its slow-growing characteristic it may not lead to clinical symptoms at the age of our patient (75 years).

References

1. Carranza-Bencano A, Fernández-Centeno M, Leal-Cerro A, Duque-Jimeno V, Gomez-Arroyo JA, et al. (1999) Xanthomas of the Achilles tendon: report of a bilateral case and review of the literature. See comment in PubMed Commons below *Foot Ankle Int* 20: 314-316.
2. Fahey JJ, Stark HH, Donovan WF, Drennan DB (1973) Xanthoma of the achilles tendon. Seven cases with familial hyperbetalipoproteinemia. *J Bone Joint Surg Am* 55: 1197-1211.
3. Moroney PJ, Besse JL. Resection of bilateral massive Achilles tendon xanthomata with reconstruction using a flexor hallucis longus tendon transfer and Bosworth turndown flap: A case report and literature review. *Foot Ankle Surg* 18: e25, 2012
4. Abate M, Schiavone C, Salini V, Andia I (2013) Occurrence of tendon pathologies in metabolic disorders. (*Oxford*) 52: 599-608
5. Huang L, Miao XD, Yang DS, Tao HM (2011) Bilateral Achilles tendon enlargement. *Orthopedics* 34: e960-964.
6. Spink MJ, Fotoohabadi MR, Menz HB (2010) Foot and ankle strength assessment using hand-held dynamometry: reliability and age-related differences. *Gerontology* 56: 525-532.
7. Mancuso G, La Regina G, Bagnoli M, Bittolo Bon G, Cazzolato G, et al. (1996) 'Normolipidemic' tendinous and tuberous xanthomatosis. *Dermatology* 193: 27-32.
8. Junyent M, Gilabert R, Zambón D, Núñez I, Vela M, et al. (2005) The use of Achilles tendon sonography to distinguish familial hypercholesterolemia from other genetic dyslipidemias. *Arterioscler Thromb Vasc Biol* 25: 2203-2208
9. Karaharju E, Paavolainen P, Holmström T, Nikkari T (1981) Xanthomas of the Achilles tendon. *Ann Chir Gynaecol* 70: 116-119.
10. Spink MJ, Fotoohabadi MR, Menz HB (2010) Foot and ankle strength assessment using hand-held dynamometry: reliability and age-related differences. *Gerontology* 56: 525-532.