

Calcaneal Fractures, Treatments and Problems

Faik Türkmen¹, Ismail Hakkı Korucu¹, Cem Sever², Gani Göncü², Burkay K Kaçira¹ and Serdar Toker³

¹Assistant Professor, Necmettin Erbakan University Meram, School of Medicine Department of Orthopaedics and Traumatology, Turkey

²Assistant Professor, Mevlana University School of Medicine Department of Orthopaedics and Traumatology, Turkey

³Associate Professor, Necmettin Erbakan University Meram School of Medicine Department of Orthopaedics and Traumatology, Turkey

*Corresponding author: Serdar Toker, Associate Professor, Necmettin Erbakan University, Meram School of Medicine, Department of Orthopaedics and Traumatology, Turkey, Tel: 00903322236230-6141; Fax: 00903322236522; E-Mail: tokerserdar@hotmail.com

Received date: March 03, 2014, Accepted date: March 28, 2014, Published date: April 5, 2014

Copyright: © 2013 Faik T, et al. This is an open-access article distributed under the terms of the Creative Commons Attribution License, which permits unrestricted use, distribution, and reproduction in any medium, provided the original author and source are credited.

Abstract

Calcaneal fractures are the most frequent tarsal fractures and represent 2% of all adult fractures. A high-energy trauma which causes axial loading is the most common cause of calcaneal fractures. The majority of these fractures are intra-articular. Particularly patients with displaced intra-articular calcaneal fractures must be evaluated for multiple traumatic injuries. The spine, contralateral lower extremity and the wrist fractures may accompany with calcaneal fractures.

The most common symptom of calcaneal fractures is pain. Swelling is frequently encountered. Erythema and fracture blisters are other findings. Conventional radiological images should include anteroposterior, axial, lateral and oblique views. The subtalar joint, the calcaneocuboid joint and posterior facet should be assessed in radiologic images.

Calcaneal fractures may involve extensive complications. Subtalar joint stiffness and arthritis, heel widening, peroneal impingement, implant-related problems and heel pad pain are the potential complications. The complex anatomy of the calcaneus should be well understood for assessing a calcaneal injury.

Evaluation of the radiological findings and classification of the fracture must be performed before determining the treatment method. There is a large number and variety of classification systems that have been described for calcaneal fractures.

There is a lack of consensus on treatment and operative technique in calcaneal fractures. The treatment of calcaneal fractures must be planned according to different factors such as type of trauma, classification of the fracture, skin condition and injury mechanism. No treatment, conservative treatment, open reduction and internal fixation, primary subtalar arthrodesis, delayed primary arthrodesis and calcanectomy are treatment options. Also minimally invasive techniques have developed over time. Restoring articular congruity and hindfoot morphology are the aims of calcaneal fracture treatment.

Most of recent studies show that open reduction and internal fixation has better outcome in selected patients. Good evaluation, preoperative planning and appropriate treatment bring out better results.

Keywords: Calcaneus; Calcaneal fracture; Calcaneal fracture treatment

Introduction

Calcaneal fractures are the most frequent tarsal fractures (approximately 60% of all tarsal fractures) and represent 2% of all adult fractures [1,2]. Calcaneal fractures occur mostly in motor vehicle accidents and fall from height [3]. The majority of these fractures are intra-articular [4]. Particularly patients with displaced intra-articular calcaneal fractures must be evaluated for multiple traumatic injuries which can occur with high-energy trauma. The spine, contralateral lower extremity and the wrist fractures may accompany with calcaneal fractures [5-7]

Calcaneal fractures present a significant challenge to orthopaedic surgeons and patients [8]. These fractures are debilitating and may

involve extensive complications [9]. Subtalar joint stiffness and arthritis, heel widening, peroneal impingement, implant-related problems and heel pad pain are the potential complications [4].

Satisfactory functional outcome depends on restoration of normal anatomy [10] Complex anatomy of the calcaneus should be well understood for restoration. The development of modern imaging like digital X-rays and computed tomography (CT) has facilitated the diagnosis. New developments of surgical techniques and osteosynthesis materials have improved the results of surgical procedure. Although improvement towards diagnostic and therapeutic interventions has been made, management of these fractures still remains controversial.

History

Norris, first described fractures of calcaneus in 1839, and Malgaigne mentioned calcaneal fractures in 1843 [8,11-13].

The first skeletal traction which applied for the reduction of a displaced calcaneal fracture was first described by Clark [13] and also minimally invasive treatment of calcaneal fractures using ligamentotaxis in 1855 was described by Clark. In 1882, Bell applied the first open reduction for an open calcaneal fracture [14]. Morestin performed the first open reduction and internal fixation of a calcaneal fracture in 1902 [15]. In 1929 Böhler described the closed reduction technique for calcaneal fractures [16,17]. In 1931 these fractures were classified according to injury mechanism and radiological view by Böhler [3]. Kocher recommended lateral approach for the calcaneus in 1948 [18]. Essex-Lopresti explained the injury mechanism of calcaneal fractures and described percutaneous reduction of tongue fractures of calcaneus in 1953 [15].

Most surgeons supported nonoperative treatment historically because of unpredictable surgical outcomes [19,20]. However open reduction and internal fixation has been considered the gold standard treatment method for displaced intra-articular calcaneal fractures since mid-1990s [21]. Furthermore open reduction and internal fixation is advocated in some of extra-articular fractures.

Anatomy

The complex anatomy of the calcaneus should be well understood for assessing a calcaneal injury. Calcaneus locates at the inferoposterior part of the foot. All axial loads from the body are supported by calcaneus [22]. Several joint axes of the calcaneus should be taken into account [23]. The calcaneus which is the largest tarsal bone has 6 different surfaces and 4 articular facets. The anterior, middle, and posterior facets form the subtalar joint by articulating with the talus superiorly. The most anterior facet forms the calcaneocuboid joint by articulating with the cuboid bone anteriorly [24].

The sustentaculum tali which is the site of insertion of the tibiocalcaneal component of deltoid ligament and the superomedial spring ligament is an eminence on the medial wall of the calcaneus. It supports the talar neck and the middle articular facet. At the same time it contributes the construction of the tarsal tunnel. Flexor hallucis longus (FHL) tendon passes under sustentaculum tali [22,25].

The lateral wall of the calcaneus is flat. Peroneal tendons pass from the sulcus which is on this side of the calcaneus [26].

This tarsal bone mostly consists of spongy bone which is surrounded by a thin cortex. The thalamic bone which underlies the posterior subtalar facet is a higher-density cortical bone. This part of cortical bone better supports axial loads along the angle of Gissane [27].

The calcaneal tuberosity which is the place of Achilles tendons insertion locates on the posterior and dorsal aspect of the calcaneus [28]. The calcaneus acts as the lever arm of the triceps surae through this insertion of the Achilles tendon [25].

Fracture Mechanism

A high-energy trauma which causes axial loading is the most common cause of calcaneal fractures. An increased axial force drives the lateral process of the talus into the calcaneus. Thus an oblique

primary fracture line occurs along the Gissane angle. Two major fragments are generally identified: an anteromedial and a posterolateral fragment. Sustentaculum tali, anterior and medial facets, and medial part of the posterior facet are in the anteromedial fragment. Calcaneal tuberosity, lateral wall, and lateral part of the posterior facet remain in the posterolateral fragment [23]. Anteromedial fragment is not significantly displaced due to its strong talocalcaneal interosseous ligament and deltoid ligament, however the posterolateral fragment is displaced laterally [26,28,29]. Greater forces can generate additional or different fracture lines [30,31]. (Figure 1)

Diagnosis

Clinical assessment

Calcaneal fractures generally occur as a result of high-energy trauma [32]. When dealing with a calcaneal fracture the possibility of concomitant injuries such as ankle fractures, contralateral calcaneal fractures, vertebral fractures, wrist fractures, femoral fractures, and other tarsal bone fractures should be evaluated. [33].

The most common symptom of calcaneal fractures is pain. Swelling is frequently encountered. Erythema and fracture blisters are other findings [34,35]. Edema and widening of the heel are among the findings need to be considered [36]. Ecchymosis and inability to bear weight also may indicate a calcaneal fracture [4].

Radiologic assessment

Conventional radiological images should include anteroposterior (AP), axial, lateral and oblique views. The subtalar joint, the calcaneocuboid joint and posterior facet should be assessed in radiologic images.

Böhler's and Gissane's angles are the two important landmarks in assessing radiological images of calcaneal fractures. Calcaneal height and joint depression are represented by Böhler's angle. This angle's normal value is 25°-40°. Displacements of the facets are assessed by Gissane's angle. Normal value of Gissane's angle is 120°-145° [23] (Figure 2).

Conventional radiographic imaging has been the basis of various calcaneal fracture classifications. However classifications derived from radiographic findings have become obsolete because of limited visualisation of the calcaneal anatomy at conventional radiography [22].

Computed tomography (CT) provides precise diagnosis and gives more detailed information about the fracture pattern. Moreover much better images can be obtained by three-dimensional reconstruction. Therefore CT-based classifications for calcaneal fractures are more useful in guiding treatment.

Fracture classification

Evaluation of the radiological findings and classification of the fracture must be performed before determining the treatment method. There is a large number and variety of classification systems that have been described for calcaneal fractures. Sanders and Crosby-Fitzgibbons are the two most prevalent [37].

The oldest classification for calcaneal fractures which based on conventional radiographic findings was performed by Essex-Lopresti

[38]. According to this classification, calcaneal fractures are divided into tongue-type and joint-depression type fractures.

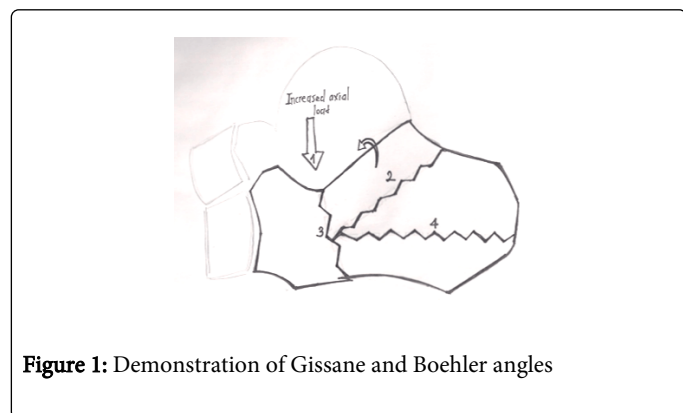


Figure 1: Demonstration of Gissane and Bohler angles

One of the two most prevalent classifications in evaluation of calcaneal fractures was described by Sanders in 1993. According to this CT based classification amount and location of fracture lines on coronal view of the posterior facet determine the type of the fracture [38]. Non-displaced fractures are classified as Type 1. Type 2, 3, and 4 are displaced fractures. Type 2 fractures are two-part intra-articular fractures and are divided into three subgroups on the basis of fracture line localisation. Fracture line is in the lateral in Type 2A fractures, in the central in Type 2B fractures, in the medial in Type 2C fractures. Type 3 fractures are three-part intra-articular fractures. Comminuted fractures are classified as Type 4.

Crosby-Fitzgibbons is another prevalent classification. Amount of displacement of the posterior facet determines the type of fracture in this CT based classification system [39] (Figures 1 and 2).

There is still some controversy about classification systems. According to Schepers et al. [37] none of the classification systems satisfy all of the criteria required for an ideal classification system.

Although a large number of classification systems have been developed during the years calcaneal fractures can be classified basically as intra- or extra-articular [23].

Intra-articular fractures account for 70% and extra-articular fractures account for 30% of all calcaneal fractures in adults [4].

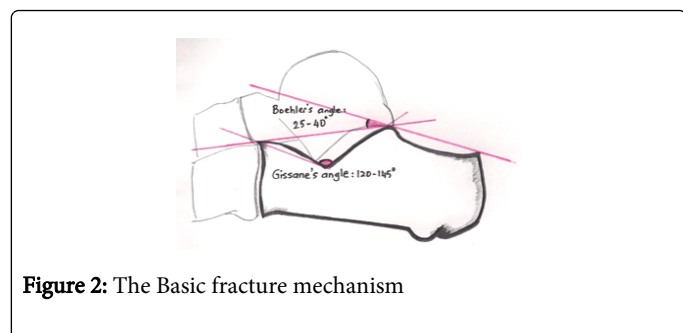


Figure 2: The Basic fracture mechanism

Treatment

There is a lack of consensus on treatment and operative technique in calcaneal fractures. No treatment, conservative treatment, open reduction and internal fixation, primary subtalar arthrodesis, delayed primary arthrodesis and calcanectomy are treatment options in the literature [40]. Also minimally invasive techniques have developed

over the time. Restoring articular congruity and hindfoot morphology are the aims of calcaneal fracture treatment [41] (Table 1)

Non-operative treatment

Conservative treatment was preferred over surgical treatment until modern imaging methods, osteosynthesis materials, improvements of less invasive surgical techniques and the presence of effective and adequate antibiotic treatments have been developed. However current treatment protocol of calcaneal fractures has shifted in favour of ORIF [24]. Age, health, gender, status of the soft tissue, injury mechanism, comminution of the bone and Bohler angle affect the choice of treatment [42]. Open reduction and internal fixation is preferable to conservative treatment for displaced calcaneal fractures in a selected group of healthy patients [43]. In general conservative treatment is applied for non-displaced fractures and surgical treatment is applied for displaced intra-articular fractures [18].

Wound concerns, medical co-morbidities and non-compliance factors may affect the decision in favour of conservative treatment [41]. Bandaging and elevation of the foot for the treatment of calcaneal fractures have been applied for a long time [44]. Elevation, splinting and non-weight bearing for up to 12 weeks are parts of conservative treatment [25].

Controversy related to open or closed management of intra-articular calcaneal fractures still persists [4]. Jarvholm et al. [45] concluded that results of operative and non-operative treatment are almost equal and they argued that primary surgery is rarely indicated. There were no significant differences between the two groups with regard to heel pain, subtalar motion, and return to work in a matched cohort study [46]. Equal outcomes between operative and non-operative treatment were obtained in a randomized controlled trial which involves 309 patients [43]. On the contrary Leung et al. [47] found significantly better results in operated group compared with non-operated group. Allmacher et al. [48] showed poor functional and clinical outcomes of non-operative treatment in their prospective cohort series and there were subtalar arthritis suspicious findings on CT images of patients. According to another study secondary arthrodesis is indicated after initial conservative treatment in approximately 21% to 30% of cases versus 2% to 5% of cases after operative treatment [49].

Operative treatment

ORIF is routinely performed especially for displaced intra-articular calcaneal fractures currently [50]. However outcomes of previous randomised controlled trials in this subject have varied. Jiang et al [51] showed that surgery can effectively restore the anatomical structures of the calcaneus and lead to better functional recovery for displaced intra-articular calcaneal fractures in their meta-analysis. According to prospective, randomised, controlled multicenter trial outcomes of operative and non-operative treatment of displaced intra-articular calcaneal fractures are comparable at one year follow up. However the same study showed that operative treatment have some benefits at eight to twelve years [52].

There are various approaches for calcaneal fracture fixation in the literature. Surgical approach is one of the factors affecting the outcomes of surgical treatment. Medial approach which allows direct reduction of the primary fracture line is associated with poor outcomes and high complication rates [40].

Accurate reduction of lateral and medial fragments can be applied through combined lateral and medial approaches. Skin blood supply problems may develop in this approach [23].

In the short lateral approach peroneal tendons and sural nerve are at risk of injury [40].

Conservative Treatment	Fracture	Operative Treatment	Fracture
Doing Nothing	Non-displaced	Minimal Invasive Essex-Lopresti Percutaneous Wire Fixation Percutaneous Screw Fixation	Tongue Type Minimally Displaced
Orthesis	Non-displaced. Minimally Displaced	External Fixation	Open Comminuted
Plaster of Paris	Non-displaced . Minimally Displaced	ORIF Plate Fixation	Displaced Intra-Extra Articular
		Primary Arthrodesis	Comminuted Fractures of Posterior Subtalar Joint
		Secondary Arthrodesis	Comminuted Fractures of Posterior Subtalar Joint

Table 1: Treatment modalities according to the type of fracture.

The most commonly used approach is the extensile lateral approach which was originally described by Letournel [53]. Better visualization of the calcaneus and to allow the anatomical reduction is advantages of the approach [54]. This approach has been extended to include a full-thickness flap that protects peroneal tendons, sural nerve, and the vascularity of the flap [25]. Kirschner wires are placed in the fibula, talar neck, and cuboid bone for retraction of the subperiosteal flap. A low-profile lateral neutralization plate is placed for fixation after completion of reduction. The full-thickness flap is closed over a deep drain [8].

Sinus tarsi approach is one of several open surgical techniques. Better visualization of the subtalar joint is the advantage of this technique. Surgical manipulations especially for the posterior subtalar joint may become easier through this approach.

Primary subtalar arthrodesis is one of the surgical techniques that can be applied for comminuted calcaneal fractures. This technique may be preferred especially for four or more-part fractures of the posterior facet of the subtalar joint.

Despite ORIF is the best method for achieving anatomic reduction and calcaneal restoration soft tissue problems should be taken into account [23].

Minimally invasive and percutaneous methods developed for reducing the wound complication rate. Clark [13] described minimally invasive technique using ligamentotaxis for calcaneal fractures in 1855.

Percutaneous reduction of fragments by Kirschner-wires, application of external fixators, percutaneous screw fixation after percutaneous distraction of displaced fragments is various minimally invasive techniques [44]. Difficulty in reducing the articular surface is the main problem of percutaneous techniques [54]. For this reason ORIF gained more popularity compared with minimal invasive techniques [44].

General Treatment Guidelines can be Summarized as Follows:

Sanders type 1 fractures are treated conservatively [21,55]. Sanders type 2 and 3 fractures are treated surgically [21,55].

There is some debate about the treatment method of Sanders type 4 fractures. These types of fractures can be treated surgically or conservatively in deference to the surgeon's experience.

Despite these general treatment principles a case-by-case basis treatment strategy should be performed because various factors affect the development of complications in calcaneal fractures [56].

Challenges and complications

Soft tissue problems may accompany to calcaneal fractures due to high-energy trauma. Particularly severe edema may cause corruption of the soft tissue, fracture blisters and compartment syndrome [32]. These factors negatively affect or may delay the treatment.

Soft tissue complications affect the success of the surgery. Therefore timing of the surgery is important for overcoming these problems. Operation should be delayed until declining of the soft tissue edema and resolving of fracture blisters for performing a safe surgery. There is a lack of consensus in the literature about sufficiently delaying surgery after the fracture in order to allow the soft tissue swelling to subside [4]. However surgery should not be delayed more than 2 weeks, because subsequent fibrosis between fragments may complicate surgery [57].

Infection and skin necrosis may delay the treatment. Entrapment of tendons between fracture fragments may cause tendon injuries [22]. Nerve entrapment and nerve injuries may associated with calcaneal fractures. Post-traumatic arthritis of the subtalar joint, instability and subluxation of peroneal tendons, heel pad syndrome and exostoses are other complications [18].

Conclusion

Calcaneal fractures should be evaluated carefully. The treatment of calcaneal fractures must be planned according to different factors such as type of trauma, classification of the fracture, skin condition and injury mechanism. Most of recent study shows that open reduction and internal fixation has better outcome in selected patients. In conclusion; Good evaluation, preoperative planning and appropriate treatment bring out better results.

References

1. Molloy AP, Lipscombe SJ (2011) Hindfoot arthrodesis for management of bone loss following calcaneus fractures and nonunions. *Foot Ankle Clin* 16: 165-179.
2. Hollawell S (2008) Wound closure technique for lateral extensile approach to intra-articular calcaneal fractures. *J Am Podiatr Med Assoc* 98: 422-425.
3. Kelikian AS, Jimenez ML (1999) Fractures of calcaneus in operative treatment of the foot and ankle, Kelikian AS (eds), Appleton & Lange, Stamford, Connecticut.
4. Dhillon MS, Bali K, Prabhakar S (2011) Controversies in calcaneus fracture management: a systematic review of the literature. *Musculoskeletal Surg* 95: 171-181.
5. Cotton FJ, Henderson FF (1916) Results of fracture of the os calcis. *The Journal of Bone & Joint Surgery*.
6. Zwipp H (1990) [Reconstructive surgery of malunited joint fractures of the foot]. *Orthopade* 19: 409-415.
7. Myerson M, Quill GE Jr (1993) Late complications of fractures of the calcaneus. *J Bone Joint Surg Am* 75: 331-341.
8. Swanson SA, Clare MP, Sanders RW (2008) Management of intra-articular fractures of the calcaneus. *Foot Ankle Clin* 13: 659-678.
9. Zwipp H, Tscherne H, Thermann H, Weber T (1993) Osteosynthesis of displaced intraarticular fractures of the calcaneus. Results in 123 cases. *Clin Orthop Relat Res* : 76-86.
10. Mostafa MF, El-Adl G, Hassanin EY, Abdellatif MS (2010) Surgical treatment of displaced intra-articular calcaneal fracture using a single small lateral approach. *Strategies Trauma Limb Reconstr* 5: 87-95.
11. Sanders RW, Clare MP (2007) Fractures of calcaneus in the surgery of the foot and ankle, Coughlin MJ, Mann RA, Saltzman CL (eds), Mosby Elsevier 8th ed.
12. Clare MP, Sanders RW (2011) [Calcaneus fractures]. *Unfallchirurg* 114: 869-876.
13. Clark LG (1855) Fracture of the os calcis. *Lancet* 65 (1651): 403-404
14. Goff C (1938) Fresh fracture of the os calcis. *Arch surg* 36: 744-765
15. Essex-Lopresti P (1952) The mechanism, reduction technique, and results in fractures of the os calcis. *Br J Surg* 39: 395-419.
16. Bohler L (1931) Diagnosis, pathology, and treatment of fractures of the os calcis - *The Journal of Bone & Joint Surgery*
17. Bohler L (1957) Die Technik der Knochen bruchbehandlung Maudrich, Wien
18. , , , (2012) Calcaneal fractures - the orthopaedic challenge. *Acta Chir Iugosl* 59: 33-39.
19. Vestad E (1968) Fractures of the calcaneum. Open reduction and bone grafting. *Acta Chir Scand* 134: 617-625.
20. Lindsay WR, Dewar FP (1958) Fractures of the os calcis. *Am J Surg* 95: 555-576.
21. Sanders R (2000) Displaced intra-articular fractures of the calcaneus. *J Bone Joint Surg Am* 82: 225-250.
22. Badillo K, Pacheco JA, Padua SO, Gomez AA, Colon E, et al. (2011) Multidetector CT evaluation of calcaneal fractures. *Radiographics* 31: 81-92.
23. Guerado E, Bertrand ML, Cano JR (2012) Management of calcaneal fractures: what have we learnt over the years? *Injury* 43: 1640-1650.
24. Palmersheim K, Hines B, Olsen BL (2012) Calcaneal fractures: update on current treatments. *Clin Podiatr Med Surg* 29: 205-220, vii.
25. Epstein N, Chandran S, Chou L (2012) Current concepts review: intra-articular fractures of the calcaneus. *Foot Ankle Int* 33: 79-86.
26. Juliano PJ, Myerson MS (2000) Fractures of the hindfoot - Foot and ankle disorders, WB Saunders, Philadelphia, USA
27. Soeur R, Remy R (1975) Fractures of the calcaneus with displacement of the thalamic portion. *J Bone Joint Surg Br* 57: 413-421.
28. Benirschke SK, Sangeorzan BJ (1993) Extensive intraarticular fractures of the foot. Surgical management of calcaneal fractures. *Clin Orthop Relat Res* : 128-134.
29. Burdeaux BD (1983) Reduction of calcaneal fractures by the McReynolds medial approach technique and its experimental basis. *Clin Orthop Relat Res* : 87-103.
30. Seipel RC, Pintar FA, Yoganandan N, Boynton MD (2001) Biomechanics of calcaneal fractures: a model for the motor vehicle. *Clin Orthop Relat Res* : 218-224.
31. Essex-Lopresti P (1993) The mechanism, reduction technique, and results in fractures of the os calcis, 1951-52. *Clin Orthop Relat Res* : 3-16.
32. Mehta S, Mirza AJ, Dunbar RP, Barei DP, Benirschke SK (2010) A staged treatment plan for the management of Type II and Type IIIA open calcaneus fractures. *J Orthop Trauma* 24: 142-147.
33. Daftary A, Haims AH, Baumgaertner MR (2005) Fractures of the calcaneus: a review with emphasis on CT. *Radiographics* 25: 1215-1226.
34. Berry GK, Stevens DG, Kreder HJ, McKee M, Schemitsch E, et al. (2004) Open fractures of the calcaneus: a review of treatment and outcome. *J Orthop Trauma* 18: 202-206.
35. Heier KA, Infante AF, Walling AK, Sanders RW (2003) Open fractures of the calcaneus: soft-tissue injury determines outcome. *J Bone Joint Surg Am* 85-85A: 2276-82.
36. Nickleburg S, Dixon T, Probe R (2009) Calcaneus fractures: eMedicine orthopaedic surgery.
37. Schepers T, van Lieshout EM, Ginai AZ, Mulder PG, Heetveld MJ, et al. (2009) Calcaneal fracture classification: a comparative study. *J Foot Ankle Surg* 48: 156-162.
38. Sanders R, Fortin P, DiPasquale T, Walling A (1993) Operative treatment in 120 displaced intraarticular calcaneal fractures. Results using a prognostic computed tomography scan classification. *Clin Orthop Relat Res*: 87-95.
39. Crosby LA, Fitzgibbons T (1993) Intraarticular calcaneal fractures. Results of closed treatment. *Clin Orthop Relat Res* : 47-54.
40. Jain S, Jain AK, Kumar I (2013) Outcome of open reduction and internal fixation of intraarticular calcaneal fracture fixed with locking calcaneal plate. *Chin J Traumatol* 16: 355-360.
41. Arastu M, Sheehan B, Buckley R (2014) Minimally invasive reduction and fixation of displaced calcaneal fractures: surgical technique and radiographic analysis. *Int Orthop* 38: 539-545.
42. Dooley P, Buckley R, Tough S, McCormack B, Pate G, et al. (2004) Bilateral calcaneal fractures: operative versus nonoperative treatment. *Foot Ankle Int* 25: 47-52.
43. Buckley R, Tough S, McCormack R, Pate G, Leighton R, et al. (2002) Operative compared with non-operative treatment of displaced intra-articular calcaneal fractures: a prospective, randomized, controlled multicenter trial. *J Bone Joint Surg Am.*: 1733-1744.
44. Schepers T, Patka P (2009) Treatment of displaced intra-articular calcaneal fractures by ligamentotaxis: current concepts' review. *Arch Orthop Trauma Surg* 129: 1677-1683.
45. Järholm U, Körner L, Thorén O, Wiklund LM (1984) Fractures of the calcaneus. A comparison of open and closed treatment. *Acta Orthop Scand* 55: 652-656.
46. Buckley RE, Meek RN (1992) Comparison of open versus closed reduction of intraarticular calcaneal fractures: a matched cohort in workmen. *J Orthop Trauma* 6: 216-222.

47. Leung KS, Yuen KM, Chan WS (1993) Operative treatment of displaced intra-articular fractures of the calcaneum. Medium-term results. *J Bone Joint Surg Br* 75: 196-201.
48. Allmacher DH, Galles KS, Marsh JL (2006) Intra-articular calcaneal fractures treated nonoperatively and followed sequentially for 2 decades. *J Orthop Trauma* 20: 464-469.
49. Schepers T, Kieboom BC, Bessems GH, Vogels LM, van Lieshout EM, et al. (2010) Subtalar versus triple arthrodesis after intra-articular calcaneal fractures. *Strategies Trauma Limb Reconstr* 5: 97-103.
50. Basile A (2012) Subjective results after surgical treatment for displaced intra-articular calcaneal fractures. *J Foot Ankle Surg* 51: 182-186.
51. Jiang N, Lin QR, Diao XC, Wu L, Yu B (2012) Surgical versus nonsurgical treatment of displaced intra-articular calcaneal fracture: a meta-analysis of current evidence base. *Int Orthop* 36: 1615-1622.
52. Agren PH, Wretenberg P, Sayed-Noor AS (2013) Operative versus nonoperative treatment of displaced intra-articular calcaneal fractures: a prospective, randomized, controlled multicenter trial. *J Bone Joint Surg Am* 95: 1351-1357.
53. Letournel E (1993) Open treatment of acute calcaneal fractures. *Clin Orthop Relat Res* : 60-67.
54. Abdelazeem A, Khedr A, Abousayed M, Seifeldin A, Khaled S (2014) Management of displaced intra-articular calcaneal fractures using the limited open sinus tarsi approach and fixation by screws only technique. *Int Orthop* 38: 601-606.
55. Kitaoka HB, Schaap EJ, Chao EY, An KN (1994) Displaced intra-articular fractures of the calcaneus treated non-operatively. Clinical results and analysis of motion and ground-reaction and temporal forces. *J Bone Joint Surg Am* 76: 1531-1540.
56. Howard JL, Buckley R, McCormack R, Pate G, Leighton R (2003) Complications following management of displaced intra-articular calcaneal fractures: a prospective randomized trial comparing open reduction internal fixation with non-operative management. *J Orthop Trauma*: 241-249.
57. Tennent TD, Calder PR, Salisbury RD, Allen PW, Eastwood DM (2001) The operative management of displaced intra-articular fractures of the calcaneum: a two-centre study using a defined protocol. *Injury* 32: 491-496.