

## Non-Surgical Management of Huge Cystic Lesion with Double Antibiotic Paste and Water Based Calcium Hydroxide Medicament: A Case Report

Eldho Jijy Varghese\*

Department of Conservative Dentistry and Endodontics, Royal Dental College, Palakkad, Kerala, 679536, India

### Abstract

For many years, calcium hydroxide has been utilised extensively as an intracanal medication in endodontics. It is utilised in a variety of clinical settings, including to controlling root resorption, promote apexification, repairing perforation, improving healing of periapical lesions and reducing exudation in teeth with persistent periapical inflammation. This case report describes the use of  $\text{Ca}(\text{OH})_2$  and double antibiotic paste as an intracanal medication to treat periradicular cystic lesion in upper maxillary central incisor of a female patient.

**Keywords:** Apexification; Perforation; Intracanal; Maxillary central; Periapical inflammation

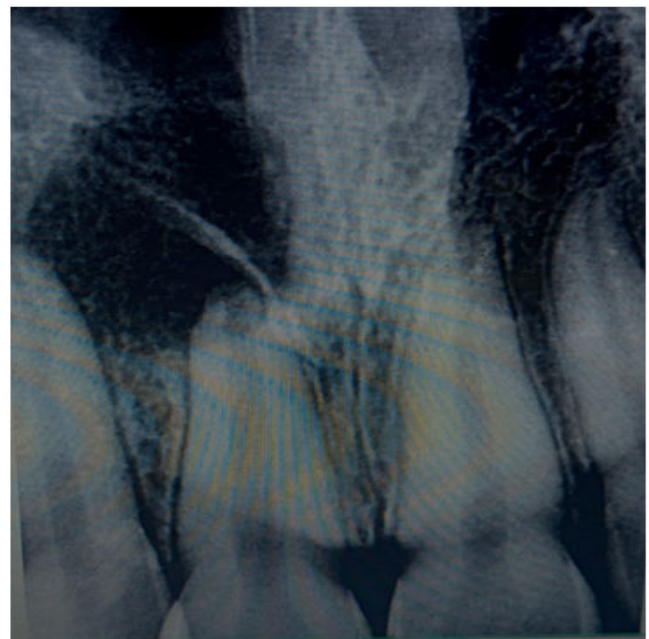### Introduction

The fundamental objective of endodontic therapy is to get rid of the bacteria in the root canal system, or at the very least, significantly reduce their number. It is common knowledge that chemo-mechanical instrumentation cannot fully sanitise the root canal system [1]. Between appointments, the microorganisms that have survived root canal instrumentation multiply. In order to get rid of any potential persistent germs between consultations, using intracanal medication with antimicrobial activity has been advised, especially in cases of pulp necrosis with periradicular bone loss [2]. With its antibacterial properties, calcium hydroxide has been utilised extensively in endodontics as an intracanal dressing between appointments.

### Case Presentation

A 17 year old female patient came to the clinic with complaint of swelling in relation to upper front tooth region. On oral examination, it was found that 11 was discoloured. On radiographic examination, a large radiolucency in the periapical region in relation to 11 suggestive of periapical cyst was seen (Figure 1). Endodontic therapy was decided in 11. Access opening was done. It was at this time that the decision was taken to compare the response of calcium hydroxide and antibiotic paste in this patient. Following the working length estimation in 11, a thorough chemo-mechanical preparation was performed (Figure 2). The root canals were irrigated with combination of 2 percent chlorhexidine and sterile saline solution. The canals were dried with sterile paper points. For the first dental visit, a combination of metronidazole 400 mg tablet and Ciprofloxacin 500 mg tablet was powdered and mixed with saline to make into a slurry paste and was packed within the root canal space using gutta percha points. The access cavity was closed with sterile cotton plug and cavit G. The patient was recalled after 7 days. The swelling was reduced and radiographic healing was appreciated in the second dental visit. For the second dental visit, the antibiotic paste was flushed out and thorough irrigation was done using 2 percent chlorhexidine and sterile saline. Calcium hydroxide paste-Neocal was injected into the canal space. The access cavity was sealed with intermediary restorative material cavit G and a radiograph was taken (Figure 3). On the third dental visit, the patient was completely asymptomatic and satisfactory radiographic healing was appreciated with complete relief from swelling. Obturation was done using bio-ceramic hydraulic condensation technique (Figure 4).

A permanent core restoration was done using direct composite and the patient was recalled after two weeks for indirect permanent restoration.



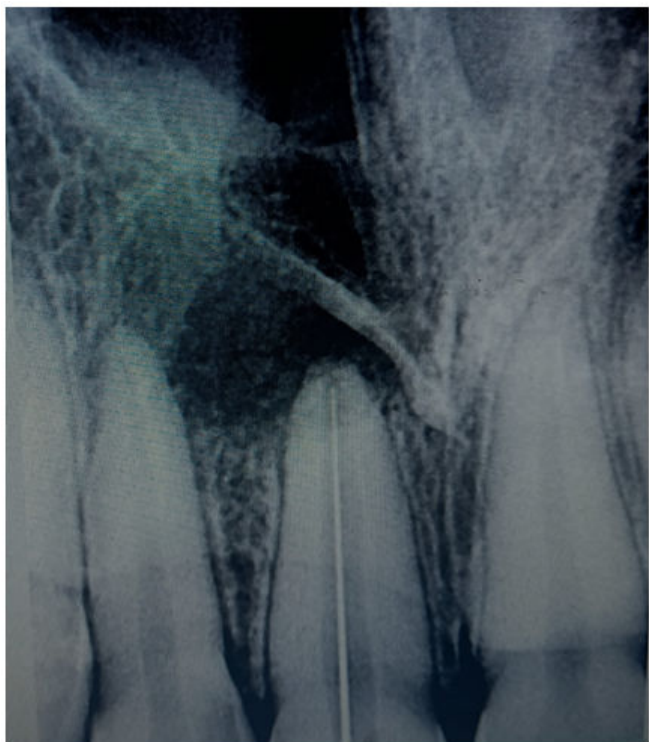**Figure 1:** Periapical cyst of canine (11) in the periapical region.

\*Corresponding author: Eldho Jijy Varghese, Department of Conservative Dentistry and Endodontics, Royal Dental College, Palakkad, Kerala, 679536, India; E-mail: ev1920@gmail.com

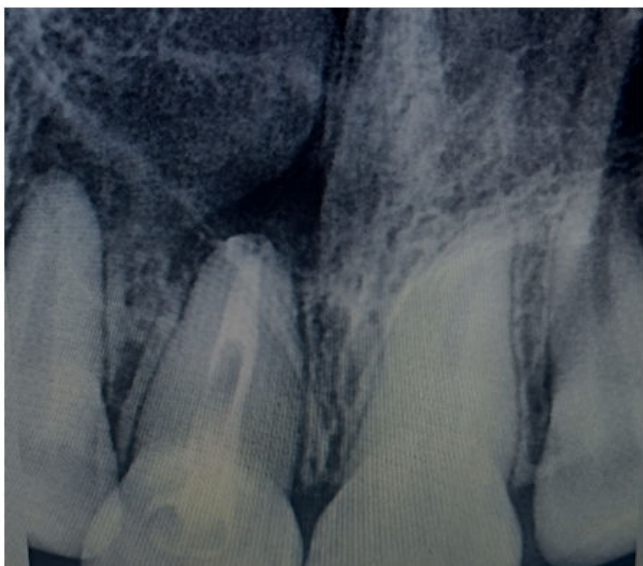**Received:** 13-June-2023, Manuscript No. DID-23-102423; **Editor assigned:** 16-June-2023, PreQC No. DID-23-102423 (PQ); **Reviewed:** 30-June-2023, QC No. DID-23-102423; **Revised:** 14-August-2023, Manuscript No. DID-23-102423 (R); **Published:** 21-August-2023, DOI: 10.4172/DID.1000180

**Citation:** Varghese EJ (2023) Non Surgical Management of Huge Cystic Lesion with Double Antibiotic Paste and Water Based Calcium Hydroxide Medicament: A Case Report. Dent Implants Dentures 6: 180.

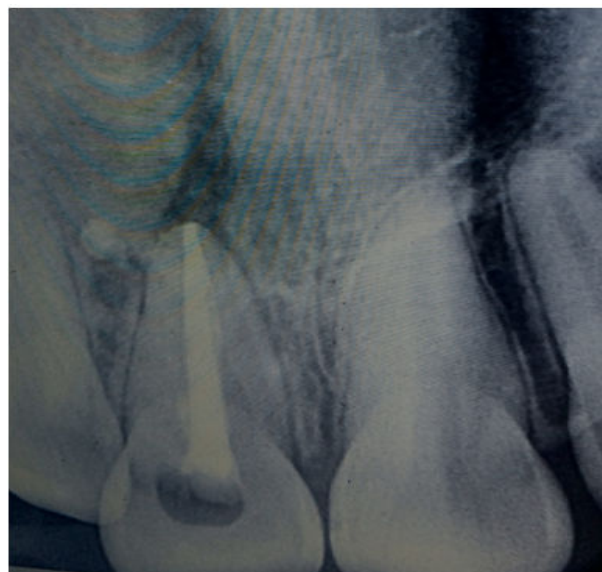
**Copyright:** © 2023 Varghese EJ. This is an open-access article distributed under the terms of the Creative Commons Attribution License, which permits unrestricted use, distribution and reproduction in any medium, provided the original author and source are credited.



**Figure 2:** Estimation of canine thorough chemo-mechanical preparation.



**Figure 3:** Intermediary restorative material cavit G and a radiograph.



**Figure 4:** Bio-ceramic hydraulic condensation technique.

## Results and Discussion

Apical periodontitis is brought on by microorganisms and eliminating them from the root canal space during root canal therapy produces predictable healing of apical pathosis. Unfortunately, it is unlikely that microorganisms will be completely eliminated by instrumentation alone. Additionally, pulp tissue remains may hinder the encapsulation of microorganisms, as well as negatively affect the root filling's physical characteristics and ability to conform to the canal walls. In order to eliminate germs, their byproducts, and leftover tissue as well as to clear the smear layer and other debris from the canal system, some type of irrigation and disinfection is therefore required. Irrigants, canal rinses, and interappointment medications can all be considered as types of chemical (therapeutic) root canal treatments [3].

Since it was first used in dentistry (Hermann), calcium hydroxide has been suggested to enhance healing in a variety of therapeutic settings [4-6]. Calcium hydroxide's antimicrobial activity is influenced by how quickly it breaks down into calcium and hydroxyl ions in a high pH environment. This inhibits enzymatic activities that are crucial for microbial life, such as metabolism, growth, and cellular division. However, the overall mechanism of action of calcium hydroxide is not fully understood. By combining its antibacterial action with its capacity to encourage the creation of hard tissue and periodontal healing,  $\text{Ca}(\text{OH})_2$  is frequently employed to effect periapical healing.

When  $\text{Ca}(\text{OH})_2$  and saline solution are combined,  $\text{Ca}^{++}$  and  $\text{OH}^-$  are quickly released when the paste comes into contact with the tissue and tissue fluids. Macrophages quickly solubilize and reabsorb the mixture, and the root canal quickly empties.

## Conclusion

Due to its indication for a number of clinical problems, calcium hydroxide has significant utility in endodontics. Two distinct calcium hydroxide formulations were used in the current instance to treat periapical lesions. Calcium hydroxide showed to be a successful

intracanal medication and caused the periapical lesions to successfully resolve regardless of the vehicle employed.

## References

1. de Souza CA, Teles RP, Souto R, Chaves MA, Colombo AP (2005) Endodontic therapy associated with calcium hydroxide as an intracanal dressing: Microbiologic evaluation by the checkerboard DNA-DNA hybridization technique. J Endod 31: 79-83.
2. Trope M (20016) Treatment of immature teeth with non-vital pulps and apical periodontitis. Endodontic topics 14: 51-59.
3. Milosevic A (1991) Calcium hydroxide in restorative dentistry. J Dent 19: 3-13.
4. Simcock RM, Hicks ML (2006) Delivery of calcium hydroxide: Comparison of four filling techniques. J Endod 32: 680-682.
5. Estrela C, Bammann LL, Pimenta FC, Pecora JD (2001) Control of microorganisms *in vitro* by calcium hydroxide pastes. Int Endod J 34: 341-345.
6. Estrela C, Estrela CR, Pecora JD (2003) A study of the time necessary for calcium hydroxide to eliminate microorganisms in infected canals. J Appl Oral Sci 11: 133-137.