

Changes in the Electrocardiogram of Cancer Patients Receiving 5-Flurouracil Chemotherapy

Sidra Gupta*

Department of Health Science and Radiology, University of Botswana, Botswana

Image Article

At the national Cancer Institute-University of Gezira, a prospective cross-sectional and analytical hospital-based study was carried out to evaluate the electrocardiogram changes of cancer patients who received 5-fluorouracil chemotherapy from September to December 2018. This study included 100 patients who had been diagnosed with cancer and were receiving 5FU-based chemotherapy. The patient's most personal information and other medically relevant information were included in a structured questionnaire that was developed, and the questionnaire's notes were reviewed.

A cardiologist then interpreted the 12-lead ECGs that were recorded before and 24 hours after the beginning of the chemotherapy treatment for 5FU. 29% of patients' ECG records changed after 5 FU, according

to the study. The pattern of ECG changes was left axis deviation in 4 percent of the patents. 5 percent have right bundle branch block, 3 percent have an inverted T wave, 5 percent have a corrected QT interval between 0.471 and 0.50 seconds, 3 percent have a QT interval greater than 0.50 seconds, 2 percent have left ventricular hypertrophy, and 7 percent have a low voltage compared to normal ECG records prior to taking 5FU. However, neither the rhythm nor the ST segment is altered in the study [1,2].

Additionally, the study discovered that there was no correlation between the drug's mode of administration and ECG changes. After the treatment, there was a correlation between the number of cycles and heart rate, and there was a significant correlation between the number of cycles and T wave inversion. The study concludes that electrocardiogram changes caused by 5-fluorouracil chemotherapy are a sign of cardio toxicity (Figure 1).

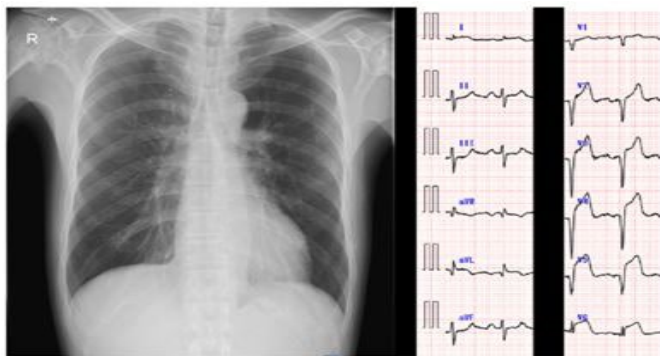


Figure 1: Result of chest x-ray and electrocardiogram.

Acknowledgement

None

Conflict of Interest

None

References

1. Ensley JF, Patel B, Kloner R, Kish JA, Wynne J, et al. (1989) The clinical syndrome of 5-fluorouracil cardiotoxicity. Invest New Drugs 7: 101-109.
2. Millward MJ, Ganju V, Buck M (1988) Cardiac arrest- -a manifestation of 5-fluorouracil cardiotoxicity. Aust N Z J Med 18: 693-695.

*Corresponding author: Sidra Gupta, Department of Health Science and Radiology, University of Botswana, Botswana, E-mail: gupta_s@yahoo.com

Received: 03-Dec-2022, Manuscript No. roa-22-83867; Editor assigned: 05-Dec-2022, PreQC No. roa-22-83867 (PQ); Reviewed: 19-Dec-2022, QC No. roa-22-83867; Revised: 23-Dec-2022, Manuscript No. roa-22-83867 (R); Published: 30-Dec-2022, DOI: 10.4172/2167-7964.1000417

Citation: Gupta S (2022) Changes in the Electrocardiogram of Cancer Patients Receiving 5-Flurouracil Chemotherapy. OMICS J Radiol 11: 417.

Copyright: © 2022 Gupta S. This is an open-access article distributed under the terms of the Creative Commons Attribution License, which permits unrestricted use, distribution, and reproduction in any medium, provided the original author and source are credited.