

Intramuscular Venous Angioma of the knee, a case of an 8 Years Old Girl

Chaimae Iahlou*, Boularab Jihad, Meryem Zhim, Nazik Allali, Latifa Chat and Siham El Haddad

Department Radiology, Children hospital of Rabat (HER), Mohammed V University, Rabat, Morocco

Image Article

Haemangioma account for 7-10% of all soft-tissue tumors it mostly affects women and the younger age groups before the age of 30, and 30% occurring in the lower limbs, Swelling and pain in muscle are the most prevalent symptoms with or without a history of trauma. A non-compressible mass is frequently present, and some patients show blue discoloration of the underlying skin and superficial dilated veins.

MRI is the method of choice of its diagnosis, It shows a well-defined lobulated mass of soft tissues, which is iso or hyper intense in T1, hyper signal in T2 FS, with significant enhancement after gadolinium injection, dilated tubular vascular channels showing flow voids intermixed with fatty tissue may be seen as well as calcifications and phleboliths [1, 2] (Figure 1).

Specific characteristics that aid in the differentiating of benign from malignant tumors include:

- serpiginous and septate appearance
- central low-intensity dots
- marked contrast enhancement

References

1. <https://radiopaedia.org/articles/intramuscular-angioma>
2. Kiran KR, Suresh Babu TV, Babu SS, Deepti K (2012) Skeletal Muscle Haemangioma: A Cause for Chronic Pain about the Knee: A Case Report. Case Rep Orthop 2012: 452651.

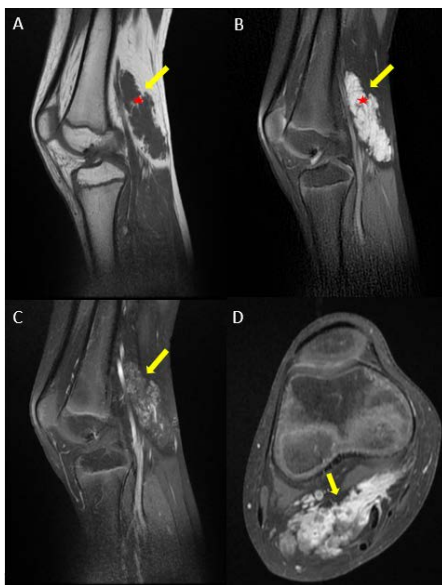


Figure 1: MRI of the right knee of an 8 years old girl, with sagittal view in T1 weighted sequence (A), T2 FS weighted sequence (B), T1 sagittal and axial enhanced sequences in portal phase (C) (D), showing a well-defined, extra-articular mass of the knee developed in the gastrocnemius muscle, isointense in the T1 sequence, hyperintense in T2 FS, with delayed enhancement after Gadolinium injection and fatty linear spots (red star), leading to diagnosis of intra muscular venous angioma.

***Corresponding author:** Chaimae Iahlou, Department Radiology, Children hospital of Rabat (HER), Mohammed V University, Rabat, Morocco, E-mail: chaimaelahlou27@gmail.com

Received: 16-Mar-2022, Manuscript No. roa-22-57475; **Editor assigned:** 18-Mar-2022, PreQC No. roa-22-57475 (PQ); **Reviewed:** 25-Mar-2022, QC No. roa-22-57475; **Revised:** 30-Mar-2022, Manuscript No. roa-22-57475 (R); **Published:** 06-April-2022, DOI: 10.4172/2167-7964.1000373

Citation: Iahlou C, Jihad B, Zhim M, Allali N, Chat L, et al. (2022) Intramuscular Venous Angioma of the knee, a case of an 8 Years Old Girl. OMICS J Radiol 11: 373.

Copyright: © 2022 Iahlou C, et al. This is an open-access article distributed under the terms of the Creative Commons Attribution License, which permits unrestricted use, distribution, and reproduction in any medium, provided the original author and source are credited.