



## A Rare Etiology of Colonic Mass in a Patient that Underwent Liver Transplantation: Malakoplakia

Sobotka LA<sup>1</sup>, Wellner M<sup>1</sup>, Proca D<sup>2</sup>, Cirocco W<sup>3</sup>, El-Hinnawi A<sup>3</sup> and Michaels A<sup>1\*</sup>

<sup>1</sup>Department of Gastroenterology, Hepatology and Nutrition, The Ohio State Wexner Medical Center, Columbus OH, USA

<sup>2</sup>Department of Pathology, The Ohio State Wexner Medical Center, Columbus OH, USA

<sup>3</sup>Department of Surgery, The Ohio State Wexner Medical Center, Columbus OH, USA

### Abstract

Malakoplakia is a rare inflammatory condition that can involve the genitourinary tract but also the gastrointestinal tract. It typically affects patients that are immunosuppressed or chronically ill. We present a case of malakoplakia in a patient with a past medical history of autoimmune hepatitis that underwent two liver transplantations, the last 10 years before the discovery of a symptomatic ascending colon mass that was suspicious for malignancy. He underwent a right hemicolectomy with en bloc partial duodenectomy and reconstruction for suspected adenocarcinoma. Pathology was consistent with malakoplakia and immunosuppression was subsequently decreased prior to discharge. While previous case reports have discussed the use of antibiotics or cholinergic medications that also resulted in successful treatment, it is unclear what treatment intervention is most effective for malakoplakia.

**Keywords:** Malakoplakia; Immunosuppression; Liver transplant; Colon mass

### Introduction

Malakoplakia is a chronic inflammatory condition defined by the presence of Michaelis-Gutmann bodies and von Hansemann histiocytes [1,2]. Previous case reports most commonly describe these lesions in the genitourinary tract, but rare case reports also reported presence in the gastrointestinal tract which is thought to be the most common location outside of the genitourinary tract [3,4]. Other studies have suggested an association with immunosuppressed patients [5]. We present a rare finding of locally aggressive malakoplakia in a patient that underwent liver transplantation that presented with a large, infiltrative colonic mass.

### Case Report

A 42-year-old male with a past medical history of autoimmune hepatitis status post orthotopic liver transplantation in 2004 and in 2008 maintained on azathioprine 50 mg twice daily, prednisone 5 mg daily and tacrolimus 5 mg twice daily presented for management of a colonic tumor. The patient failed to follow up with hepatology after transplantation and therefore immunosuppression was being prescribed and monitored by the patient's primary care physician for the past 2 years. Routine blood work noted an elevation in alkaline phosphatase prompting an abdominal ultrasound. Imaging revealed a slightly heterogenous, hypoechoic mass inferior and medial to the right kidney with unclear site of origin. He then underwent a computed tomography of the abdomen and pelvis with contrast that revealed a 10.3 x 7.6 x 9.2 cm colonic mass arising from the ascending colon with mildly enlarged pericolic lymph nodes.

He underwent a colonoscopy which revealed a 5 mm rectal polyp and malignant appearing tumor in the ascending colon with biopsy only confirming adenomatous neoplasm. During abdominal exploration the next day, he was found to have an ascending colon mass with invasion into the 2<sup>nd</sup> and 3<sup>rd</sup> part of duodenum. He then underwent right an en-bloc right hemicolectomy and partial duodenectomy, duodenal repair, gastrojejunostomy and pyloric exclusion with end ileostomy for presumed advanced stage adenocarcinoma.

Pathology from the rectal polyp removed during colonoscopy

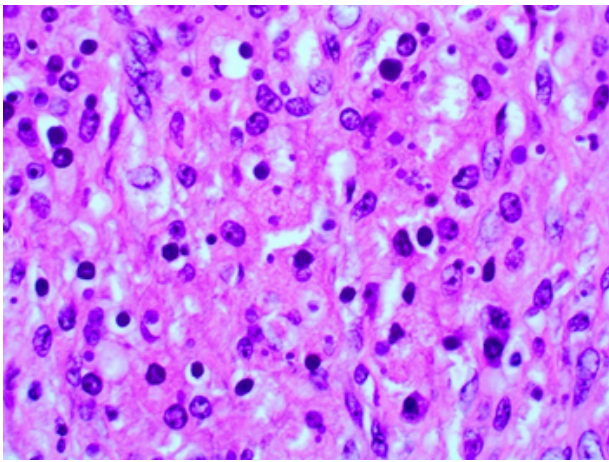
returned positive for cytomegalovirus (CMV) and he was started on valgancyclovir. Pathology from the right hemicolectomy with partial duodenectomy revealed a large (10.8 cm in greatest dimension) submucosal inflammatory mass that involved the ascending colon and extended into the duodenal wall; the mass consisted of heavy histiocytic and lymphoplasmacytic infiltrates, focal granulomata and focal microabscesses (Figure 1). A CD 68 immunohistochemical stain highlighted numerous Von Hansemann histiocytes, while a Von Kossa special stain highlighted the numerous round, laminated basophilic bodies, containing calcium in their cores, consistent with Michaelis Gutman bodies, staples for malakoplakia. Immunohistochemical stains for CMV, herpes simplex virus (HSV) I&II, Adenovirus were performed on several blocks and were negative. The enlarged mesenteric lymph nodes displayed involvement by malakoplakia, as well as focal non-necrotizing granulomata. The largest lymph nodes were stained with Grocott's methenamine silver stain (GMS) and acid-fast bacteria (AFB) and no fungus/yeast or acid fast bacilli were identified on the special stains. Epstein-Barr virus (EBV) testing showed rare positive cells within some of the lymph nodes. No histological or immunohistochemical evidence of a lymphoproliferative disorder were identified in the mesenteric lymph nodes, which were diagnosed as malakoplakia involvement in a background of reactive lymphoid hyperplasia and sinus histiocytosis. The final pathologic diagnosis was that of malakoplakia involving the ascending colon, duodenum and mesenteric lymph nodes. A large sessile tubulovillous adenoma was also seen in the right colon. His post-operative course was unremarkable, and he was discharged on tacrolimus, methylprednisolone and valgancyclovir.

**\*Corresponding author:** Anthony Michaels MD, 395 West 12th Avenue Columbus OH, 43210, USA, Tel: +1 614 293-6255; Fax: +1 614 293-8518; E-mail: [Anthony.Michaels@osumc.edu](mailto:Anthony.Michaels@osumc.edu)

**Received** October 13, 2018; **Accepted** October 31, 2018; **Published** November 07, 2018

**Citation:** Sobotka LA, Wellner M, Proca D, Cirocco W, El-Hinnawi A, et al. (2018) A Rare Etiology of Colonic Mass in a Patient that Underwent Liver Transplantation: Malakoplakia. J Clin Exp Transplant 3: 123. doi: [10.4172/2475-7640.1000123](https://doi.org/10.4172/2475-7640.1000123)

**Copyright:** © 2018 Sobotka LA, et al. This is an open-access article distributed under the terms of the Creative Commons Attribution License, which permits unrestricted use, distribution, and reproduction in any medium, provided the original author and source are credited.



**Figure 1:** Colonic mass pathology Description: 40X magnification, pathology revealing histiocytes and Michaelis–Gutmann bodies consistent with Malakoplakia.

## Discussion

We present a rare case of malakoplakia presenting as a right colon tumor in an immunosuppressed patient. Malakoplakia typically presents in the genitourinary urinary tract as a recurrent urinary tract infection or a mass [1]. The second most common location was in the gastrointestinal tract and these patients also typically presented with a mass found on imaging, during endoscopic evaluation or with nonspecific symptoms of diarrhea, abdominal pain or rectal bleeding [2,6]. Given the rarity of this disease, clinical suspicion must remain high to diagnose; however, patients are not diagnosed until there is a tissue diagnosis, as in this case. Pathology typically reveals the classic findings of a sheet of macrophages with granular eosinophilic cytoplasm and cytoplasmic Michaelis-Gitmaan bodies in macrophages [7].

It is unclear if malakoplakia is more common in patients that are immunosuppressed, though some case reports suggest a higher prevalence in these patients [8]. Patients with prolonged chronic illness and gram-negative infection were also thought to be more likely to develop malakoplakia [6,9]. Our patient developed malakoplakia in the setting of immunosuppression after liver transplantation and he had previous histologic evidence of CMV infection in the colon, but had no recorded infections with gram negative bacilli (eg. *E. coli*, *Proteus*), as reported in some of the genitourinary cases of malakoplakia. To our knowledge, less than 5 similar cases have been reported in the literature [9]. Each of the literature reported patients that developed malakoplakia after transplant had a different etiology prompting liver transplantation, including hepatitis C, hepatocellular carcinoma and, in our case, autoimmune hepatitis. Previous case reports noted that these patients were on minimal immunosuppression with monotherapy tacrolimus or tacrolimus and prednisone compared to our patient who was on triple therapy with tacrolimus, azathioprine and steroids [6,10,11]. While liver transplant patients on immunosuppression may be more likely to develop malakoplakia, it remains unclear if the diagnosis leading to transplantation and the amount of immunosuppression increases the likelihood of this complication. In this case, the patient remained on an aggressive immunosuppression regimen even after 10 years post transplantation, which likely contributed to the development of malakoplakia. His immunosuppression was being managed by his primary care physician instead of a hepatologist, and perhaps if monitored by a hepatologist his immunosuppression could have been

decreased earlier post transplantation and prevented the development of malakoplakia.

No standard of care exists in the treatment of malakoplakia. Some case reports postulate an infectious etiology and suggest the use of antibiotics as treatment, specifically an extended course of ciprofloxacin or bactrim. This approach caused the granulomatous lesions to disappear, suggesting this could be an appropriate treatment in some patients [12]. Other case reports discuss the utilization of medications that can increase low levels of cyclic guanosine monophosphate (GMP), such as cholinergic medications and noted improvement in symptoms with this therapy [13] Since some patients presented with a mass that was causing an obstruction or pain, they underwent surgical excision of the mass and were not placed on any additional therapy such as antibiotics [1]. Regardless of other interventions, whether surgical or medical, patients that developed malakoplakia while on immunosuppression were considered for a reduction in immunosuppression if possible.

Our patient underwent surgical resection of his colonic mass given an initial high concern for malignancy, as well obstructive symptoms related to large tumor size and infiltration of adjacent organs. Valganciclovir was also initiated after the initial colonic polyp biopsy returned positive for CMV. Due to chronic immunosuppression and previous history of CMV infection, there was a high index of suspicion for other active infections, but CMV, HSVI&II and Adenovirus tissue testing was negative in the resection specimen. Rare EBV positive cells in the mesenteric lymph nodes were noted, and periodic screening for the development of a post-transplant lymphoproliferative disease will be considered. The patient was not started on antibiotics therapy, as there was no evidence of an ongoing bacterial infection. With these interventions, the patient has remained asymptomatic and is doing well. Continuous clinical, laboratory and radiological follow-up will be necessary to diagnose any early complications that may recur in this patient.

## Conclusion

Malakoplakia is a rare, chronic inflammatory disease that is most commonly noted in the genitourinary tract, but also noted in the gastrointestinal system and is often misdiagnosed as a malignancy. Patients can present with a mass, abdominal pain, or diarrhea. Malakoplakia is a pathological diagnosis: Histiocytic infiltrate with lymphocytes, plasma cells, occasional granulomata and multinucleated giant cells; on biopsies, the pathognomonic histologic finding is the Michaelis-Gutman body which stains positive with calcium Von Kossa stain and an iron stain.

Malakoplakia is more commonly noted in patients that are immunosuppressed, suffering from chronic illness and with gram-negative infections with few case reports noting this complication in patients who have undergone liver transplantation. While multiple treatment interventions have been suggested, such as antibiotics, cholinergic agents, reduction in immunosuppression and surgical resection, it is unclear what is the most effective therapy. In our experience, treatment has to be tailored to the individual patient, taking into consideration surgical indications, co-existent infections and morbidities. Clinical and radiological follow-up is necessary in these patients.

## Disclosure

None of the authors have any disclosures.

## Financial Support

This case report does not have any financial support to disclose.

## Reference

1. Dong H, Dawes S, Philip J, Chaudhri S, Subramonian K (2015) Malakoplakia of the Urogenital Tract. *Urol Case Rep* 3: 6-8.
2. Long JP Jr, Althausen AF (1989) Malacoplakia: a 25-year experience with a review of the literature. *J Urol* 141: 1328–1331.
3. Yousef GM, Naghibi B, Hamodat MM (2007) Malakoplakia outside the urinary tract. *Arch Pathol Lab Med* 131: 297–300.
4. McClure J (1981) Malakoplakia of the gastrointestinal tract. *Postgrad Med J* 57: 95-103.
5. Biggar WD, Crawford L, Cardella C, Bear RA, Gladman D, et al. (1985) Malakoplakia and immunosuppressive therapy. Reversal of clinical and leukocyte abnormalities after withdrawal of prednisone and azathioprine. *Am J Pathol* 119: 5-11.
6. Hyun KH, Shin HD, Kim DH (2013) Malakoplakia in a healthy young female patient. *Korean J Intern Med* 28: 475-480.
7. Lusco M, Fogo AB, Najafian B, Alpers C (2016) Malakoplakia. *Am J Kidney Dis* 68: 27-28.
8. Purnell SDK, Davis B, Burch-Smith R, Coleman P (2015) Renal malakoplakia mimicking a malignant renal carcinoma: a patient case with literature review. *BMJ Case Rep* bcr2014208652.
9. Kim PT, Davis JE, Erb SR, Yoshida EM, Steinbrecher UP (2007) Colonic malakoplakia in a liver transplant recipient. *Can J Gastroenterol* 21: 753-755.
10. Kamishima T, Ito K, Awaya H, Mitchell DG (2000) MR imaging of bilateral renal malacoplakia after liver transplantation. *AJR Am J Roentgenol* 175: 919–920.
11. Weinrach DM, Wang KL, Cisler JJ, Diaz LK (2004) Pathologic Quiz Case: A 54-Year-Old Liver Transplant Recipient With Diffuse Thickening of the Sigmoid Colon. *Arch Pathol Lab Med* 128: e133-e134.
12. Furth RV, Wout JV, Zwartendijk J, Wertheimer P (1992) Ciprofloxacin for treatment of malakoplakia. *Lancet* 339: 148-149.
13. Abdou NI, NaPombejara C, Sagawa A, Ragland C, Stechschulteet DJ, et al. (1997) Malakoplakia: Evidence for monocyte lysosomal abnormality correctable by cholinergic agonist in vitro and in vivo. *N Engl J Med* 297: 1413–1419.