

## Thyroglossal Fistula Presented with Multiple Tracts – A Case Report

Jyoti Ranjan Das\*, Debabrata Biswas and Ajay Manickam

Rg Kar Medical College, Kolkata, India

\*Corresponding author: Jyoti Ranjan Das, Rg Kar Medical College, Kolkata, India, Tel: 033 2555 7656; E-mail: [jdbegins007@gmail.com](mailto:jdbegins007@gmail.com)

Rec date: December 09, 2015; Acc date: January 18, 2016; Pub date: January 23, 2016

Copyright: © 2016 Das R J et al. This is an open-access article distributed under the terms of the Creative Commons Attribution License, which permits unrestricted use, distribution, and reproduction in any medium, provided the original author and source are credited.

### Abstract

Congenital anomalies in the neck region are formed at birth, however, the resulting lump or complications related to them appear sometimes in later adult life. The thyroglossal duct cyst is the most common congenital lesions. Generally it ends in foramen caecum. But in case of infected thyroglossal cyst, when gets ruptured or if inadequately excised, can end anywhere in neck. It may have single tract or multiple tracts. We present a case of thyroglossal duct tract with two endings in different place.

**Keywords:** Thyroglossal cyst duct; Infected; Multiple tracts

### Introduction

Thyroglossal duct cyst is the most common congenital midline cervical anomaly [1]. They are more common in the pediatric population under 5 years of age, and 60% of lesions are diagnosed before the age of 20 [2]. Frequently the cyst ruptures spontaneously or is incised; an intermittent draining channel which may blindly end in tissue, that is, a sinus or may run uninterruptedly to enter to mouth at foramen caecum, that is a fistula [3]. Thyroglossal fistula may be congenital or acquired. Congenital Thyroglossal fistula is a disorder of thyroglossal duct which develops from thyroid primordium in the floor of primitive pharynx at the site of foramen caecum at the junction of posterior one third and anterior two third of tongue. The descending thyroid gland migrates through the tongue tissue passing anterior to hyoid bone to lie in anterior neck. This line of descent from foramen caecum is marked by thyroglossal duct. If involution of thyroglossal duct is incomplete thyroglossal cyst develops [4]. Clinically the site is more at the level below hyoid bone than above it. It accounts for 70% all congenital neck mass [5] and 2 to 4% of all neck masses [6]. About 15 to 50% are at the level of hyoid bone, 20 to 25% are suprahyoid, and 25 to 65% are infrahyoid [7]. Presentation of thyroglossal cyst or duct. The presentation is delayed beyond infancy and often in childhood. The cyst or fistula is usually in the midline or in 10% case presented laterally on left side. It moves with deglutition. Protusion of tongue by elevating the hyoid bone results in cyst or fistulous opening being pulled upward [4]. Treatment of thyroglossal duct cyst or fistula is Sistrunk operation which includes removal of cyst or fistula tract with hyoid bone. The tract is then followed through the tongue in the midline. If no tract is visible, a core of tissue is removed up to foramen caecum.

Generally thyroglossal fistula has only one tract. We present a case of 18 yr girl presenting with a discharging sinus at the midline of which during operation shows 2 tract one ending over hyoid bone and other over strap muscles.

### Case Report

A 18 year girl presented to outpatient department of a tertiary care hospital with complain of intermittent discharge from neck for last 4

years. Detailed history of patient was taken which revealed 4 years back she developed an abscess at a point just lateral to midline of neck at the junction of upper one third and lower two third which ruptured spontaneously after 10 days. There after intermittent discharge has been occurring till now which is little in amount, mucoid in consistency, not blood tinged, not painful and aggravated in upper respiratory tract infection. There was itching. Discharge was being subsided with medication. There was no past history of any previous neck infection, any neck surgery and Tuberculosis. On examination, there was an opening on left side of neck around 2 inches lateral to thyroid cartilage with no active discharge, no hood of skin (Figure 1). It was moving with deglutition and protrusion of tongue. Skin over opening was dark in colour in comparison to surrounding skin. On palpation, it was nontender and wall of sinus was thickened. There were no palpable neck nodes. Oral cavity, oropharynx, posterior rhinoscopy, indirect laryngoscope examination, nose, ear are within normal limit. Systemic examination was also normal. Fistulogram was done which was confirmatory of thyroglossal fistula. Sistrunk operation was done under general anesthesia. Methylene blue dye was given through opening of tract. A transverse elliptical incision was given around the opening of tract. The tract was then explored and two tracts were seen, one ending at hyoid bone and other over strap muscle neck sternohyoid (Figure 2). Corrugated rubber drain was given. Subcutaneous layer was closed with vicryl and skin was closed with ethilon. Specimen (Figure 3) was sent for histopathological examination. Drain was removed after 48 hrs. Postoperative recovery was uneventful. Histopathological report (Figure 4) shows tract is lined by columnar epithelium with inflammatory features. Underlying stroma contains mucus gland and thyroid follicles. Patient was followed up for last six months and there was no recurrence.

### Discussion

Cyst and sinuses in the neck may be formed along the course of 1st, 2nd, 3rd or 4th branchial clefts as a result of improper closure during embryonic life. Thyroglossal Cyst and fistula are similar defects located in or near the midline of neck. The descent of developing thyroid results in the formation of a thyroglossal duct extending from base of tongue to isthmus of thyroid gland. It is in close relationship with hyoid bone, passing in front of it until, at its lower margin, it loops up behind the bone before turning to thyroid isthmus. It disappears in

embryonic life, only its original connection with base of tongue remains as the foramen caecum on the tongue. Any portion of duct it may remain resulting in (a) Thyroglossal fistula, (b) Thyroglossal sinus, (c) Thyroglossal cyst [8]. Thyroglossal cysts predominate with fewer sinus and fistula. Thyroglossal duct carcinoma is rare, estimated no more than 1% of Thyroglossal duct cyst and when it supervenes, it is usually a sub type of papillary thyroid carcinoma [9].

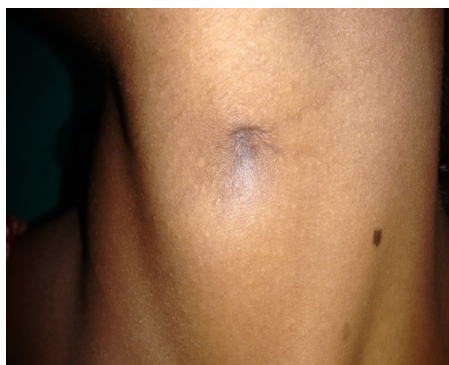

Figure 1: fistula opening in left side of neck.

A thyroglossal duct cyst often appears after upper respiratory tract infection [10]. In nearly 50% of affected children the cyst or fistula manifest as an infected midline upper neck mass [10]. The complete congenital thyroglossal fistula is rare and the more common presentation is midline sinus with its point of discharge just below the hyoid bone, resulting from sepsis in a portion of congenital tract or from an infected thyroglossal cyst. The discharge is purulent or glairy and is intermittent due to skin healing and breaking down [8]. Treatment of thyroglossal duct cyst or fistula is Sistrunk operation [11]. Which includes removal of cyst or fistula tract with hyoid bone. The tract is then followed through the tongue in the midline. If no tract is visible, a core of tissue is removed up to foramen caecum. It is essential to remove the whole of thyroglossal tract, particularly if it is patent, as any portion of the epithelial lining left behind will lead to recurrence. Recurrent ruptures of the thyroglossal cyst either spontaneous or iatrogenic can give rise to multiple fistulous tracts. A thyroglossal fistula between the base of the tongue and neck skin due to persistence of the entire thyroglossal duct (a true Thyroglossal lesion). Multiple inadequate and inappropriate procedures on thyroglossal tract disease can lead to formation of Thyroglossal fistula with multiple fistulous tracts. Incision and drainage on the infected thyroglossal duct cysts complicate management by generating scarring and creating abnormal tissue planes, making dissection difficult.

## Conclusion

A thyroglossal fistula is often caused by spontaneous rupture of thyroglossal cyst or inadequate excision of thyroglossal cyst or tract. When thyroglossal fistula is presented with multiple tracts, the tract may end at different sites of neck. Our case shows one type which is having two tract one ending at hyoid bone and other ending over strap muscle of neck. This report shows that there is a possibility that anomaly can be seen in a simple case, hence we should always keep in mind and look for a possible associated or concurrent lesion. Hence this case is reported.

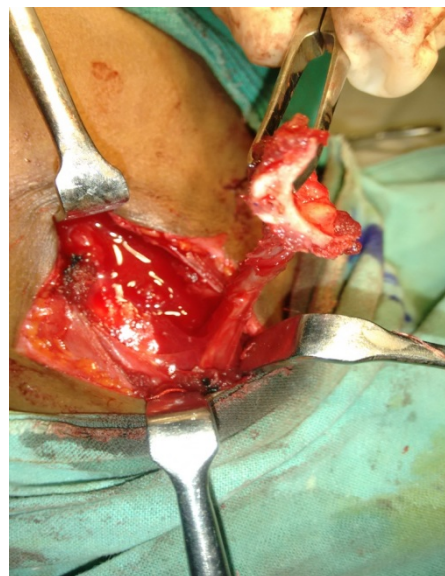


Figure 2: fistula tract with one end attached to hyoid bone and other end attached to sternohyoid muscle.

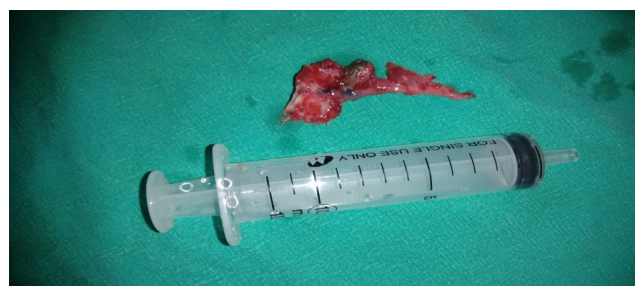

Figure 3: Specimen of thyroglossal tract with hyoid bone attached at one end and sternohyoid muscle at other end.

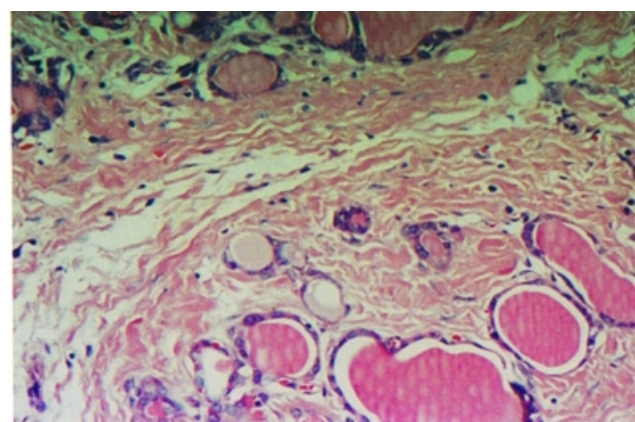


Figure 4: Histopathological report of thyroglossal fistula.

---

## References

1. Johnson JT, Rosen CA. *Bailey's Head and Neck Surgery- Otolaryngology.*
2. Madana J, Yolmo D, Saxena SK, Gopalkrishna S (2009) True Thyroglossal Fistula. *Laryngoscope* 119: 2345- 2347.
3. Pemberton JD, Stalker LK (1940) Cysts, Sinuses and Fistulae of the Thyroglossal Duct-Results in Two Hundred and Ninety-Three Surgical Cases. *ANN Surg* 111: 950-957.
4. Giesson M, Brown's S. *Otorhinolaryngology and Head and Neck Surgery.* (7th edn), Arnold publication, United Kingdom.
5. Montgomery WN (1973) *Surgey of Upper Respiratory System.* Lea and Febiger, Philadelphia.
6. Eversole LR (1992) *Clinical Outline of Oral Pathology Diagnosis and Treatment.* Lea and Febiger, Philadelphia.
7. Gandhi RA, Bhowate R, Degweker S, Bhake A (2011) Case Report in Dentistry.
8. Wilson JSP. *Operative Surgery Fundamental International Techniques.* Head and Neck Part 2. Butterworth and co publishers ltd, London.
9. Watkinson JC, Gilbert RW. *Stell and Maran's Textbook of Head and Neck Surgery and Oncology,* (5th edn), Hodder Arnold publication, United kingdom.
10. Stanton K, St Geme, Schor. *Nelson Textbook of Paediatrics First South Asia.* Elsevier Publication, USA.
11. Sistrunk WE (1920) Technique of Removal of Cysts and Thyroglossal Duct. *Annals of surgery* 71: 121-124.