

# The Carpal Tunnel Syndrome Caused by *Arthrinium Phaeospermum* Infection: First Case Report and Literature Review

Li Miaozhong<sup>1</sup>, Li Yuning<sup>2</sup> and Li Xueyuan<sup>1\*</sup>

<sup>1</sup>Department of Hand Surgery, Ningbo No.6 Hospital, Ningbo, China

<sup>2</sup>Department of Hand Surgery, Clinical Medical Laboratory Center, Ningbo No.6 Hospital, Ningbo, China

## Abstract

**Background:** The Carpal Tunnel Syndrome (CTS) caused by atypical infectious is a therapeutic and diagnostic challenge. Because non-specific clinical presentation often results in misdiagnosis and incorrect therapy, failing to elicit an accurate exposure.

**Case presentation:** This article reports a case of deep infection leading to CTS manifestations. A male patient was admitted for numbness and pain of the left hand. Left carpal tunnel release, median nerve decompression, synovectomy of the carpal tunnel were performed. Inflamed synovium and effusion were submitted for bacterial culture and metagenomic Next-Generation Sequencing (mNGS). The causing pathogen was identified as *Arthrinium phaeospermum* and the patient recovered after surgical debridement and 10 months of antimicrobial therapy.

**Conclusion:** Diagnosis of fungi infection of the hand is challenging as the presentation mimics other conditions without much histological findings. NGS is proposed of great importance adjunctive diagnostic approach for identifying atypical infectious quickly.

**Keywords:** *Arthrinium phaeospermum*; Next-generation sequencing; Carpal tunnel syndrome; Infectious

**Abbreviations:** CTS: Carpal Tunnel Syndrome; mNGS: metagenomic Next-Generation Sequencing

## Introduction

Carpal Tunnel Syndrome (CTS) is the most common peripheral nerve compression disorder, caused by idiopathic carpal transverse ligament thickening, synovial hypertrophy, etc. [1]. In addition, CTS caused by secondary infection of atypical bacteria such as mycobacterium tuberculosis, non-tuberculous mycobacteria and fungi, is a therapeutic and diagnostic challenge. Because the infection is rare and often fails to elicit a history of traumatic exposure [2].

*Arthrinium phaeospermum* is a globally distributed conditional pathogenic fungus with a wide host range, mainly in plants, and can also lead to skin lesions in humans and animals [3]. In 1990, Rai reported the first case of human skin infection with this pathogen [4]. Subsequently, four cases of human infection with *A. phaeospermum* were clinically reported, all of them were superficial skin infections occurring in mainland China [5-8]. This article reports a case of deep infection leading to CTS manifestations, the causing pathogen was identified as *A. phaeospermum* by Metagenomic Next-Generation Sequencing (mNGS) and culture, and the patient recovered after surgical debridement and 10 months of antimicrobial therapy. The following report discussed the diagnosis and treatment process for this rare case of *A. phaeospermum* infection presented with acute CTS.

## Case Presentation

A 64-year-old patient lives in coastal area. He was hospitalized for “numbness and pain in the 1-4 fingers of the left hand for 3 weeks”. He had no obvious inducing factors, the pain radiated from finger to the palm, worsen at night, affecting his sleep. Antibacterial therapy was given in the local hospital without obvious effect. Medical history was unremarkable except a habit of alcohol consumption.

Physical examination showed mild swelling of the left wrist, elevated skin temperature, mild atrophy of the thenar major muscles of the left palm, tenderness over the wrist and numbness over 1-4 fingers, along with positive Tinel's sign and Phalen's test. The finger flexion movement was restricted (Figure 1). Pain score VAS: 6 points.

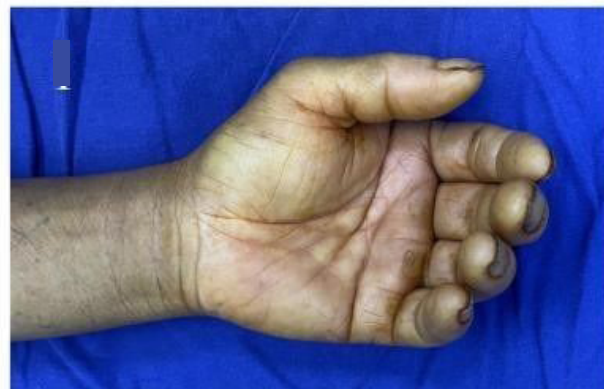

Figure 1: Before surgery, the finger flexion movement was restricted.

## Investigations

The radiographic imaging of the chest, hand and wrist were non-specific, as were the laboratory tests. EMG demonstrated slowed median nerve conduction velocity at the left wrist, abductor pollicis brevis motor unit potential amplitude 2.1 mV, latency 4.5 ms, which indicated CTS.

\*Corresponding author: Li Xueyuan, Department of Hand Surgery, Ningbo No.6 Hospital, Ningbo, China, E-mail: lixueyuan2000@163.com

**Received:** 10-Apr-2024, Manuscript No. JIDT-24-132134; **Editor assigned:** 12-Apr-2024, Pre QC No. JIDT-24-132134 (PQ); **Reviewed:** 29-Apr-2024, QC No. JIDT-24-132134; **Revised:** 06-May-2024, Manuscript No. JIDT-24-132134 (R); **Published:** 13-May-2024, DOI:10.4173/2332-0877.24.S6.003.

**Citation:** Miaozhong L, Yuning L, Xueyuan L (2024) The Carpal Tunnel Syndrome Caused by *Arthrinium Phaeospermum* Infection: First Case Report and Literature Review. J Infect Dis Ther S6:003.

**Copyright:** © 2024 Miaozhong L, et al. This is an open-access article distributed under the terms of the Creative Commons Attribution License, which permits unrestricted use, distribution, and reproduction in any medium, provided the original author and source are credited.

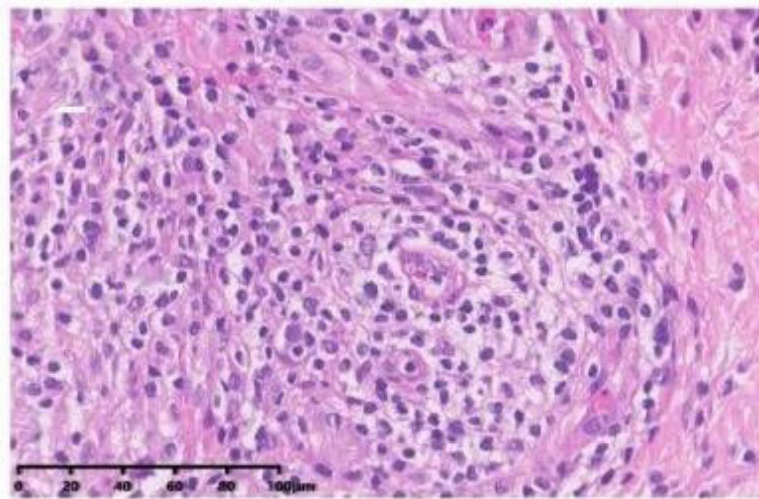
## Treatment

The patient underwent left carpal tunnel release, and a synovectomy of carpal tunnel and forearm. About 1 ml of yellow exudate was observed in the carpal tunnel. The inflamed proliferative synovium was adherent to the flexor tendons. The median nerve was compressed and flattened, with congestive changes of the epineurium. The exudate and inflammatory synovial tissue were sent for routine bacterial culture, mycobacterial culture, pathology and mNGS, respectively. Then we performed thorough debridement of the inflamed synovium. Cefoperazone Sodium and Sulbactam Sodium 1.5 g iv q12h was performed postoperatively.

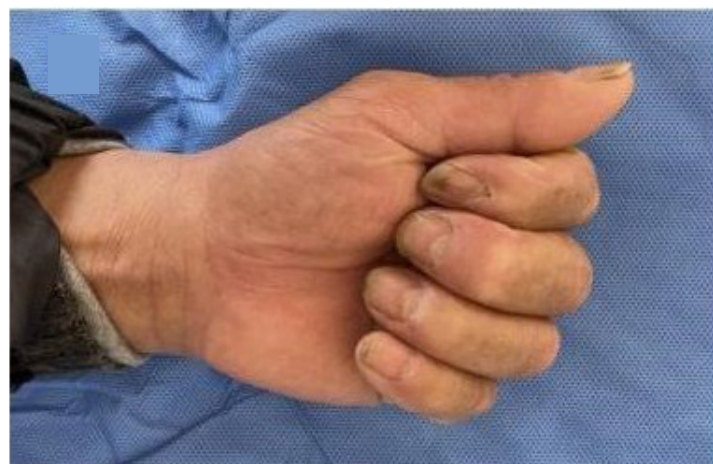On the second day, mNGS reported *A. phaeospermum* infection. Fungal growth was reported in the culture, consistent with the characteristics of *A. phaeospermum* later. Histopathology showed chronic synovitis with non-caseating granulomas, inflammatory cell

infiltrate with proliferating capillaries (Figure 2).but there was no fungus was observed by special staining.

The previous antibiotic was discontinued and Fluconazole 200 mg twice daily was prescribed. At the 6-week postoperative follow-up, numbness and pain in the patient's left hand were significantly relieved and the range of motion of fingers showed improvement compared to preoperative status. There was mild swelling of the wrist, and limited ability to make a fist with the fingers (Figure 3). Two months after surgery, patient changed his medicine to Terbinafine in a local hospital. There was no significant relief of wrist redness and swelling and patient complained of gastrointestinal symptoms one month later. Thus Terbinafine was replaced with oral Fluconazole again (with a change in manufacturer). There was only occult swelling in the wrist and no signs of recurrence were observed at 6-months follow up. At the 10 month, the patient restored almost full range of motion of the hand activity without any symptom (Figure 4).



**Figure 2:** There is prominent synovial hyperplasia characterized by the development of nodular structures, with a notable infiltrate comprising lymphocytes, plasma cells, and foam cells evident upon microscopic examination. The presence of these cellular constituents suggests an active inflammatory process within the synovium.



**Figure 3:** There was mild swelling of the wrist, and limited ability to make a fist with the fingers at the 6 weeks follow-up.

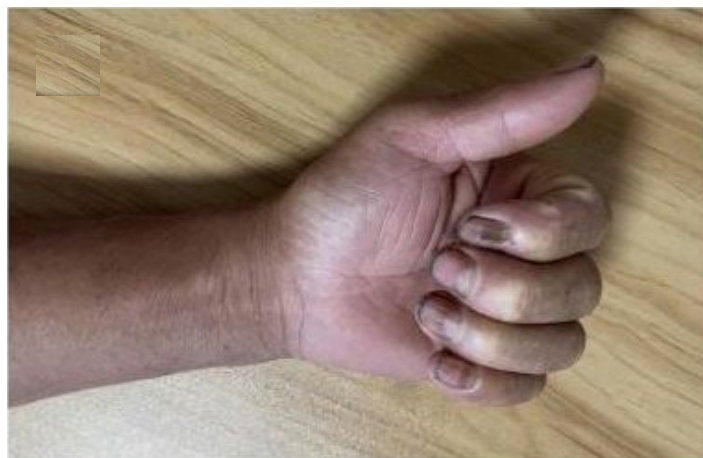

Figure 4: At the 10 month, the patient made almost full recovery of the motion range without any symptom.

## Discussion

### Biological characteristics of *A. phaeospermum*

*A. phaeospermum* belongs to the Ascomycota and can cause diseases in various plants. It is widely present in the environment. Khan et al., first confirmed it as a phytopathogenic fungus in 1980 [9]. Zhu et al., first proved that it could lead to withering disease of hybrid bamboo [10-12]. It is also one of the conditional pathogenic fungi causing cutaneous fungal diseases in humans and animals. Zhao Yaoming's research confirmed that *A. phaeospermum* could infect rabbits, cavy and mice, damage hair follicles and sebaceous glands, and produce liposoluble toxins leading to skin damage [11]. In addition, Bloor et al., found that *A. phaeospermum* could produce aromatic acids when infecting the human body [11,12], and Rai et al., first isolated *A. phaeospermum* from the skin lesions of patients [4]. In immunocompromised populations, fungi can occasionally cause deep hand tissue infections, which have been reported in individual cases, but not the *A. phaeospermum*. And this patient had no other evidence of immunodeficiency except a long history of alcohol drinking.

In recent years, many studies have confirmed that it can produce various secondary metabolites and enzymatic proteins involved in pathogenesis. Li et al., discovered that *A. phaeospermum* could produce a protein toxin that increases mitochondrial lipid peroxidation, inhibits respiration, and plays an important role in its pathogenicity. But the specific virulence-related genes and mechanisms of action need further in-depth study [12,13].

### Characteristics of CTS caused by infection

The carpal tunnel is a narrow anatomical canal. In addition to the median nerve, there are also nine flexor tendons inside the carpal tunnel cavity. Any inducing factor that alters the structures in the carpal tunnel can compress the median nerve, leading to characteristic symptoms with pain or paresthesias in radial and half fingers and weakness or muscle atrophy of the thenar major [3].

Local inflammation is also involved in the occurrence of CTS. Acute or chronic local inflammation caused by infection may stimulate proliferation of the carpal tunnel contents, compressing the nerves indirectly. Infectious CTS is relatively rare, with most cases caused by *Staphylococcus*, which can lead to purulent tenosynovitis and cause

CTS secondarily. Mascola JR reviewed documented infectious causes of CTS, such as common bacteria, mycobacterium tuberculosis, atypical mycobacteria, and fungi. For those atypical infections, non-specific clinical presentation may lead to misdiagnosis and delayed therapy, even incorrect treatment [14]. Compared with mycobacterial infections, fungal infections such as *Coccidioides immitis*, *Sporothrix schenckii*, have a higher tendency of recurrence. Most patients begin to suspect infection when they see a large amount of inflamed proliferative synovium during surgery. Moreover, special cultures take 4-6 weeks or longer, causing more difficulties for treatment. After diagnosis, targeted antimicrobial treatment needs to last for months.

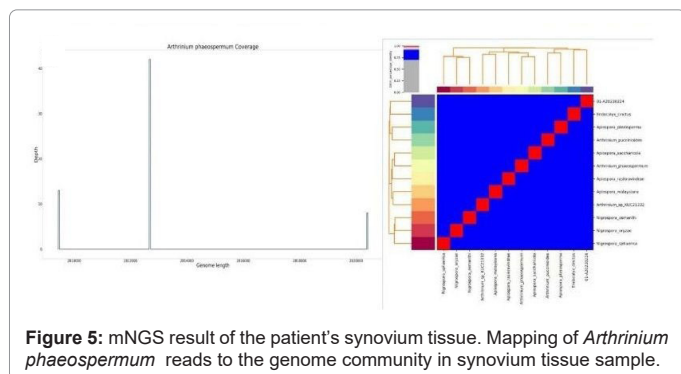
This patient has been taking oral fluconazole for nearly one year and eventually recovered. Currently there is no sign of recurrence. We performed mNGS of the cultured strain, and the results showed that the fungal genome contains abundant gene clusters encoding carbohydrate active enzymes, effector proteins and secondary metabolism-related genes, some of which are related to pathogenicity. It indicates that *A. phaeospermum* may have been involved in the infection process of the lesion tissue through its metabolic products and effector proteins.

Unlike pyogenic infections, fungal and mycobacterial infections are more likely to be overlooked in clinics [15,16]. Clinical reports of *A. phaeospermum* infection are rare. It is an opportunistic pathogen that tends to invade immunocompromised populations. This patient had nothing special but living in where suitable for bamboo and other agriculture. Given that *A. phaeospermum* can lead to withering disease of hybrid bamboo [8], it reminds us that we should increase awareness of this pathogen and strengthen fungal culture and identification of surgical samples to avoid misdiagnosis. Regarding treatment, thorough removal of inflamed synovium combined with postoperative antifungal treatment is currently the consensus treatment plan. When selecting antifungal drugs, hand surgeons should consult opinions from infectious disease specialists to achieve adequate dosage and duration as much as possible [14].

### Application of mNGS in the diagnosis of infectious diseases

Traditional pathogen culture and morphological identification require a certain amount of time, and some pathogens are difficult to culture, causing some limitations. In recent years, the development of mNGS technology has brought new opportunities for the diagnosis

of infectious diseases, and has been widely used in the detection of bacterial and viral infections [17]. Genomic sequencing can detect all pathogen information in body fluid and tissue samples by non-specific amplification and direct sequencing of all genomic DNA, enabling detection of unknown pathogens. This provides strong support for the diagnosis of infectious diseases. In this case, mNGS (Figure 5) quickly discovered the presence of *A. phaeospermum* in the patient's carpal tunnel synovial sample, providing important diagnostic evidence for the clinic.



## Conclusion

*A. phaeospermum* can cause multiple system infections in plants and animals, and its pathogenic mechanism is related to the secreted toxins and enzymes. This case suggests that *A. phaeospermum* can also stimulate synovial hyperplasia in the carpal tunnel, leading to the rare fungal CTS. Its clinical manifestations are similar to mycobacterial infections, and are very easily overlooked clinically. For abnormal inflammatory hyperplastic synovial changes found during surgery, timely bacteriological testing should be performed. The current mNGS technology allows rapid detection of pathogens, avoiding misdiagnosis and mistreatment.

## Ethics approval and consent to participate

The study was conducted in accordance with the local legislation and institutional requirements which was approved by the Ethics Committee of Ningbo No. 6 Hospital. The patient provided his written informed consent to participate in this study.

## Consent for publication

Written informed consent was obtained from the patient for publication of this case and any accompanying images report. A copy of the written consent is available for review by the Editor of this journal.

## Availability of data and materials

The datasets used and/or analysed during the current study are available from the corresponding author on reasonable request.

## Competing interests

The authors declare that the research was conducted in the absence of any commercial or financial relationships that could be construed as a potential conflict of interest.

## Funding

This study was supported by grants from the Ningbo Top Medical and Health Research Program (No.2022020506), Ningbo Key Research and Development Program (No. 2022Z146).

## Authors' contributions

Conception and design of the study, Operation: Xueyuan Li and Miao Zhong Li. Acquisition of data: Yuning Li. Analysis and interpretation of the data: Miao Zhong Li. Writing of the manuscript: Miao Zhong Li. Critical revision of the manuscript for intellectual content: Xueyuan Li. All authors contributed to the article and approved the submitted version.

## Acknowledgements

The authors thank the workmates for their efforts in the clinical management of this patient.

## References

1. Pai M, Bhat AK, Acharya AM, Reddy SP (2022) Unusual presentation of carpal tunnel syndrome due to *Mycobacterium marinum* infection of hand. *BMJ Case Rep* 15(12):e251692.
2. Mascola JR, Rickman LS (1991) Infectious causes of carpal tunnel syndrome: Case report and review. *Rev Infect Dis* 13(5):911-917.
3. Li S, Tang Y, Fang X, Qiao T, Han S, et al. (2020) Whole-genome sequence of *Arthrinium phaeospermum*, a globally distributed pathogenic fungus. *Genomics* 112(1):919-929.
4. Rai MK (1989) Mycosis in man due to *Arthrinium phaeospermum* var. *indicum*. First case report: Mykose durch *Arthrinium phaeospermum* var. *indicum* beim Menschen. *Mycoses* 32(9):472-475.
5. Zhao YM, Deng CR, Chen X (1990) *Arthrinium phaeospermum* causing dermatomycosis, a new record of China. *Acta Mycologica Sinica* 9(3):232-235.
6. LU G, Shen Y, Chen W, HU S, LI H, et al. (1995) Cutaneous mycosis caused by *arthrinium phaeospermum*: A case report. *Chin J Dermatol* 38(4): 232-234.
7. HU S, Zhan P, Lyu G, Mei H, Zeng X, et al. (2016) A case of cutaneous *Arthrinium phaeospermum* infection after lower limb amputation. *Chin J Dermatol* 726-728.
8. Xue-wen CH, Hong-mei ZH, Hai WE (2016) A case of cutaneous mycosis caused by *Arthrinium phaeospermum*. *Chin J Mycol* 11(6):357.
9. Khan KR, Sullia SB (1980) *Arthrinium phaeospermum* var. *indicum* var. *nov.*, a new market pathogen of cowpea, garden pea and french bean. *Acta Botanica Indica* 8(1):103-104.
10. Zhao YuMing ZY, Wen ShuTian WS, Liu MingLi LM, Jiang YuBo JY, Zhang ShuSen ZS, et al. (1997) Mycosis caused by *Arthrinium phaeospermum*, its animal toxicity and pathological analysis. *Mycosystema* 16(2):112-116.
11. Bloor S (2008) Arthrinic acid, a novel antifungal polyhydroxyacid from *Arthrinium phaeospermum*. *The Journal of antibiotics*. 61(8):515-517.
12. Li ShuJiang LS, Liang Man LM, Zhu TianHui ZT, Yang ChangQing YC (2013) Selection of an antagonistic bacterium against *Arthrinium phaeospermum* and its antibacterial protein analysis. *J Nanjing Forestry Univ* 37:27-32
13. King V, Crouser N, Speckaert A, Bhatt R (2023) Infection management for the hand surgeon. *Hand Clinics* 39(3):465-473.
14. Hassanpour SE, Gousheh J (2006) *Mycobacterium tuberculosis*-induced carpal tunnel syndrome: Management and follow-up evaluation. *J Hand Surg Am* 31(4):575-9.
15. Fox MP, Jacoby SM (2020) Fungal infections of the hand. *Hand Clin* 36(3):355-60.
16. Zhang K, Yu C, Li Y, Wang Y (2020) Next-generation sequencing technology for detecting pulmonary fungal infection in bronchoalveolar lavage fluid of a patient with dermatomyositis: A case report and literature review. *BMC Infect Dis* 20:1-7.
17. Fang X, Yan P, Luo F, Han S, Lin T, et al. (2022) Functional identification of *arthrinium phaeospermum* effectors related to *bambusa pervariabilis* × *dendrocalamopsis grandis* shoot blight. *Biomolecules* 12(9):1264.