

Spontaneous Common Bile Duct Perforation: A Rare Cause of Biliary Peritonitis in a Patient of Chronic Calcific Pancreatitis

Vivek Rajdev^{1*}, Nandakumar BM², Rakesh Gupta¹, Pankaj Chandel¹ and Jagdish Gupta¹

¹Department of General Surgery, Indira Gandhi Medical College and Hospital, India

²Department of General Surgery, MS Ramaiah Medical College, India

Abstract

Spontaneous perforation of common bile duct is a rare cause of acute generalized peritonitis. It is difficult to diagnose pre-operatively and mainly caused due to increased intra-ductal pressure of common bile duct, which can occur due to stone, stricture or malignancy.

Here, we present an interesting case report of spontaneous common bile duct perforation in a patient of chronic calcific pancreatitis leading to peritonitis, the management protocol with highlight on previous literature.

Keywords: Chronic calcific pancreatitis; Biliary peritonitis; Spontaneous CBD perforation; Rare cause of peritonitis; Isolated CBD perforation

Introduction

Spontaneous perforation of common bile duct (CBD) is an infrequent cause of acute generalised peritonitis [1]. Other common causes being peptic ulcer disease complicated by duodenal or gastric perforation and unusually by gall bladder perforation. It is almost always diagnosed intra operatively and it is a rare entity in adults. The common causes are increased intraductal pressure due to stone, tumour, stricture and erosion of a biliary diverticulum. The incidence of common bile duct obstruction among patients with chronic pancreatitis range from 3% to 23% [2]. Till date only three cases of spontaneous common bile duct perforation with peritonitis as a complication in chronic pancreatitis has been reported [3]. We report an interesting case of spontaneous common bile duct perforation in a middle aged male with chronic calcific pancreatitis and review literature of such cases.

Case Report

A 35 year old male patient was referred from a private hospital as a non-settling case of acute on chronic pancreatitis being managed conservatively for the last 4 days. Patient had complaints of generalised pain abdomen with multiple episodes of vomiting.

On examination he was sick looking and dehydrated with tachycardia, tachypnoea and was normotensive. On examination, the abdomen was distended and tender with presence of free fluid and absent bowel sounds. Initial investigations revealed haemoglobin 15.1 gm/dL, white cell count 27,100/cumm with 94% segmented neutrophils, serum bilirubin was 1.84 mg/dL, transaminases and alkaline phosphatase (ALP) were normal. Serum Amylase and Lipase were 321 U/L and 393 U/L respectively. Ultrasound abdomen showed moderate ascites with multiple pancreatic calcifications. Chest X-ray was normal and abdominal X-ray showed evidence of ileus with calcification in the region of pancreas (Figure 1, yellow arrow) with no evidence of air under diaphragm. Contrast enhanced Computed Tomography (CECT) of abdomen showed features of acute exacerbation with chronic calcific pancreatitis with multiple intraluminal calculi and normal common bile duct. Diagnostic paracentesis showed bilious fluid.

With the provisional diagnosis of biliary peritonitis, patient was taken up for explorative laboratory. Upon exploration, 1.5 litres of bilious peritoneal fluid was aspirated, omentum was studded with calcifications. The duodenum and stomach were normal. Gallbladder was intact and didn't contain

any calculus. The common bile duct was mildly dilated 8 mm with a perforation of 5 x 5 mm in supraduodenal part (Figure 2, white arrow). It didn't contain any calculus and distal patency was maintained. Cholecystectomy with primary closure of common bile duct perforation was done.

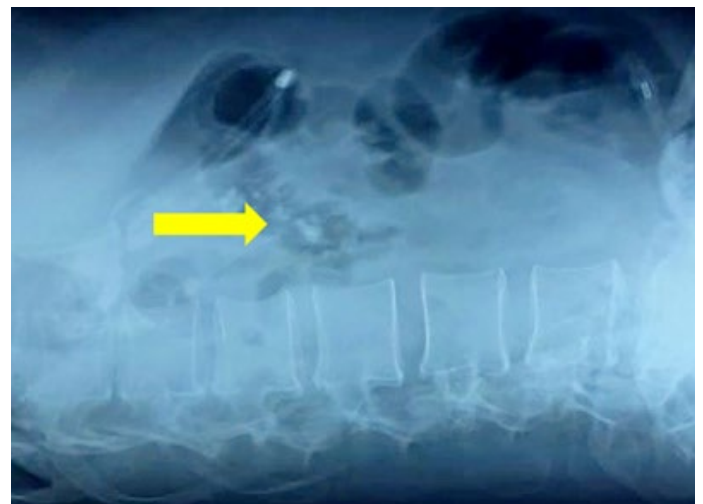


Figure 1: Abdominal X-ray showing calcification in region of pancreas (yellow arrow)

Post-operative Magnetic Resonance Cholangiopancreatography (MRCP) showed smooth tapering of CBD into duodenum with acute on chronic mass forming pancreatitis with multiple calculi in pancreatic duct.

Patient had an uneventful postoperative recovery and was discharged on

***Corresponding author:** Vivek Rajdev, Department of General Surgery, Indira Gandhi Medical College and Hospital, India, Tel: +919917153044; E-mail: vivekrajdev.43@gmail.com

Citation: Rajdev V, Nandakumar BM, Gupta R, Chandel P, Gupta J (2022) Spontaneous Common Bile Duct Perforation: A Rare Cause of Biliary Peritonitis in a Patient of Chronic Calcific Pancreatitis. J Gastrointest Dig Syst. 12:673

Received: 21-February-2022, Manuscript No. JGDS-22-55029; **Editor assigned:** 23-February-2022, PreQC No. JGDS-22-55029(PQ); **Reviewed:** 09-March-2022, QC No. JGDS-22-55029; **Revised:** 14-March-2022, Manuscript No. JGDS-22-55029(R); **Published:** 21-March-2022, **DOI:** 10.4172/2161-069X.1000673

Copyright: © 2022 Rajdev V, et al. This is an open-access article distributed under the terms of the Creative Commons Attribution License, which permits unrestricted use, distribution, and reproduction in any medium, provided the original author and source are credited.

6th post-operative day.

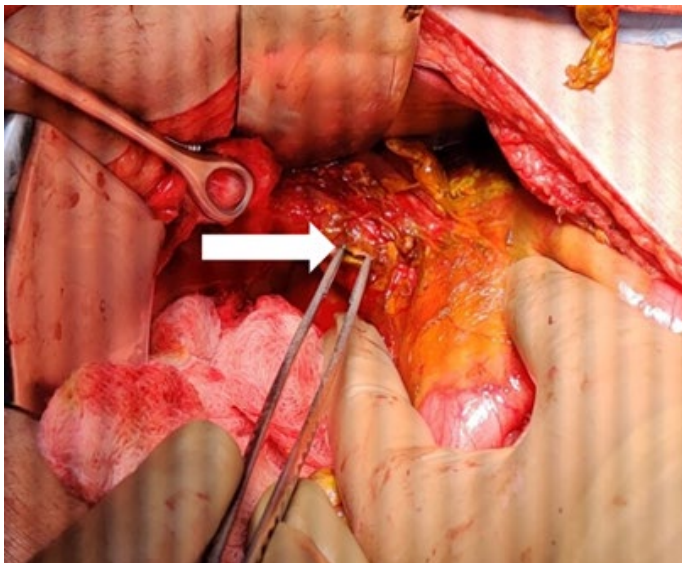


Figure 2: CBD perforation of size 5 x 5 mm (white arrow)

Discussion

Spontaneous extrahepatic bile duct perforation is a rare entity. Since its first description by Freeland in 1882 only 90 cases have been reported in infancy and 97 cases in adults [4]. Pathogenesis of spontaneous CBD perforation is not clearly understood. Proposed mechanisms are increased intraductal pressure due to stone, stricture and tumour and weak CBD wall due to pancreatic juice reflux, Anomalous Pancreaticobiliary Junction (APBJ), choledochal cyst and connective tissue disorders. Complications of chronic pancreatitis are pseudocyst (25%), CBD obstruction (3%-23%), duodenal obstruction (0.5%-13%), pancreatic fistula and malignancy [2]. Chronic pancreatitis presenting as biliary peritonitis secondary to CBD perforation to our knowledge has only been reported three times and all three were in paediatric age group and had impacted pancreatic calculus at duodenal papilla [3] and one patient had APBJ [5].

Presentation is usually insidious with diffuse abdominal pain, vomiting, jaundice and patient is usually septic with raised white cell counts. Bilirubin and transaminases are seldom deranged [6]. Absence of air under diaphragm with moderate ascites with normal gall bladder on ultrasound with a diagnostic ascetic tap showing bile should raise a suspicion of bile duct perforation. CECT abdomen is rarely informative of CBD perforation. Endoscopic Retrograde Cholangiopancreatography (ERCP) and MRCP to delineate biliary and pancreatic anatomy and Radio-nucleotide study dem-

onstrating tracer in peritoneum is diagnostic but it is rarely done due to non-availability and lack of suspicion. ERCP with stenting across perforation can be done if perforation is diagnosed preoperatively. Reports of two cases managed with ERCP are available [7]. Spontaneous CBD perforation is almost always diagnosed intraoperatively and is usually managed with cholecystectomy with CBD exploration with primary repair or repair over T-tube [1]. In our case, primary repair of CBD was done after confirming distal patency with post-operative MRCP. Biliary-enteric anastomosis is usually unwarranted in the emergency setting with grossly inflamed tissues.

Conclusion

Spontaneous bile duct perforation leading to biliary peritonitis is an uncommon diagnosis in the setting of chronic pancreatitis, but this differential should be sought when a case of suspected acute on chronic pancreatitis has diffuse peritonitis with bile in a diagnostic paracentesis. MRCP and biliary scintigraphy aid in preoperative diagnosis. Early diagnosis and management is must owing to its high mortality and morbidity.

References

1. Khanna R, Agarwal N, Singh AK, Khanna S, Basu SP (2010) Spontaneous common bile duct perforation presenting as acute abdomen. *Indian J Surg* 72(5):407-408.
2. Vijungco J, Prinz R (2003) management of biliary and duodenal complications of chronic pancreatitis. *World J Surg* 27:1258-1270.
3. Kumar A, Kataria R, Chattopadhyay TK, Karak PK, Tandon RK (1992) Biliary peritonitis secondary to perforation of common bile duct: An unusual presentation of chronic calcific pancreatitis. *Post grad Med J* 68(804):837-9.
4. Kang Sung-Bum, Han Ho-Seong, Seog Ki Min, Kook Lee Hyeon (2004) Nontraumatic perforation of the bile duct in adults. *Arch Surg* 10:1083-7.
5. Shenoy V, Jawale S (2001) Anomalous pancreaticobiliary union and chronic pancreatitis: Rare presentation with biliary peritonitis. *Pediatr Surg Int* 17:549-551.
6. Hamura R, Haruki K, Tsutsumi J, Takayama S, Shiba H, et al (2016) Spontaneous biliary peritonitis with common bile duct stones: Report of a case. *Surg Case Rep* 2(1):103.
7. Barrett HB, Narkewicz MR, Ronald SJ (2006) Spontaneous Perforation of the Bile Duct in a Toddler: The Role of Endoscopic Retrograde Cholangiopancreatography in Diagnosis and Therapy. *J Pediatr Gastroenterol Nutr* 43(5):695-697.