

## Prophylactic Use of Fentanyl Buccal Tablets for Predictable Breakthrough Pain: A Case Report

Iwao Osaka\*, Shigeki Ono, Akinori Aikawa, Akira Kimura, Yoshie Shizusawa and Isamu Adachi

Division of Palliative Medicine, Shizuoka Cancer Center Hospital, Japan

\*Corresponding author: Iwao Osaka, Division of Palliative Medicine, Shizuoka Cancer Center Hospital, 1007 Shimonagakubo, Nagaizumicho, Sunto-gun, Shizuoka, 411-8777 Japan, Tel: +81-55-989-5222; E-mail: [i.osaka@schr.jp](mailto:i.osaka@schr.jp)

Received date: Sep 01, 2014, Accepted date: Sep 22, 2014, Published date: Sep 30, 2014

Copyright: © 2014 Osaka I, et al. This is an open-access article distributed under the terms of the Creative Commons Attribution License, which permits unrestricted use, distribution, and reproduction in any medium, provided the original author and source are credited.

### Abstract

Short acting opioids, such as morphine, are recommended for the management of predictable breakthrough pain in cancer patients. However, it has been reported that prophylactic fentanyl rescue medication, which is more effective and has a shorter duration of action, is more suitable for some patients depending on their symptoms and the characteristics of their breakthrough pain. Herein, we report the case of a 68-year-old man with prostate cancer who received high-quality analgesic treatment by prophylactic administration of fentanyl buccal tablets before meals. It is hoped that fentanyl rescue medication can be used as a prophylactic for predictable breakthrough pain in other cancer patients.

**Keywords:** Breakthrough cancer pain; Fentanyl buccal tablet; prophylactic rescue dose

### Introduction

Pain is the biggest problem for cancer patients. Recently, the frequency and characteristics of breakthrough cancer pain has been focused on, and breakthrough pain therapeutic approaches have increasingly been reported [1]. Breakthrough pain affects not only a patient's general condition but also their quality of life (QOL) [2,3]. The management of breakthrough pain is a key component of expensive cancer pain treatment.

It has been suggested that fentanyl rescue medication, with a prompt pharmacological effect and shorter duration of action, is an ideal rescue medication for breakthrough pain [3]. Fentanyl buccal tablets (FBT) and fentanyl sublingual tablets have recently been introduced in Japan, and their efficacy has been documented [4,5]. Furthermore, the safety and efficacy of fentanyl has been investigated in a clinical study conducted in Japan [6]. However, the use of fentanyl rescue medication for breakthrough pain treatment still requires investigation in Japan, and it can be anticipated that this validation will take some time.

Some forms of breakthrough pain are predictable, such as that experienced when eating or moving, and in general, this breakthrough pain is treated with prophylactic administration of rescue doses of medication. To date, there are no reports on the use of fentanyl rescue medication in patients with breakthrough cancer pain. Herein, we report that the prophylactic administration of FBT before meals can provide high-quality treatment for breakthrough pain.

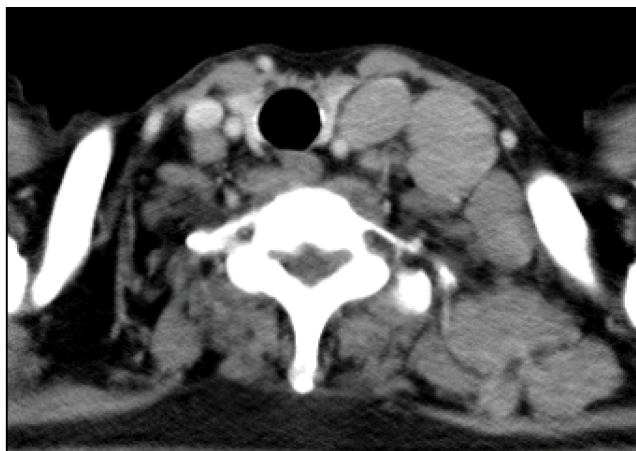
### Case Report

The patient was a 68-year-old man who was diagnosed with prostate cancer by a local physician in 2008. The patient had metastases to the para-aortic lymph nodes and obturator lymph nodes, and multiple bones. He underwent treatment using lutenizing

hormone-releasing hormone analogues, and was subsequently administered estramustine phosphate sodium hydrate. In 2010, the patient was referred to our hospital. In 2011, he underwent radiotherapy for bone metastases to the thoracic vertebrae and the left sacroiliac joint. In 2013, he underwent radiotherapy for metastases to the right scapula, but significant progression of multiple bone metastases was observed. The patient was referred to the outpatient department of the hospital in July due to low back pain and bilateral thigh pain. He received radiotherapy for metastases to the thoracic vertebrae and both femora, and was followed-up at the outpatient department. However, he was admitted to the Palliative Care Unit four months later because of uncontrolled pain in the left shoulder.

The patient had a poor functional status upon admission. His Palliative Performance Scale [7] was 40% (ambulation: mainly in bed; activity level: unable to do any work; self-care: mainly assistance; intake: normal; level of consciousness: full), and his Palliative Prognostic Index [8] score was 2.5 because there were no edema, dyspnea at rest, or delirium. A computed tomography scan indicated significant progression of multiple metastases to the lymph nodes; including the cervical (Figure 1), supraclavicular, axillary, para-aortic, and the pelvic region.

Upon hospitalization, the patient was administered loxoprofen sodium hydrate 60 mg 3 times a day and morphine sulfate hydrate 30 mg at fixed times every day. However, due to severe pain in the left shoulder, the morphine capsule was changed to a morphine injection, and the dose was increased to 36 mg/day by titration. Once the patient's pain at rest had decreased to a Numeric Rating Scale (NRS) of 1-2, the route of administration was again changed and extended-release morphine sulfate hydrate 60 mg/day was administered.



**Figure 1:** Computed tomography (CT) scan indicating significant progression of multiple metastases to the lymph nodes.

The patient's pain at rest was relieved, but NRS 7 breakthrough pain developed when his bed was upright during meals. The patient was administered a single dose of immediate-release morphine hydrochloride hydrate before meals, and the prophylactic rescue dose was increased from 10 mg to 20 mg. However, the patient continued to experience NRS 5 pain and his drowsiness was exacerbated. In order to alleviate this drowsiness, his rescue dose was switched to a 50 µg FBT, a comparatively short acting drug, 15 minutes before meals. This switching of intervention enabled him to have meals at the upright position without any pain. In consideration of meal times, FBT was administered at 4 hourly intervals at 7:30 am, 11:30 am, and 5:30 pm, without any problem. Immediate-release morphine hydrochloride hydrate was administered as a prophylactic rescue dose for the management of unpredictable breakthrough pain, and before going to the bathroom or undergoing laboratory tests.

The patient was satisfied, reporting that "It is more effective than morphine" and "I enjoy meals". When radiotherapy was performed to control the pain caused by metastases to the left cervical lymph nodes and supraclavicular nodes, breakthrough pain during meals disappeared and FBT administration was terminated. No adverse event was observed during the use of FBTs.

## Discussion

The patient received high-quality analgesia by prophylactic administration of fentanyl rescue medication before meals. He complained of increased pain due to cervical lymph node metastases when the bed was in an upright position during meals. Since pain was eventually relieved by radiotherapy for the cervical lymph node metastases, it is suggested that the pain experienced on movement was caused by the lymph node swelling rather than bone metastases. An FBT as a rescue medication was effective in this case because it has a rapid onset of action and was administered before moving the bed to an upright position. Furthermore, the lowest dose of a FBT, 50 µg, in Japan, might provide effective analgesia without causing drowsiness. It has been reported that there is no correlation between a fixed scheduled opioid regimen and the required rescue dose [9]. In this case, the patient was administered 60 mg/day of extended-release morphine sulfate hydrate at fixed intervals, and a 50 µg FBT was more

effective as a rescue dose than 20 mg of immediate-release morphine hydrochloride hydrate. Thus, titration of the rescue dose is critical, and the optimal dose should be adjusted on each patient basis.

It is currently unclear whether prophylactic or preemptive administration of rescue medication for predictable breakthrough pain is safe and effective. The European Association for Palliative Care guidelines recommends preemptive immediate-release formulations of opioids for predictable episodes of breakthrough pain. There are no detailed descriptions of the use of rapid onset fentanyl formulations in these guidelines [10]. However, enhanced high-quality analgesic effects may well be achieved by the administration of an FBT for breakthrough pain that is associated with a regular-interval action, such as eating. Indeed, French guidelines only recommend transmucosal fentanyl for the management of induced procedural pain in patients already receiving an opioid for chronic pain [11]. Prophylactic administration of FBT may be considered as one of the possible treatment options for breakthrough pain in specific patients who are selected using appropriate criteria.

However, the analgesic treatment used in this case did have some limitations. The treatment required a combination of two different opioid formulations for rescue medication, which indicates that this method should only be given to patients under vigilance with good adherence. Furthermore, the treatment may only be available in an inpatient setting, and caution would be required before recommending this treatment for home-based care. Economic issues should also be considered because an FBT is approximately 14% more expensive per rescue dose than an available formulation of short acting morphine in Japan. The long-term efficacy and safety of fentanyl rescue medication have been reported using oral transmucosal fentanyl citrate [12], which may also be applicable to FBT. For the reasons previously mentioned, appropriate rescue medication should be selected depending upon the procedures for breakthrough pain, in particular, body movement, eating, excretion, or travelling.

A prospective study or a head-to-head comparative study between fentanyl and other rescue medications should be performed in order to determine whether prophylactic administration fentanyl is appropriate for standard medical practice [13]. If the efficacy and safety of rapid onset fentanyl formulations is established, a tailor-made treatment for breakthrough pain can be provided, which will improve patient's QOL.

## Conclusion

Preventive rescue medication are rarely considered or discussed in cancer patients. This case report suggested that prophylactic administration of a fentanyl buccal tablet is likely to play a key role in the rescue medication for predictable breakthrough cancer pain.

## References

1. Davies A, Buchanan A, Zeppetella G, Porta-Sales J, Likar R, et al. (2013) Breakthrough cancer pain: an observational study of 1000 European oncology patients. *J Pain Symptom Manage* 46: 619-628.
2. Green CR, Montague L, Hart-Johnson TA (2009) Consistent and breakthrough pain in diverse advanced cancer patients: a longitudinal examination. *J Pain Symptom Manage* 37: 831-847.
3. Zeppetella G, Davies AN. Opioids for the management of breakthrough pain in cancer patients. *Cochrane Database Syst Rev* 2013; 10: CD004311.

4. Portenoy RK, Taylor D, Messina J, Tremmel L (2006) A randomized, placebo-controlled study of fentanyl buccal tablet for breakthrough pain in opioid-treated patients with cancer. *Clin J Pain* 22: 805-811.
5. Rauck RL, Tark M, Reyes E, Hayes TG, Bartkowiak AJ, et al. (2009) Efficacy and long-term tolerability of sublingual fentanyl orally disintegrating tablet in the treatment of breakthrough cancer pain. *Curr Med Res Opin* 25: 2877-2885.
6. Kosugi T, Hamada S, Takigawa C, Shinozaki K, Kunikane H, et al. (2014) A randomized, double-blind, placebo-controlled study of fentanyl buccal tablets for breakthrough pain: efficacy and safety in Japanese cancer patients. *J Pain Symptom Manage* 47: 990-1000.
7. Anderson F, Downing GM, Hill J, Casorso L, Lerch N (1996) Palliative performance scale (PPS): a new tool. *J Palliat Care* 12: 5-11.
8. Morita T, Tsunoda J, Inoue S, Chihara S (1999) The Palliative Prognostic Index: a scoring system for survival prediction of terminally ill cancer patients. *Support Care Cancer* 7: 128-133.
9. Coluzzi PH, Schwartzberg L, Conroy JD, Charapata S, Gay M, et al. (2001) Breakthrough cancer pain: a randomized trial comparing oral transmucosal fentanyl citrate (OTFC) and morphine sulfate immediate release (MSIR). *Pain* 91: 123-130.
10. Caraceni A, Hanks G, Kaasa S, Bennett MI, Brunelli C, et al. (2012) Use of opioid analgesics in the treatment of cancer pain: evidence-based recommendations from the EAPC. *Lancet Oncol* 13: e58-68.
11. Poulain P, Michenot N, Ammar D, et al. Mise au point sur l'utilisation du fentanyl transmuqueux: chez le patient présentant des douleurs d'origine cancéreuse. *Douleurs* 2012; 13: 34-39.
12. Payne R, Coluzzi P, Hart L, Simmonds M, Lyss A, et al. (2001) Long-term safety of oral transmucosal fentanyl citrate for breakthrough cancer pain. *J Pain Symptom Manage* 22: 575-583.
13. Caraceni A, Davies A, Poulain P, Cortés-Funes H, Panchal SJ, et al. (2013) Guidelines for the management of breakthrough pain in patients with cancer. *J Natl Compr Canc Netw* 11 Suppl 1: S29-36.