

Promising Effect of Treatment at Early Adolescent Age: A Case Report

Seema Kapil Lahoti^{1*}, Kapil B Lahoti², Varunjeet Chaudhary¹ and Rajeshwar Singh³

¹MDS in Orthodontics, RKDF Dental College, Bhopal, Madhya Pradesh, India

²MDS in Oral and Maxillofacial Surgery, Bhabha Dental College, Bhopal, Madhya Pradesh, India

³MDS in Orthodontics, RR Dental College and Hospital, Udaipur, Rajasthan, India

Abstract

Aim of this study was to see the effect of bionator in early permanent dentition phase. Bionator from its inception and evolution of the appliance itself has been widely accepted as a more competent class II corrector. The bionator has both dentalveolar and skeletal effect. This appliance can be used successfully in growing patient with certain class II malocclusion. It also simplifies the fixed appliance phase. An 11-year-old boy was treated with bionator appliance and treatment results were demonstrated in following case report. In permanent dentition, bionator produce similar effect as in mixed dentition phase. With proper case selection and good patient cooperation, we can obtain a significant result with bionator appliance.

Introduction

Very common skeletal problem in orthodontics is the class II malocclusion due to mandibular retrognathism [1,2]. Class II division 1 malocclusion if associated with a retrognathic mandible in growing phase, the best treatment option is the alteration of the amount and direction of mandibular growth by using functional appliances [3]. However, the effects and stability of early class II treatment with functional appliances have been surrounded by much controversy and uncertainty [4].

Multiple factor which influences the stability of early class II treatment includes mandibular growth patterns [5], airway obstructions [6], manipulation of appliances, treatment timing [7] and retention [8]. Among these, bionator is one of the tooth-borne appliances that have been reported to produce significant changes in the dental and skeletal facial structures through a repositioning of the mandible in a more protrusive position, overbite correction, dental eruption modification, and improvement of the profile [2,9]. The large number of studies including randomized clinical trials on one-phase vs. two-phase treatment have investigated the mechanism of action and the effects of bionator appliance in class II division 1 malocclusion [2,8-11].

The present case study shows the correction of class II division 1 malocclusion with bionator to assess the treatment outcome of tooth-borne functional appliances and its stability over the time.

Case Report

A 13.2-year-old male patient reported 23 months back, with the chief complaint of forwardly placed upper front teeth. Extra-Oral Examination revealed an apparently symmetrical mesoprosopic face, potentially competent lips. He had convex facial profile and posterior divergence with positive VTO. Decreased nasolabial angle and hyperactive buccinator muscle. His smile was non-consonant type with 50% upper incisors and some amount of lower incisors visible (Figure 1).

Examination

Intra-Oral Examination showed all early permanent teeth except third molars. Periodontium was healthy with melanin pigmentation of attached gingiva. Upper incisors were proclined with mild spacing in upper and lower anterior teeth. Overjet and overbite was increased. He had class II molar and canine relation bilaterally. Dental midline was coinciding with facial midline. Functional examination showed the path of closure of mandible was normal without any deviation and there

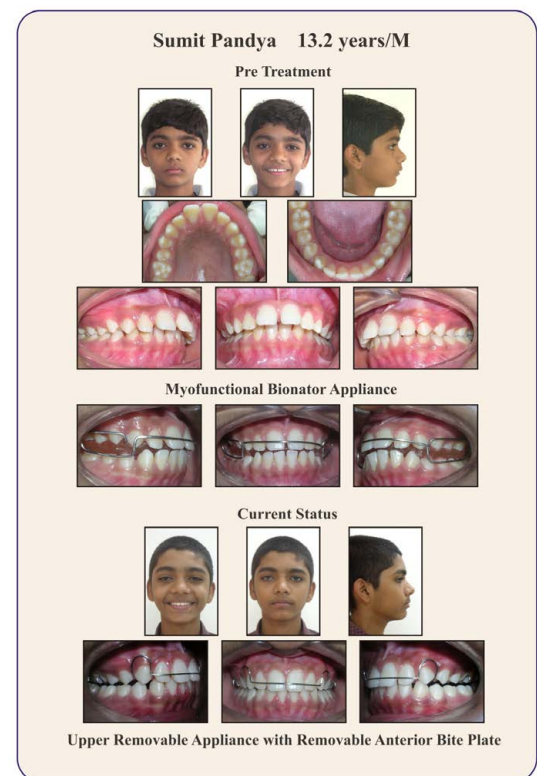


Figure 1: Shows pretreatment and the current status of the patient after myofunctional appliance therapy.

***Corresponding author:** Lahoti SP, MDS in Orthodontics, Hospital and Research Centre, RKDF Dental College, Sector A/14, Shahpura, Bhopal, Madhya Pradesh, India. Tel: 09406910100; 07554229756; E-mail: sims_kaps_26@yahoo.co.in

Received January 22, 2017; **Accepted** February 28, 2017; **Published** March 09, 2017

Citation: Lahoti SK, Lahoti KB, Chaudhary V, Singh R (2017) Promising Effect of Treatment at Early Adolescent Age: A Case Report. *Pediatr Dent Care* 2: 130. doi: [10.4172/2573-444X.1000130](https://doi.org/10.4172/2573-444X.1000130)

Copyright: © 2017 Lahoti SK, et al. This is an open-access article distributed under the terms of the Creative Commons Attribution License, which permits unrestricted use, distribution, and reproduction in any medium, provided the original author and source are credited.

were no other associated signs or symptoms of tempero-mandibular disorders. Mentalis and buccinator muscle were hyperactive with hypotonic upper lip.

Cephalometric examination revealed that patient was in CVMI stage II and had class II skeletal bases due to retrognathic mandible with average growth pattern. Maxillary incisors were proclined. The soft tissue analysis showed significantly protrusive upper and lower lips in relation to E line with decreased nasolabial angle.

Treatment Plan

Standard Bionator appliance was used for correction of skeletal class II malocclusion followed by fixed mechanotherapy for settling and detailing of occlusion if required. Objectives to be achieved were Profile improvement, correction of upper anterior teeth proclination and class I molar and class I canine relationship with skeletal class I bases.

Treatment was carried out with standard bionator myofunctional appliance for the correction of mandible. After initial un-cooperation by the patient treatment continued for 18 months with improved facial profile, normal nasolabial angle, reduced proclination of upper anterior teeth and class I molar and canine relationship. Skeletal class I bases achieved. Now the patient is in retention phase with night time bionator and anterior bite plate for correction of minute deep bite in day time.

Conclusion

The present case show that growing class II malocclusion can be managed with a very simple and one of the oldest myofunctional appliance bionator without the fixed orthodontic treatment at an early age and without exaggerating the problem to develop to a stage where

its correction and stabilization will be more difficult. The simplicity of treatment and its emphasis on the management of the occlusion is noteworthy, which can be easily done by a general dentist/pedodontist. Patient motivation and co-operation is the only issue which can be resolved by telling and showing the treatment effects to the patient.

References

1. Riolo ML, Avery JK (2003) *Essentials for Orthodontic Practice*. Ann Arbor, Mich: EFOP Press pp 170-173.
2. Baccetti T, Franchi L, McNamara JA Jr, Tollaro I (1997) Early dentofacial features of Class II malocclusion: a longitudinal study from the deciduous through the mixed dentition. *Am J Orthod* 111: 502-509.
3. McNamara JA Jr, Brudon WL (2001) *Orthodontics and Dentofacial Orthopedics*. Ann Arbor, Mich: Needham Press, MI, USA Inc pp: 63-73.
4. McNamara JA Jr, Carlson DS (1979) Quantitative analysis of temporomandibular joint adaptations to protrusive function. *Am J Orthod* 76: 593-611.
5. Bjork A (1969) Prediction of mandibular growth rotation. *Am J Orthod* 55: 585-599.
6. Linder-Aronson S, Woodside DG, Lundstrom A (1986) Mandibular growth direction following adenoidectomy. *Am J Orthod Dentofacial Orthop* 89: 273-284.
7. Baccetti T, Franchi L, Toth LR, McNamara JA Jr (2000) Treatment timing for Twin Block therapy. *Am J Orthod Dentofacial Orthop* 118: 159-170.
8. Pancherz H ((1991)) The nature of Class II relapse after Herbst appliance treatment: a cephalometric long-term investigation. *Am J Orthod Dentofacial Orthop* 100: 220-233.
9. McNamara JA Jr (1981) Components of Class II malocclusion in children 8-10 years of age. *Angle Orthod* 51: 171-202.
10. Moyers RE, Riolo ML, Guire KE, Wainright RL, Bookstein FL (1980) Differential diagnosis of Class II malocclusions. Part 1. Facial types associated with Class II malocclusions. *Am J Orthod* 78: 477-494.
11. Charlier JP, Petrovic A, Stutzmann J (1969) Effects of mandibular hyperpropulsion on the prechondroblastic zone of young rat condyle. *Am J Orthod* 55: 71-74.