

## Prognostic Factors in Onychomycosis Treatment

Shari R Lipner\* and Richard K Scher

Weill Cornell Medical College Dermatology, New York, USA

\*Corresponding author: Shari Lipner, Dermatology, Weill Cornell Medical College Dermatology, Cornell Dermatology Consultant, 1305 York Ave, New York, NY 10021, Tel: 646-962-3376; E-mail: [shl9032@med.cornell.edu](mailto:shl9032@med.cornell.edu)

Rec date: Nov 06, 2014; Acc date: Jan 26, 2015; Pub date: Feb 05, 2015

Copyright: © 2015 Lipner SR, et al. This is an open-access article distributed under the terms of the Creative Commons Attribution License, which permits unrestricted use, distribution, and reproduction in any medium, provided the original author and source are credited.

### Abstract

Onychomycosis is a common fungal disease of the nail unit with a prevalence of 10% to 12% in the United States. Despite therapeutic innovations in the last few decades, as many as 20-25% of patients do not achieve a complete cure, and 10-53% are reported to relapse after successful treatment. Some of the factors associated with a poor response to onychomycosis have been well studied. They include patient characteristics and morbidities, nail characteristics, and the infecting organism. Therefore, the goal of therapy is to identify these specific prognostic features for each patient and devise an appropriate treatment plan that will allow for the best chance for cure. Scoring systems may be helpful for grading the severity of onychomycosis and predicting the therapeutic outcome.

**Keywords:** Nondermatophyte; Hyperkeratosis; Carcinoma

### Introduction

Onychomycosis is a fungal infection of the nail unit caused by dermatophytes, yeasts, and nondermatophyte molds. It is a common disease, with a prevalence of 10% to 12% in the United States [1,2]. It may cause both physical and psychological problems, as some patients have pain, difficulty wearing shoes, secondary infection, and problems performing everyday functions due to the resulting nail dystrophy or unacceptable cosmetic appearance. The treatment objective is to eradicate the fungus and produce a normal nail. The therapeutic innovations both in the 1990's and this past year have led to superior efficacy, more rapid treatment courses and fewer drug-drug interactions. However, despite these improvements, at the present time all patients do not achieve a complete cure. In fact, about 20-25% of patients will not respond to treatment [3]. Furthermore, even when a complete cure is achieved, relapse rates are high, with reports in the literature of 10-53% [4]. Since some of the factors that are associated with treatment failures are known, it would be desirable to have an individualized treatment plan for each patient based on these known prognostic factors that could help the patient achieve a complete cure.

### Diagnosis of Onychomycosis

While there are certain features that may predict a poor response to treatment for onychomycosis, the first step in evaluating every patient is to make the correct diagnosis. Clinically, onychomycosis is characterized by hyperkeratosis of the nail bed, which may lead to distal detachment of the nail plate from the nail bed, known as onycholysis. There is often subungual debris and a white or yellow discoloration of the nail plate. *Tinea pedis*, which presents with scale in the web spaces and plantar feet, is a common associated finding. Although not specific for onychomycosis, the nail may be dystrophic with thickening, crumbling, ridging, as well as partial nail loss. While onychomycosis accounts for 50% of nail diseases [5], other nail conditions may present in a similar fashion, including trauma, bacterial infections such as *Pseudomonas aeruginosa* and *Proteus mirabilis*, and inflammatory skin diseases like lichen planus and

psoriasis. Malignant neoplasms, squamous cell carcinoma or rarely amelanotic melanoma, are also considerations. In addition, exostoses, warts and benign neoplasms such as onychomatricoma can also present similarly. Exogenous substances such as nail polish or self-tanning creams may also result in yellow or brown staining of the nail plate [6,7]. Finally, systemic medications, including chemotherapeutic agents, tetracycline derivatives plus sunlight, and oral retinoids, such as acitretin and isotretinoin may result in nail changes that have features similar to onychomycosis [8].

Since other nail conditions may resemble onychomycosis clinically, it is imperative to make a proper laboratory diagnosis before initiating treatment. This practice will avoid the consequences of treating inappropriately or missing the diagnosis of other nail disorders and their associated morbidity (i.e. psoriasis, neoplasm). Diagnosis can be made using direct microscopy and a potassium hydroxide (KOH) agent to identify fungal hyphae [9]. Fungal culture is considered the gold standard for the diagnosis of onychomycosis, and is the only technique to date that can be used to identify both the causative organism and viability. Onychomycosis may also be diagnosed using a periodic acid-Schiff stain on nail clippings, which is more sensitive than KOH and culture, but the causative pathogen and viability can not be established [10].

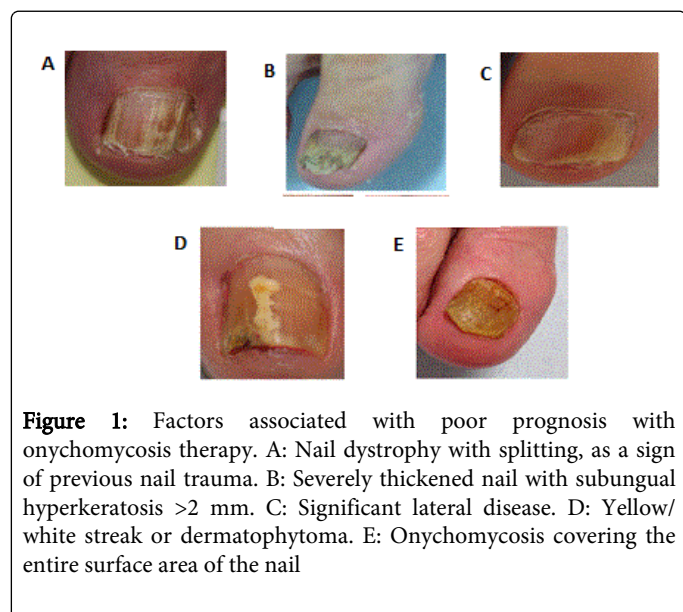
### Poor Prognostic Factors for Onychomycosis

Characteristics that are associated with poor response to onychomycosis therapy can be divided into three categories, namely, patient characteristics and morbidities, nail features, and type of infecting organism. These are shown in Table 1 [11-17]. Patient characteristics include older age, prior trauma to the affected nail, and previous history of onychomycosis; patient morbidities include immunosuppression, poor peripheral circulation, and uncontrolled diabetes mellitus. Nail features include thickened nails (subungual hyperkeratosis >2mm), significant lateral disease, a longitudinal streak or patch (dermatophytoma), large surface area of nail involved (>50%), slowly growing nails, great toenail involved as opposed to other digits, severe separation of nail plate from nail bed (onycholysis), paronychia, melanonychia, matrix involvement, and total dystrophic

onychomycosis. Organisms that respond poorly to treatment are nondermatophyte molds, yeasts, and mixed bacterial and fungal infections. Examples of these features are shown in Figure 1.

Patient Characteristics and Morbidities	Nail Features	Organism
Older age	Subungual hyperkeratosis > 2mm	Mixed bacterial and fungal infections
Previous nail trauma	Significant lateral disease	Yeasts
History of onychomycosis	Dermatophytoma	Nondermatophyte molds
Immunosuppression (due to medication or disease)	Nail plate involvement >50%	
Peripheral vascular disease	Slowly growing nails	
Uncontrolled diabetes mellitus	Hallux involvement	
	Severe onycholysis	
	Paronychia	
	Melanonychia	
	Matrix involvement	
	Total dystrophic onychomycosis	

**Table 1:** Factors associated with poor prognosis with onychomycosis therapy.



### Patient Characteristics and Morbidities

Older age has been shown to be highly associated with low cure rates [3,18]. The elderly often have poor circulation, reduced nail growth rates, as well as a higher frequency of nondermatophytes, which may contribute to their lack of response to therapy. For example, in a large study of 90,085 subjects from 16 European countries, *Trichophyton rubrum* was the most common isolate from nails in all age groups, but *Aspergillus spp.*, *Scopulariopsis brevicaulis* and *Candida spp.* were cultured more frequently in older individuals. Additionally, the frequency of mixed fungal growths also increased with age [19]. Trauma to the nail unit may produce irreversible

damage, which may predispose patients to onychomycosis. In a study of 15,000 patients, those who had abnormally appearing nails and positive mycology had a risk-odds ratio of 5.4 (95% CI, 4.0-7.4, P<.0001) [20]. While trauma has been also cited as a sign of poor prognosis [12,15], there have been no large-scale studies evaluating the association of trauma with response to treatment.

It has been shown that patients with a history of onychomycosis are less likely to achieve cure compared to patients who have the infection for the first time [17]. While this needs formal study, possible explanations for this finding are that patients were not fully cured by the first treatment, genetic predisposition, or other confounding factors like nail psoriasis or lichen planus.

Immunosuppressed patients, such as those with HIV infection, may be more likely to develop onychomycosis especially when their helper T-lymphocyte (CD4) count is below 400/mm<sup>3</sup> [21]. While the clinical presentation and infecting organisms are the same as in normal individuals, in HIV, onychomycosis may be more severe and more likely to involve all the fingernails and toenails. In addition, HIV positive individuals may have a dermatophyte infection of the periungual region and "one hand two feet" syndrome more commonly [22].

Peripheral vascular disease is also a poor prognostic sign for good therapeutic outcomes. Chronic venous disease may cause varicose veins, lower extremity pain and edema as well as venous skin changes and ulceration. It may also cause nail plate dystrophy similar to that seen in onychomycosis [23,24]. Nails may also be thickened, discolored, and have a hyperplastic nail bed; onychogryphosis is also common. Onychomycosis and nail changes due to venous disease often coexist [23,25]. In a study of patients with both venous disease and onychomycosis who were treated with itraconazole, only a 25% cure rate was achieved, compared with the 60% to 70% cure rate commonly cited in the literature [25].

Onychomycosis affects approximately one third of patients with diabetes and may increase the severity of foot disorders such as nonhealing ulcers and secondary infections [26]. The severity of onychomycosis is significantly associated with the length of time that the individual has diabetes [27]. Studies have shown that while the cure rate is not statistically different between diabetic and non-diabetic patients [28,29], recurrence rate and duration required for complete cure are higher [28].

### Nail Features

Subungual hyperkeratosis is defined as a thickening of the stratum corneum and is a reaction to the fungal infection. It may be measured using a ruler or calipers from the nail bed to the nail plate. Although, this feature has been cited as a poor prognostic sign, to date there is no statistical support [12,13,15-17]. It is thought that this thick debris is a barrier to both topical and systemic therapies. It has been suggested that mechanical debridement of the nail unit using a curette, clippers, or partial chemical avulsion be used to reduce the fungal load and may be an adjunct to topical or oral drugs [30].

Many authors have cited significant lateral disease as a poor prognostic sign for onychomycosis therapy [3,17,31,32]. When the nail plate is tightly bound to the underlying nail bed, systemic antifungals normally reach the nail plate via rapid diffusion across the nail bed [33-35]. In a study of 18 patients who were treated with a course of oral terbinafine or itraconazole for onychomycosis, in the 5 nonresponders, there was involvement of the lateral edge of the nail plate. The authors hypothesized that there was poor penetration of the drug to the lateral nail plate, based on the histological evidence that there is poor adhesion of the lateral edge of the nail to the lateral nail groove. Interestingly, to test this hypothesis, the two authors each took 400 mg of itraconazole for 1 week and then measured the concentration of drug in the distal and lateral parts of the nail plate. They found that the concentration of the antifungal drug in the lateral edge was roughly two thirds of that in the distal nail, and concluded that this finding supports the premise that significant lateral disease portends a poor prognosis [31]. While compelling, this finding would have to be validated in a larger study to have statistical significance.

A dermatophytoma is a white, yellow or orange longitudinal streak or patch in the nail plate seen clinically, and a collection of densely packed thick walled fungal hyphae when seen on histological examination. A dermatophytoma streak differs from onycholysis, in that it extends from the free edge of the nail to the proximal part of the nail. A patch is a round area that is not contiguous with the free edge of the nail. This clinical finding has important prognostic value, as it is unlikely for even systemic antifungals to penetrate this fungal mass [14,32]. For example, in one study, patients with the presence of a dermatophytoma who were treated with oral terbinafine were less likely to achieve a mycological cure than patients without it [17]. It should be noted that in another study, the authors did not find an association of dermatophytoma with lower cure rate [36]. However drawing conclusions from this study is questionable since the sample size was quite small.

Numerous reports have demonstrated that when a greater surface area of nail plate is affected by onychomycosis, lower cure rates will be achieved [15,18,28,37]. The area of involvement is defined as the percentage of affected onychomycotic nail and is measured using the boundaries of the lateral nail folds, proximal nail fold, and distal nail groove [11]. This finding of lower cure rates is likely due to the greater fungal load that is associated with more surface area of nail affected. It

may also be due to the slower growth rate of the nail plate when a large portion of the nail is affected. In fact, in a study of 49 patients with onychomycosis affecting either more or less than 50% of the nail plate, the authors found a slower growth rate when the affected area occupied more than half of the total nail plate [38].

Evidence supports the observation that faster nail growth leads to better treatment outcomes [32,39,40]. For example, a study was done on 199 patients with onychomycosis who were treated with continuous terbinafine vs. intermittent terbinafine who were then recruited for additional observation. Those patients with faster nail growth were more likely to achieve cure [17]. It is believed that with faster nail growth, the onychomycotic portion of the nail plate is shed more quickly, leading to a better cure rate. Faster nail growth rates may also partially explain the finding that children are less likely to have onychomycosis compared to adults [41]. It should be noted other studies have not confirmed the finding that faster nail growth is associated with better cure rates. For example, in a smaller study of 49 patients with onychomycosis, the authors found that when onychomycosis affected more than half of the total nail plate, the nail growth rate was slower than that of nonaffected toenails. However when the nail was cured there was no slowing of nail growth compared to the unaffected nail with a history of onychomycosis [38]. In addition, in another study it was found that the mean rate of linear nail growth in 30 patients with a history of onychomycosis was not significantly different from that of the control patients [42]. In yet another small study of 35 patients treated with terbinafine for 12 weeks who were then followed for 48 weeks, slow linear nail growth did not influence treatment outcomes [36].

Several other nail features have been cited as portending a poor prognosis with onychomycosis therapy. For example, involvement of the great toenail as opposed to the other digits may lead to a lower cure rate [12,16]. While most onychomycosis studies focus on the great toenail, Shemer et al. [25], found that there was a statistically significant difference in complete cure rates between the great toenail (23%), as compared to the second (65%), third (51%) and the fourth toenails (67%) [43]. This may be partially attributed to the fact that the hallux is more prone to external trauma [15,44,45] and thus more likely to be infected compared to healthy, non-deformed, toenails [46]. In addition, nail dystrophy may reduce penetration of the drug into its target. Severe onycholysis has been suggested as a poor prognostic sign for onychomycosis treatment [12,15]. When this detachment is present, there is poor uptake of the oral antifungal into the nail plate from the underlying bed. It has been proposed that the combination of oral and topical agents, or systemic treatment with partial nail avulsion is necessary to cure onychomycosis in these cases [13]. Paronychia, an infection around the nail fold, and melanonychia, defined as a black discoloration of the nail plate may predict a poor response to treatment [12]. Another poor prognostic sign is onychomycosis involving the matrix [17,47]. It is hypothesized that involvement of the nail matrix may affect nail growth or that drug absorption may be impaired in this region. Another poor prognostic sign is total dystrophic onychomycosis [15]. Total dystrophic onychomycosis is the end stage of onychomycosis, in which the nail plate crumbles and the nail bed is thickened and ridged with involvement of the nail matrix [46].

### Organisms

When onychomycosis is present concurrently with a bacterial infection or viral infection, antifungal therapy alone may not lead to

cure. It has been suggested that the bacterial infection e.g. Pseudomonas or viral infection e.g. herpes should be treated first followed by appropriate antifungal therapy for the onychomycosis [13,48].

Candida onychomycosis may also portend a poor prognosis [15]. This may be due to the fact that this type of onychomycosis may be associated with immunosuppression. For example, onychomycosis is a characteristic feature of patients with chronic mucocutaneous candidiasis (CMC), who have poor cell-mediated immunity [49,50]. In addition, in a study of 500 HIV-positive patients from North and South America, the prevalence of onychomycosis was 23.2% with causative organisms identified as dermatophytes and Candida species [51]. Furthermore, candida nail infections may be more common when host immunity is suppressed such as in congenital or acquired ectodermal defects, and endocrine disorders including hypothyroidism, hypoparathyroidism, hypoadrenalism and diabetes mellitus [52].

Nondermatophyte molds (NDMs) are a relatively rare cause of onychomycosis accounting for approximately 10% of cases worldwide,

with the majority being caused by dermatophytes and yeasts [53]. The most common NDM isolates in descending order are Scopulariopsis brevicaulis, Fusarium species, Aspergillus species, Scytalidium dimidiatum, and Acremonium species [54]. Onychomycosis associated with NDM has been associated with a poor prognosis [15]. This may be due to the difficulty in diagnosing NDM infections, as they may be innocuous contaminants of the feet and nails or laboratory contaminants. In addition, since they are a relatively uncommon cause of nail infections, there is a paucity of data on treatment regimens [54].

### Scoring Systems Used to Predict Prognosis

Scoring systems for onychomycosis have been developed to help physicians choose appropriate therapy and predict treatment outcomes. These systems have incorporated a subset of the factors associated with poor prognosis that are listed in Table I with various weights given to each factor. Three scoring systems have been devised to date and are compared in Table 2.

Scoring Clinical Index for Onychomycosis	Severity Index by Baran, et al. [12]	Onychomycosis Severity Index
Depth of involvement (d)	Extent of involvement	Area of involvement
Degree of hyperkeratosis (h)	Diffuse nail plate thickening	Subungual hyperkeratosis > 2mm
Clinical form (distal-lateral subungual, proximal subungual, superficial white onychomycosis ) (f)	Nail plate thickening with linear streaks	Dermatophytoma
Location (fingernails 2-5, thumbnail or toenails 2-5, great toenail) (l)	Location (thumb or toenails 2-5, great toenail)	Proximity of the disease to the matrix
Age of patient (a)	Age of Patient	
	Paronychia	
	Melanonychia	
	Presence of diabetes mellitus, immunosuppression, peripheral vascular disease	
	Causative organism (Scytalidium spp., mold, yeast)	
	Onycholysis	
Final score: $[(d/3)3-f (f + h (3-f)) (l) (a + 3)/3]1-[(2-f)(3-f)/2]$ or online or downloadable calculator at <a href="http://www.onychoindex.com">http://www.onychoindex.com</a>	Final score: obtained by adding scores for individual factors	Final score: (Score for area of involvement) x (score for proximity of disease to matrix) + 10 (if dermatophytoma or subungual hyperkeratosis > 2mm)

**Table 2:** Comparison of Factors Used in Onychomycosis Scoring Systems (Similarities between scoring systems are shown on bold).

The earliest method was devised by Sergeev et al. [16], and named the Scoring Clinical Index for Onychomycosis (SCIO). It includes a “clinical index component” which takes into account the clinical form of onychomycosis, depth of involvement, and degree of hyperkeratosis, while a “growth component” includes the particular fingernail or toenail affected and the age of the patient. The growth component is meant to reflect the approximate time needed for complete outgrowth of the target nail. Each factor is given a score of 1-3 and values entered into a complex formula, which can be calculated manually or with a downloadable calculator. Using this system, scores range from 1-30, and treatment guidelines are suggested based on the final score [16]. Advantages of this system are the

incorporation of five simple prognostic factors and inclusion of the clinical form of onychomycosis. Limitations of this grading system are that other important prognostic factors are excluded, complex calculations must be performed, and that this system has not been validated.

Another scoring system derived by Baran et al. [3] (Severity Index), utilizes a total of 10 factors, some of which are included in the earlier scoring system, such as extent of nail plate involvement, nail plate thickening, location and age of the patient, as well as other factors including dermatophytoma, presence of onycholysis, paronychia, melanonychia, predisposing factors such as diabetes mellitus and



immunosuppression and the causative organism. These factors are given scores of 1-4 and then added to get a final score. A higher score is thought to predict a worse prognosis [12]. Advantages of this system are that it is the most comprehensive, taking into account many of the known prognostic factors, and that calculations are simple. Limitations of this method of analysis are that it is time consuming, in that numerous factors must be analyzed for each patient and the fact that it has not been validated.

The most recent scoring system by Carney et al. [11], is named the Onychomycosis Severity Index (OSI). This system takes into account area of involvement, proximity of the disease to the matrix, as well as the presence of a dermatophytoma or subungual hyperkeratosis. For area of involvement and proximity of disease to the matrix, 1-5 points are given depending on severity, with 0 points for no involvement (clinical cure). If a dermatophytoma is present or if there is subungual hyperkeratosis greater than 2 mm, 10 points are awarded. The final score is calculated by multiplying the scores for area of involvement and proximity of disease to the matrix, and then potentially adding points for dermatophytoma or severe hyperkeratosis. Final scores range from 0 to 35 and are broken down into mild (1-5), moderate (6-15) and severe (16-35) categories, with a clinical cure receiving a score of zero [11]. Advantages of this system are that it is relatively simple to use, has been validated, and was shown to have high statistical reliability between dermatology experts in nail diseases and dermatologists who were generalists. Limitations of this system are that analyses are limited to the one nail, other factors that are important in predicting prognosis are excluded, and it does not correlate nail disease severity with response to treatment.

## Conclusion

Antifungal drugs, due to recent improvements in the past few decades, have superior efficacy, more rapid treatment courses and fewer drug-drug interactions. However, despite these advancements, many patients fail to achieve a complete cure, and may have high relapse rates. Since many of the factors associated with a poor response to onychomycosis are known, an understanding of these features and the currently available grading systems will aid the physician in selecting the most ideal treatment plan for each patient.

## References

1. Ghannoum MA (2000) A large-scale North American study of fungal isolates from nails: the frequency of onychomycosis, fungal distribution, and antifungal susceptibility patterns. *J Am Acad Dermatol* 43(4): p. 641-8.
2. Scher RK, Rich P, Pariser D, Elewski B (2013) The epidemiology, etiology, and pathophysiology of onychomycosis. *Semin Cutan Med Surg* 32: S2-4.
3. Scher RK, Baran R (2003) Onychomycosis in clinical practice: factors contributing to recurrence. *Br J Dermatol* 149 Suppl 65: 5-9.
4. Piraccini BM1, Sisti A, Tosti A (2010) Long-term follow-up of toenail onychomycosis caused by dermatophytes after successful treatment with systemic antifungal agents. *J Am Acad Dermatol* 62: 411-414.
5. Scher RK, Daniel CR (2005) Nails diagnosis, therapy, surgery. Elsevier Saunders, Oxford. p. 1 online resource (xiv, 324 p).
6. Cockerell C, Odom R (1995) The differential diagnosis of nail disease. *AIDS Patient Care* 9 Suppl 1: S5-10.
7. Daniel CR 3rd (1991) The diagnosis of nail fungal infection. *Arch Dermatol* 127: 1566-1567.
8. Rich P, Elewski B, Scher RK, Pariser D (2013) Diagnosis, clinical implications, and complications of onychomycosis. *Semin Cutan Med Surg* 32: S5-8.
9. Mehregan DR, Gee SL (1999) The cost effectiveness of testing for onychomycosis versus empiric treatment of onychodystrophies with oral antifungal agents. *Cutis* 64: 407-410.
10. Mahoney JM, Bennet J, Olsen B (2003) The diagnosis of onychomycosis. *Dermatol Clin* 21: 463-467.
11. Carney C, Tosti A, Daniel R, Scher R, Rich P, et al. (2011) A new classification system for grading the severity of onychomycosis: Onychomycosis Severity Index. *Arch Dermatol* 147: 1277-1282.
12. Baran R, Hay RJ, Garduno JI (2008) Review of antifungal therapy and the severity index for assessing onychomycosis: part I. *J Dermatolog Treat* 19: 72-81.
13. Gupta AK, Daniel CR 3rd (1998) Factors that may affect the response of onychomycosis to oral antifungal therapy. *Australas J Dermatol* 39: 222-224.
14. Roberts DT, Evans EG (1998) Subungual dermatophytoma complicating dermatophyte onychomycosis. *Br J Dermatol* 138: 189-190.
15. Scher RK, Tavakkol A, Sigurgeirsson B, Hay RJ, Joseph WS, et al. (2007) Onychomycosis: diagnosis and definition of cure. *J Am Acad Dermatol* 56: 939-944.
16. Sergeev AY, Gupta AK, Sergeev YV (2002) The Scoring Clinical Index for Onychomycosis (SCIO index). *Skin Therapy Lett* 7 Suppl 1: 6-7.
17. Sigurgeirsson B1 (2010) Prognostic factors for cure following treatment of onychomycosis. *J Eur Acad Dermatol Venereol* 24: 679-684.
18. Kim DHP HJ, Lee JY, Cho BK (2005) Clinical study of onychomycosis: factors contributing to the prognosis and response rate according to each factor and summation of factors. *Korean Journal of Medical Mycology* 10(2): p. 55-69.
19. Piérard G (2001) Onychomycosis and other superficial fungal infections of the foot in the elderly: a pan-European survey. *Dermatology* 202: 220-224.
20. Gupta AK, Jain HC, Lynde CW, Macdonald P, Cooper EA, et al. (2000) Prevalence and epidemiology of onychomycosis in patients visiting physicians' offices: a multicenter canadian survey of 15,000 patients. *J Am Acad Dermatol* 43: 244-248.
21. Gregory N (1996) Special patient populations: onychomycosis in the HIV-positive patient. *J Am Acad Dermatol* 35: S13-16.
22. Daniel CR, Norton LA, Scher RK (1992) The spectrum of nail disease in patients with human immunodeficiency virus infection. *J Am Acad Dermatol* 27: 93-97.
23. Sáez de Ocariz MM, Arenas R, Ranero-Juárez GA, Farrera-Esponda F, Monroy-Ramos E (2001) Frequency of toenail onychomycosis in patients with cutaneous manifestations of chronic venous insufficiency. *Int J Dermatol* 40: 18-25.
24. Valencia IC, Falabella A, Kirsner RS, Eaglstein WH (2001) Chronic venous insufficiency and venous leg ulceration. *J Am Acad Dermatol* 44: 401-421.
25. Shemer A, Nathansohn N, Kaplan B, Trau H (2008) Toenail abnormalities and onychomycosis in chronic venous insufficiency of the legs: should we treat? *J Eur Acad Dermatol Venereol* 22: 279-282.
26. Robbins JM (2003) Treatment of onychomycosis in the diabetic patient population. *J Diabetes Complications* 17: 98-104.
27. Gupta AK, Konnikov N, MacDonald P, Rich P, Rodger NW, et al. (1998) Prevalence and epidemiology of toenail onychomycosis in diabetic subjects: a multicentre survey. *Br J Dermatol* 139: 665-671.
28. Ko JY, Lee HE, Jae H, Oh DH, Kim JS, et al. (2011) Cure rate, duration required for complete cure and recurrence rate of onychomycosis according to clinical factors in Korean patients. *Mycoses* 54: e384-388.
29. Farkas B, Paul C, Dobozy A, Hunyadi J, Horváth A, et al. (2002) Terbinafine (Lamisil) treatment of toenail onychomycosis in patients with insulin-dependent and non-insulin-dependent diabetes mellitus: a multicentre trial. *Br J Dermatol* 146: 254-260.

30. Gupta AK, Scher RK, De Doncker P (1997) Current management of onychomycosis. *An overview. Dermatol Clin* 15: 121-135.
31. Baran R, de Doncker P (1996) Lateral edge nail involvement indicates poor prognosis for treating onychomycosis with the new systemic antifungals. *Acta Derm Venereol* 76: 82-83.
32. Gupta AK, Konnikov N, Lynde CW, Summerbell RC, Albreski D, et al. (1999) Onychomycosis: predisposed populations and some predictors of suboptimal response to oral antifungal agents. *Eur J Dermatol* 9: 633-638.
33. Munro CS, Shuster S (1992) The route of rapid access of drugs to the distal nail plate. *Acta Derm Venereol* 72: 387-388.
34. Dykes PJ, Thomas R, Finlay AY (1990) Determination of terbinafine in nail samples during systemic treatment for onychomycoses. *Br J Dermatol* 123: 481-486.
35. Matthieu L, De Doncker P, Cauwenbergh G, Woestenborghs R, van de Velde V, et al. (1991) Itraconazole penetrates the nail via the nail matrix and the nail bed--an investigation in onychomycosis. *Clin Exp Dermatol* 16: 374-376.
36. Sommer S, Sheehan-Dare RA, Goodfield MJ, Evans EG (2003) Prediction of outcome in the treatment of onychomycosis. *Clin Exp Dermatol* 28: 425-428.
37. Kim JE, Park HJ, Lee JY, Cho BK (2003) The Compliance and Long-term Follow up of Onychomycosis Treatment. *Korean Journal of Medical Mycology* 8: 110-117.
38. Yu HJ, Kwon HM, Oh DH, Kim JS (2004) Is slow nail growth a risk factor for onychomycosis? *Clin Exp Dermatol* 29: 415-418.
39. Geyer AS, Onumah N, Uyttendaele H, Scher RK (2004) Modulation of linear nail growth to treat diseases of the nail. *J Am Acad Dermatol* 50: 229-234.
40. Na GY, Suh MK, Sung YOC SK (1995) A decreased growth rate of the toenail observed in patients with distal subungual onychomycosis. *Annals of Dermatology* 7: 217-221.
41. Gupta AK, Sibbald RG, Lynde CW, Hull PR, Prussick R, et al. (1997) Onychomycosis in children: prevalence and treatment strategies. *J Am Acad Dermatol* 36: 395-402.
42. Goulden V, Goodfield MJ (1997) Onychomycosis and linear nail growth. *Br J Dermatol* 136: 139-140.
43. Shemer A, Sakka N, Baran R, Scher R, Amichai B, et al. (2014) Clinical comparison and complete cure rates of terbinafine efficacy in affected onychomycotic toenails. *J Eur Acad Dermatol Venereol* .
44. Avner S, Nir N, Henri T (2005) Combination of oral terbinafine and topical ciclopirox compared to oral terbinafine for the treatment of onychomycosis. *J Dermatolog Treat* 16: 327-330.
45. Roberts DT, Taylor WD, Boyle J; British Association of Dermatologists (2003) Guidelines for treatment of onychomycosis. *Br J Dermatol* 148: 402-410.
46. Hay RJ, Baran R (2011) Onychomycosis: a proposed revision of the clinical classification. *J Am Acad Dermatol* 65: 1219-1227.
47. Baran R (2001) Topical amorolfine for 15 months combined with 12 weeks of oral terbinafine, a cost-effective treatment for onychomycosis. *Br J Dermatol* 145 Suppl 60: 15-19.
48. Elewski BE (1997) Bacterial infection in a patient with onychomycosis. *J Am Acad Dermatol* 37: 493-494.
49. Kirkpatrick CH, Rich RR, Bennett JE (1971) Chronic mucocutaneous candidiasis: model-building in cellular immunity. *Ann Intern Med* 74: 955-978.
50. Kirkpatrick CH (2001) Chronic mucocutaneous candidiasis. *Pediatr Infect Dis J* 20: 197-206.
51. Gupta AK, Taborda P, Taborda V, Gilmour J, Rachlis A, et al. (2000) Epidemiology and prevalence of onychomycosis in HIV-positive individuals. *Int J Dermatol* 39: 746-753.
52. Chi CC, Wang SH, Chou MC (2005) The causative pathogens of onychomycosis in southern Taiwan. *Mycoses* 48: 413-420.
53. Welsh O, Vera-Cabrera L, Welsh E (2010) Onychomycosis. *Clin Dermatol* 28: 151-159.
54. Gupta AK, Drummond-Main C, Cooper EA, Brintnell W, Piraccini BM, et al. (2012) Systematic review of nondermatophyte mold onychomycosis: diagnosis, clinical types, epidemiology, and treatment. *J Am Acad Dermatol* 66: 494-502.