

## Preservation of the Length of the First Metatarsal after Modified Mitchell's Osteotomy for Hallux Valgus Deformity. Overview, Technique and Preliminary Results

Vlamiis John, Karampinas K, Panagiotis, Polizois V, Evangelopoulos S, Dimitrios and Pneumaticos G, Spyridon

3<sup>rd</sup> Orthopaedic Department, University of Athens, Greece

**Corresponding author:** Panagiotis K, MD, MSc, Consultant in Orthopaedics, 3rd Department of Orthopaedic Surgery, KAT Hospital, University of Athens, Greece, 13 Kirinias str 15669. Athens, Greece, Tel: +302106537175; E-mail: [karapana@yahoo.com](mailto:karapana@yahoo.com)

**Received date:** November 25, 2014, **Accepted date:** February 23, 2015, **Published date:** Feb 25, 2015

**Copyright:** © 2015 John V, et al. This is an open-access article distributed under the terms of the Creative Commons Attribution License, which permits unrestricted use, distribution, and reproduction in any medium, provided the original author and source are credited.

### Abstract

**Background:** Mitchell's osteotomy is considered an effective treatment option for patients with moderate hallux valgus deformity. Common complications include shortening of the first metatarsal bone as well as inadequate correction. We present an overview of the technique and propose a new modification in an attempt to improve congruity of the metatarsophalangeal joint angle and minimize metatarsal shortening. Preliminary results are reported.

**Methods:** 9 patients (11 feet) were operated using the new osteotomy. All patients were evaluated postoperatively and at 2 year follow up by means of the hallux metatarsophalangeal-interphalangeal score (HMIS) of the AOFAS.

**Results:** Postoperatively, there was no pain in the first MTP joint, no deformity or signs of local inflammation. Average HMIS and AOFAS scores were found significantly improved at the second year follow up.

**Conclusion:** The new technique displays good results for the correction of moderate hallux valgus deformities and preserves the length of the metatarsal bone.

**Keywords:** Hallux valgus; Modified mitchell osteotomy; Metatarsal shortening; Metatarsophalangeal congruity

### Introduction

Hallux valgus represents a relatively common and complex forefoot angular deformity of the first metatarsophalangeal joint, affecting 22% to 36% of adolescents and leading to both functional and cosmetic problems [1-3]. The patient experiences tenderness over the area due to shoe wear pressure and a subsequent accompanying bursitis [4]. The lateral deviation of the great toe is associated with medial prominence of the distal first metatarsal (bunion). The sesamoids undergo lateral subluxation, the medial collateral ligament and capsule are stretched and the lateral soft tissue structures are contracted. The resulting metatarsophalangeal subluxation leads to the plantar displacement of the abductor hallucis tendon, creating an additional deforming force. Meanwhile, flexor and extensor tendons displace laterally contributing to the deformity. A bursa forms over the medial aspect of the first metatarsal and may ultimately be the cause of severe pain [1].

Based on the hallux valgus and the intermetatarsal angles, the deformity can be classified as mild (<200, <110), moderate (200-390, 110-150) or severe (>400, >150). As the deformity progresses, degeneration of the metatarsophalangeal joint (congruent, incongruent with or without subluxation and lateral sesamoid subluxation) occurs [1,4].

### Overview of the Mitchell's osteotomy

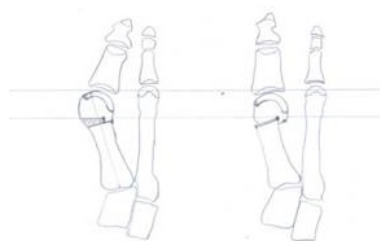
In 1945, Hawkins et al. is the first to describe a step cut osteotomy of the distal aspect of the first metatarsal for correction of hallux valgus [5]. The procedure, also known as Mitchell's bunionectomy, has been used effectively by many surgeons for the past 50 years [1,6,7]. The first metatarsal is accessed through an anteromedial incision, curved over the exostosis, preserving the dorsomedial cutaneous nerve. Subperiosteal stripping around the metatarsal neck and shaft is performed, followed by bunion resection and a lateral displacement osteotomy of the first metatarsal neck to correct metatarsus primus varus (step metatarsal osteotomy, between 2 cortical holes). The metatarsal head is shifted laterally, reefing of the medial articular capsule of the first metatarsophalangeal joint and a medial capsulorrhaphy to correct hallux valgus is performed. Final stabilization is achieved by means of chromic catgut sutures [1,5,8,9].

Failures usually occur either due to inadequate fixation with the suture loop or due to shortening of the first metatarsal by the step-off osteotomy. Sutures allow some degree of motion at the osteotomy site resulting in malunion, recurrence of the deformity and dorsal tilt of the distal fragment, while shortening and/or declination of the 1st metatarsal may result in load transfer phenomena to the lateral rays, leading to secondary pain [3,10]

Numerous modifications of the Mitchell's osteotomy have been reported, concerning soft tissue dissection, technique and site of the osteotomy as well as the fixation methods, perplexing the original

technique [4,11,12]. The most commonly performed modifications include the Y to V capsulorrhaphy to avoid damaging blood supply to the metatarsal head and the replacement of the classical transverse by a diverging trapezoid step off osteotomy to improve the degree of correction and minimize first metatarsal's shortening [3,4,13-16]. Additionally, modifications have been described concerning the orientation of displacement, the fixation of the osteotomy and the soft tissue releases [3,10,13-15,17-19]. In a study questioning thirty-one consultants performing a Mitchell's type osteotomy for the correction of hallux valgus deformity, the investigators discovered that 71% still perform an anteromedial incision as described by Mitchell. Eighty-four per cent prefer to do a Y-V capsulorrhaphy and the remaining 16% prefer the double breast capsular repair. 29% strip the periosteum circumferentially while the majority still prefers to preserve the lateral periosteum. The osteotomy is displaced laterally only by 29% of surgeons, while 71% of them prefer to displace both laterally and plantarward. Cortical holes are drilled by 68% to facilitate stabilization with a suture and thirty two per cent preferred k-wires with or without a suture and/or a plaster. Only one surgeon continued to use the exact technique as described by Mitchell in 1958 [4].

While failures of the classical technique occurred either due to inadequate fixation with the suture loop or due to shortening of the 1st metatarsal by the step-off osteotomy, failures of the modified techniques were mainly attributed to inadequate correction, excessive shortening of the first metatarsal, dorsal head tilt, poor fixation and delayed union or nonunion [3,10]. The worst results were related to technical problems, such as inadequate correction, early loss of fixation or malunion [3,20]. Although improvement of both metatarsophalangeal and intermetatarsal angles is associated with patient satisfaction, the intermetatarsal angle carries the higher significance. Correction of this angle largely depends on the displacement of the peripheral fragment following osteotomy [21].

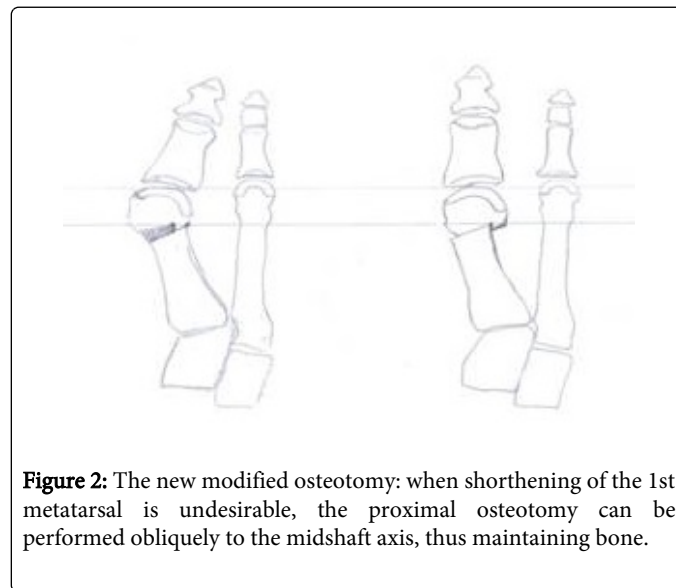


**Figure 1:** Trapezoid osteotomy with the base medial can achieve redirection of the articular surface and improved congruity of the metatarsophalangeal joint.

### The New Modified Technique

We propose a new modified technique for Mitchell's osteotomy in an attempt to correct the hallux valgus deformity, maintaining the length of the first metatarsal and achieving appropriate orientation of the metatarsophalangeal and intermetatarsal joints. A dorsomedial skin incision and a medial linear capsular incision are used to expose the head and the distal shaft of the first metatarsal. A step trapezoid osteotomy with the base medially and the top laterally is performed to reposition the metatarsal head laterally and reorientate the articular surface of the metatarsal head, thus improving the congruity of the

metatarsophalangeal joint (Figure 1). To maintain the length of the first metatarsal (trapezoid section), the proximal cut of the osteotomy is performed obliquely with regard to the middle shaft metatarsal line (Figure 2). Stability of the osteotomy can be achieved by means of a single screw (Herbert screw).



**Figure 2:** The new modified osteotomy: when shortening of the 1st metatarsal is undesirable, the proximal osteotomy can be performed obliquely to the midshaft axis, thus maintaining bone.

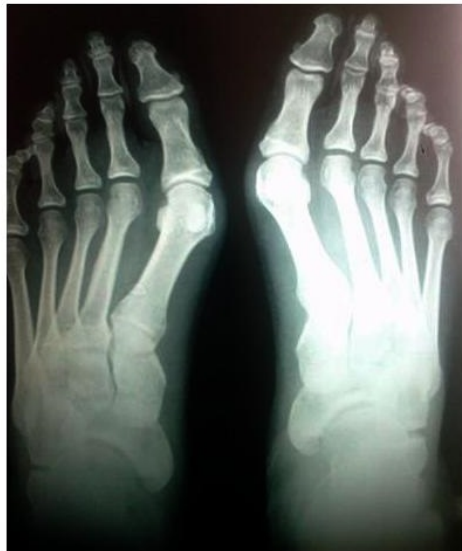### Materials and Methods

Since 2007, the proposed modified technique was performed in 9 consecutive patients (1 male and 8 female) with moderate hallux valgus deformities at 11 feet (2 bilateral). The hallux valgus was classified as moderate in most of the cases (7/11) and severe in 2/11. Mean age of our study group was 47 years (range 22-75). Average follow up was 30 months. All patients were operated by the same surgeon and were available for follow up. There was no incidence of intraoperative complications. Patients were evaluated preoperatively and at 2 year follow up by means of the hallux metatarsophalangeal-interphalangeal score (HMIS) of the American Orthopaedic Foot and Ankle Society score (AOFAS) and detailed informations were collected concerning pain, function and alignment [18]. All surgeries were performed by one single surgeon. Collected data as well as preoperative and postoperative anteroposterior and lateral X-rays were evaluated by two independent orthopaedic surgeons and the results were statistically analyzed.

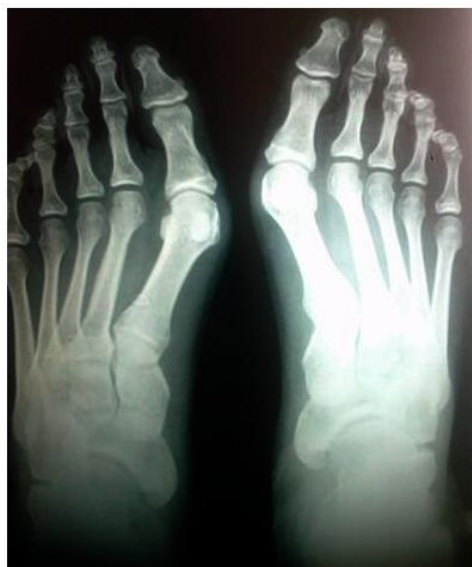### Results

Average preoperative valgus angle was 350 (range, 120-470) and intermetatarsal angle 140 (range, 120-220). There were no cases of malunion, non union, infection or avascular necrosis. Average postoperative valgus and intermetatarsal angle were 140 (range, 120-220) and 70 (range, 60-140) respectively. There was no pain in the first MTP joint, no deformity or signs of local inflammation and all patients were able to use commercially available shoes. Patients' preoperative and postoperative scores are shown on Table 1. Average HMIS score increased from 43 preoperatively to 87 postoperatively. Average preoperative pain, function and alignment were measured at 16.3, 21.6 and 2.9 respectively whereas average postoperative values were 35.4, 37.2 and 14.4 respectively (Figures 3 and 4).

Statistical analysis demonstrated a significant improvement for pain, function and alignment for all patients of the study group ( $p < 0.05$ ).



**Figure 3:** Preoperative (f+p) foot X-ray with hallux valgus deformity.



**Figure 4:** Postoperative (f+p) foot X-ray with hallux valgus treated with the new modified osteotomy.

## Discussion

The initial management of adolescent hallux valgus can be conservative and consists of forefoot-wide shoes, pads for bunion protection and arch supports. Quite often however, such measures fail

leading to chronic discomfort, difficulty with shoe wear and cosmetic dissatisfaction [13,22].

The presence of a painful bunion is an important criterion for surgical treatment. Selection of the appropriate surgical method should be based on the severity of the deformity assessed by the hallux valgus and/or intermetatarsal angles, taking also into account specific parameters such as, general health, level of motion, pain, quality of bone and soft tissue, life style foot wear and age [4,8,12,21]. Numerous surgical methods have been described for the correction of hallux valgus and the accompanying bunion. Tachdjian categorized the innumerable surgical options into five basic categories: a) metatarsal osteotomies, b) soft-tissue procedures at the first metatarsophalangeal joint, c) adductor hallucis transfer, d) excisions of the metatarsal prominence and e) proximal phalangeal resections [19,21]. Distal metatarsal osteotomies such as Mitchell's or Hohmann's are performed to treat mild-to-moderate deformities, whereas proximal osteotomies, such as Mann's, combined with soft-tissue dissection are preferred for the treatment of moderate-to-severe hallux valgus. Mitchell's osteotomy, in combination with proximal metatarsal osteotomy and first MTP joint lateral soft-tissue dissection, has been used to treat severe hallux valgus deformities [8,12,16,21].

The ideal osteotomy should fulfill three main criteria: a) attain, as close to normal, a three-dimensional alignment, b) correct any rotational deformity and c) maintain adequate metatarsal length. Unsatisfactory results may lead to joint impingement and to problems associated with the tendinous insertions on the distal fragment that would alter joint biomechanics and generate deforming forces. Stable fixation is very important to prevent malunion [3,12].

Indications for Mitchell's osteotomy vary amongst authors. Mann proposed an intermetatarsal angle  $< 200$  and a hallux valgus angle  $< 400$  [12]. Tanaka et al. suggested an intermetatarsal angle of  $< 150$  and hallux valgus angle of  $< 330$  [20]. Other indications have been the combination of young age with severe hallux valgus ( $IM \geq 150$ ), moderate to severe pain, deformity and joint instability, inability to wear normal footwear and failure of conservative treatment [8,15].

Maestro suggested eliminating the proximal screw by locking the two fragments distally: a notch was created via a medial extension of the cephalic part of the osteotomy, the plantar fragment was displaced laterally, and the distal end of the proximal fragment was then fit into the notch (secondary cut and interlocking joint technique). To further develop this concept and to increase the potential range of translation, Leemrijse et al. developed an original technique involving distal locking without shortening and proximal stabilization by impaction of a cortical-cancellous bone graft taken from the medial overhanging edge of the proximal fragment. This is nearly identical to ours described modification, oblique osteotomy orientation with a modified Scarf-Mitchell osteotomy, minimize shortening of the first metatarsal [23].

Already described modifications, although capable of correcting the hallux valgus and intermetatarsal angles, cannot maintain the length of the first metatarsal. Additionally, the Greek foot is characterized by a congenital longer second metatarsal. Application of a Mitchell's osteotomy in such a population can result in a significantly shorter first metatarsal, leading not only to cosmetic dissatisfaction but also to exacerbation of metatarsophalangeal joint alignment, alteration of joint biomechanics, metatarsalgia and plantar callosity. Our results demonstrated that the new modified osteotomy not only improved hallux valgus and intermetatarsal angles alleviating patients' symptoms but also succeeded in maintaining first metatarsal's length. The

performance of an oblique step trapezoid osteotomy, with regard to the middle shaft metatarsal line, maintains metatarsal length, maximizing correction and congruity of the metatarsophalangeal joint angle.

Limitations of this study include the limited size of the study group as well as the absence of cohort comparison group. Although, the initial results appear quite encouraging, future studies to include larger patient samples, as well as biomechanical studies are warranted to draw safer conclusions.

## Conclusion

Mitchell's osteotomy represents a reasonable surgical option for the treatment of hallux valgus, providing satisfactory results. This modification of Mitchell's osteotomy (the proximal cut of the step trapezoid osteotomy is performed obliquely with regard to the middle shaft metatarsal line) represents a novel technique for correcting moderate deformities, especially for people with a congenital longer second metatarsal, since it can minimize the shortening of the first metatarsal, maximize correction and reconstruct the congruity of the metatarsophalangeal joint angle.

## References

1. McDonald MG, Stevens DB (1996) Modified Mitchell bunionectomy for management of adolescent hallux valgus. *Clin Orthop Relat Res* : 163-169.
2. Tachdjian (1990) *Pediatric orthopaedics*. WB Saunders, Philadelphia, pp: 2626-2629.
3. Weiner BK, Weiner DS, Mirkopoulos N (1997) Mitchell osteotomy for adolescent hallux valgus. *J Pediatr Orthop* 17: 781-784.
4. Gower A, Greiss ME, Briggs PJ (2000) What is modified Mitchell's osteotomy? *The foot*10: 66-68.
5. Hawkins F, Mitchell C, Hedrick D (1945) Correction of hallux valgus by metatarsal osteotomy. *J Bone Joint Surg*. 27: 387-394.
6. Canale PB, Aronsson DD, Lamont RL, Manoli A 2nd (1993) The Mitchell procedure for the treatment of adolescent hallux valgus. A long-term study. *J Bone Joint Surg Am* 75: 1610-1618.
7. Mann RA (1990) Bunion surgery: decision making. *Orthopedics* 13: 951-957.
8. Grannis WR, Meier AW, Tanner JB. (1956) Surgical treatment of bunions distal metatarsal osteotomy. *Calif Med* 85: 245-247.
9. Mitchell C, Fleming J, Allen R, Glenney C, Sanford Ga (1958) Osteotomy-bunionectomy for hallux valgus. *J Bone Joint Surg. Am* 40-40A: 41-58.
10. Talab YA (2002) Hallux valgus in children: a 5-14-year follow-up study of 30 feet treated with a modified Mitchell osteotomy. *Acta Orthop Scand* 73: 195-198.
11. Blum JL (1994) The modified Mitchell osteotomy-bunionectomy: indications and technical considerations. *Foot Ankle Int* 15: 103-106.
12. Yamamoto K, Imakiire A, Katori Y, Masaoka T, Koizumi R (2005) Clinical results of modified Mitchell's osteotomy for hallux valgus augmented with oblique lesser metatarsal osteotomy. *J Orthop. Surg. (Hong Kong)* 13: 245-252.
13. Downing ND, Radford PJ (1999) Stabilization of the Mitchell first metatarsal osteotomy using an intramedullary K-wire. *Foot Ankle Int*. 20: 301-302.
14. Glynn MK, Dunlop JB, Fitzpatrick D (1980) The Mitchell distal metatarsal osteotomy for hallux valgus. *J Bone Joint Surg. Br* 62-62B: 188-91.
15. Mann RA, Coughlin MJ (1981) Hallux valgus--etiology, anatomy, treatment and surgical considerations. *Clin Orthop Relat Res* 157: 31-41.
16. Mohamed Z, Issam D (2003) Modified Mitchell's Osteotomy for the Treatment of Hallux Valgus. Experience at King Hussein Medical Center. *JRMS* 10: 6-10.
17. Bonner AC Jr (1986) Rigid internal fixation of the Mitchell-Hawkins osteotomy/bunionectomy with the Herbert Bone Screw. *J Foot Surg* 25: 390-393.
18. Kitaoka HB, Alexander JJ, Adelaar RS, Nunley JA, Myerson MS, et al. (1994) Clinical rating systems for the ankle-hindfoot, midfoot, hallux, and lesser toes. *Foot Ankle Int* 15: 349-353.
19. Pickering S, Zafiropoulos G, Henry APJ (1999) Shortening and upward displacement at osteotomy of 1st Metatarsal for hallux valgus. The effects on Forefoot load bearing. *J Bone Joint Surg* 81: 378.
20. Tanaka Y, Takakura Y, Kitada T, Aoki T, Tamai S (1992) A follow-up study of Mitchell osteotomy for the halux valgus. *J Jpn Orthop Assoc* 66:S264-S252.
21. Meier PJ, Kenzora JE (1985) The risks and benefits of distal first metatarsal osteotomies. *Foot Ankle* 6: 7-17.
22. Geissele AE, Stanton RP (1990) Surgical treatment of adolescent hallux valgus. *J Pediatr Orthop* 10: 642-648.
23. Leemrijse T, Maestro M, Tribak K, Gombault V, Bevernage BD, et al. (2012) Scarf osteotomy without internal fixation to correct hallux valgus. *Orthopaedics & Traumatology: Surgery & Research* 98: 921-927.