

## Percutaneous Vertebroplasty Painful Malignant Involvement of the Second Cervical Vertebra (C2): Case Report

Rispoli R<sup>1\*</sup>, Zofrea G<sup>1</sup>, Bartolini N<sup>2</sup>, Caputo N<sup>2</sup> and Carletti S<sup>1</sup>

<sup>1</sup>Department of Neurosurgery, S.Maria Hospital, Terni, Italy

<sup>2</sup>Department of Neuroradiology, S.Maria Hospital, Terni, Italy

\*Corresponding Author: Rispoli R, Department of Neurosurgery, "S. Maria" Hospital, Terni, Italy; Tel: 00393331163632; E-mail: [rossella.rispoli@libero.it](mailto:rossella.rispoli@libero.it)

Rec date: Jun 06, 2014, Acc date: Jul 11, 2014, Pub date: Jul 13, 2014

Copyright: © 2014 Rispoli R, et al. This is an open-access article distributed under the terms of the Creative Commons Attribution License, which permits unrestricted use, distribution, and reproduction in any medium, provided the original author and source are credited

### Abstract

The axis is an important element of the musculoskeletal complex in the upper cervical spine. It is surrounded by a number of delicate neurological and vascular structures and controls a wide range of movements. Thus, a pathological C2 fracture is a threatening condition. Multiple myeloma and osteolytic metastases are the most frequent malignant lesions affecting the spine. However, the cervical spine, especially the C1 and C2 region, seems to be involved less often.

In this study, we report a case of unstable C2 fracture treated with the percutaneous vertebroplasty. Vertebroplasty is a well-established procedure for pain control and stabilization of vertebral pathology including metastasis, hemangioma, and multiple myeloma.

The PVP procedure allows the option of preserving the mobility of the upper cervical spine.

**Keywords:** C2 vertebra; Percutaneous vertebroplasty; Spine stabilization

### Case Report

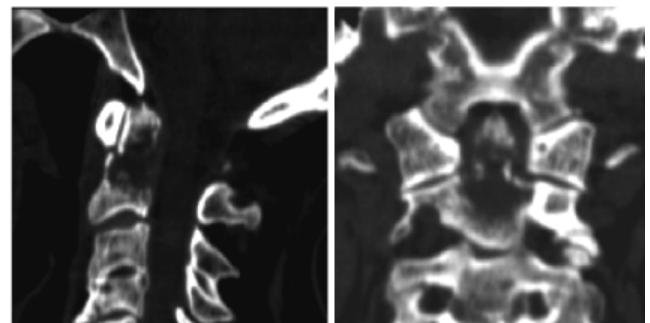
A 74 year old male presented with a one-month history of neck pain without antecedent trauma.

The patient sought help from his primary care physician who prescribed prescription analgesics, anti-inflammatory medication, muscle relaxants and physical therapy

Despite ten days of therapy, he had inadequate pain relief and he presented to the Emergency room to our Hospital.

The X-ray images demonstrated a fracture in C2; a CT of the cervical spine was positive for a lytic lesion involving the C2 vertebral body and odontoid process with an underlying pathologic fracture (Figure 1a,1b); magnetic resonance imaging (MRI) demonstrated a focal area of signal abnormality with a pre-dominantly hypointense complex lesion on T1 weighted images, and hyperintense lesion on T2 weighted images. This MRI confirmed the presence of a lytic/complex cystic lesion at the base of dens with extension into the C2 vertebral body (Figure 2). At this point, the patient was transferred to Neurosurgery Unit. Total-body CT was performed and demonstrated a mass in the right upper lobe of the lung. We recommended biopsy and possible vertebroplasty. The patient provided informed consent after an explanation of the risks/benefits and indications for the procedure. The procedure was performed in the X-ray suite with a single-plane Angiography C-arm system. The patient was in the supine position and following the routines for percutaneous vertebroplasty (PVP) procedures at the cervical spine at our unit, under general anaesthesia. A fibrotic nasal intubation was performed

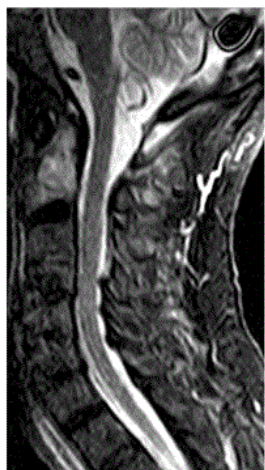to minimize movement of the neck. The patient was given a prophylactic dose of an antibiotic.



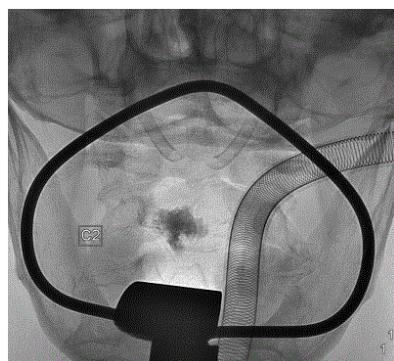
**Figure 1a,1b:** CT of the cervical spine was positive for a lytic lesion involving the C2 vertebral body and odontoid process with an underlying pathologic fracture

The otolaryngology service placed an oropharyngeal retractor (Crowe–Davis mouth gag) within the patient's oral cavity in order to adequately expose the oropharynx. The soft palate was tethered superiorly using red rubber catheters. The oral cavity and oropharynx were then prepped using Beta dine swabs, and a 22-gauge, 5 in. spinal needle was used to localize the best approach toward the left aspect of the C2 vertebral body, in the location of the lytic lesion seen on the CT scan and avoiding the retropharyngeal right internal carotid artery. 10-gauge guide needle was then placed into the C2 vertebral body over an introducer stylet under fluoroscopic guidance. A 12-gauge biopsy needle was then advanced through the kyphoplasty guide needle into the C2 vertebral body beyond the anterior aspects of the guide needle.

The biopsy needle was retracted under gentle suction, and specimens were obtained for histology. A trocar needle filled with high viscosity radiopaque poly-methyl-methacrylate (PMMA) was then placed within the guide needle. Each batch of PMMA was mixed with 500 mg vancomycin powder. Under intermittent fluoroscopic visualization, 2 cc of PMMA was slowly hand injected into the C2 vertebral body (Figure 3). The guide catheter was then removed.



**Figure 2:** MRI confirmed the presence of a lytic/complex cystic lesion at the base of dens with extension into the C2 vertebral body



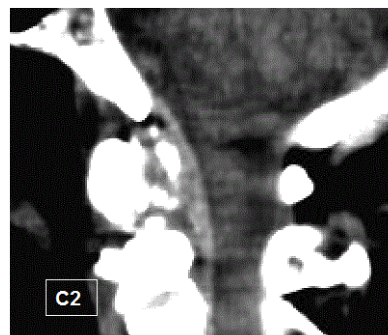
**Figure 3:** Cement was injected under continuous fluoroscopy control in the anteroposterior projection

The patient tolerated the vertebroplasty of C2 without complications and he had adequate pain relief. Follow-up CT images of the upper cervical spine 3 months after the PVP procedure showed that the cement cast is unchanged. A clear osteosclerotic reaction occurred around the cement cast (Figure 4).

## Discussion

The axis is an important element of the musculoskeletal complex in the upper cervical spine. It is surrounded by a number of delicate neurological and vascular structures and controls a wide range of movements [1]. Thus, a pathological C2 fracture is a threatening condition. Multiple myeloma (MM) and osteolytic metastases are the

most frequent malignant lesions affecting the spine [2]. Severe neck and back pain and reduced mobility are the most common symptoms in patients with vertebral metastases and MM. The treatment is basically conservative, with analgesics, cytostatic, radiotherapy, reinforced corset and/or neck brace. However, the cervical spine, especially the C1 and C2 region, seems to be involved less often. Pathologic fractures involving the C2 vertebral body and odontoid process pose a unique dilemma, as the surgical approaches for direct odontoid process screw fixation have several limitations. There have been a small number of transoral approach C2 vertebroplasties or kyphoplasties reported in the literature. Previous attempts at accessing the C2 vertebral body and/or odontoid process were performed utilizing fluoroscopy or CT guidance. The proximity to the spinal cord and adjacent vascular structures increases the difficulty of this procedure. Lateral, poster lateral, and anterior approaches have been described in prior reports for surgery, biopsy, and/or bone cement placement. The anterior transoral approach for accessing the cervical spine appears to best avoid the adjacent neurovascular structures.



**Figure 4:** Follow-up CT images of the upper cervical spine 3 months after the PVP procedure showed that the cement cast is unchanged. A clear osteosclerotic reaction occurred around the cement cast

Otolaryngologists and neurosurgeons have extensively used the transoral approach to access the upper cervical spine. This is a well-established access route in the otolaryngological and neurosurgical literature [3,4] a thin layer of fascia and muscles separates the upper cervical spine from the oral mucosa. One of the potential downsides of the transoral cervical spine surgical approach is a reported risk of wound infection up to 2% and a risk of meningitis up to 4.5%. Extension of infection into facial planes can cause a retropharyngeal abscess and invasion of the meningeal layers leading to meningitis and encephalitis. The rate of infection has dropped significantly in recent years, due to the improvement in aseptic techniques, perioperative antibiotics, and thorough cleansing of the surgical bed prior to the procedure.

Percutaneous vertebroplasty (PVP) of the axis is a challenging procedure which may be performed by a percutaneous or a transoral approach [5,6]. There are few reports of PVP at the C2 level. Transoral vertebroplasty is postulated to have a lower risk of infection given the minimal tissue disruption by the needle. The addition of perioperative intravenous antibiotics, antibiotics within the PMMA mixture, and post-procedural antibiotics should further reduce the infection risk.

Severe neck and back pain and reduced mobility are the most common symptoms in patients with vertebral metastases. The treatment is basically conservative, with analgesics, cytostatic, radiotherapy, reinforced corset and/or neck brace.

In patients with osteolytic lesions in the cervical spine and refractory pain, with or without fracture dislocations, different types of surgical stabilization methods have traditionally been used. The least invasive method consists of the halo-vest treatment, which can safely be performed concurrently with the medical treatment. This form of treatment may lead to bone reconstitution and stability. Posterior osteosynthesis with or without decompression involves permanent fixation from occipital bone to C4 with restriction of flexion, extension, bending and rotation. The procedure has a low risk of complications, provides immediate stabilization of the C2 lesion and allows safe mobilization of the patient with a neck brace.

During recent years an increasing number of patients with C2 metastases have been treated with PVP. This has offered rapid and long-lasting pain relief in up to 85% of cases [7].

Vertebroplasty is a well-established procedure for pain control and stabilization of vertebral pathology including metastasis, hemangioma, and multiple myeloma.

The PVP procedure allows the option of preserving the mobility of the upper cervical spine. On the other hand, posterior stabilization leads to fixation from the occipital bone to the C4 vertebra, resulting in a considerable decrease in mobility. If sufficient stabilization is not achieved with PVP, the surgical option is still available.

We think that PVP is a less aggressive procedure than any surgical stabilizing procedure in the upper cervical spine and does not restrict

the mobility of the occipito-cervical junction [8]. The patient can usually walk a couple of hours after treatment, and can be discharged from hospital within 24 h of the procedure. Considering the higher risk of complications of PVP in this region, it is highly recommended that the treatment be performed by an experienced specialist at a centre where many PVP procedures are carried out and which has excellent radiological equipment.

## References

1. Fung KY, Law SW (2005) Management of malignant atlanto-axial tumours. *J Orthop Surg* 13: 232-239.
2. Jenis LG, Dunn EJ, An HS (1999) Metastatic disease of the cervical spine. A review *Clin Orthop Relat Res* 359: 89-103.
3. Bonney G, Williams JP (1985) Trans-oral approach to the upper cervical spine. A report of 16 cases. *J Bone Joint Surg Br* 67: 691- 698.
4. Spetzler RF, Hadley MN, Sonntag V (1988) the transoral approach to the anterior superior cervical spine. A review of 29 cases. *Acta Neurochir Suppl* 43: 69-74.
5. Guglielmi G, Andreula C, Muto M, Gilula LA (2005) Percutaneous vertebroplasty: indications, contraindications, technique, and complications. *Acta Radiol* 46: 256-268
6. Levine SA, Perin LA, Hayes D, Hayes WS (2000) An evidence-based evaluation of percutaneous vertebroplasty. *Manag Care*. 9: 56-60.
7. Cotten A, Boutry N, Cortet B, Assaker R, Demondion X, et al. (1998) Percutaneous vertebroplasty: state of the art. *Radio- graphics*. 18: 311-323.
8. Martin JB, Gailloud P, Dietrich P-Y, Luciani ME, Somon T (2002) Direct transoral approach to C2 for percutaneous vertebroplasty. *Cardiovasc Intervent Radiol*. 25: 517-519.