

## Novel Ultrasonographic Method to Assess Metatarsal Heads Heights in Hallux Valgus Patients: Pre and Post-Surgical Evaluation after First Metatarsal Osteotomy

Stoppino LP<sup>1\*</sup>, Cassano A<sup>2</sup>, Cleopazzo E<sup>1</sup>, Moffa AP<sup>1</sup>, Specchiulli LP<sup>1</sup>, Gallo C<sup>3</sup>, Vinci R<sup>1</sup>, Vittore D<sup>2</sup> and Macarini L<sup>1</sup>

<sup>1</sup>Section of Diagnostic Imaging, Department of Medical & Surgical Sciences, University of Foggia, Viale Pinto, Foggia, Italy

<sup>2</sup>Section of Orthopaedic Surgery, Department of Clinical & Experimental Medicine, University of Foggia, Viale Pinto, Foggia, Italy

<sup>3</sup>Section of Bioinformatics, Department of Clinical & Experimental Medicine, University of Foggia, Viale Pinto, Foggia, Italy

### Abstract

**Objective:** Hallux valgus is a forefoot deformity usually revealed with a weight-bearing radiograph of the foot. The aim of this study is to describe a new ultrasonographic method to assess metatarsal heads in hallux valgus patients.

**Methods:** We enrolled 38 patients with hallux valgus candidates to surgery. We assessed the ultrasonographic distance between the inferior surface of all metatarsal heads and support plane, before and after surgery. Moreover, we assessed the American Orthopaedic Foot and Ankle Society (AOFAS) clinical score before and after surgery.

**Results:** Our results showed a decrease of ultrasound distance for the first metatarsal head before and after surgery and an increase in all other distances of the remaining metatarsal heads before and after surgery. Finally, we showed significant differences between preoperatively and postoperatively clinical values.

**Conclusion:** The first metatarsal osteotomy should be able to restore the normal distribution of forefoot loading forces, hence reducing the associated metatarsalgia, as confirmed in this study. We suggest that our ultrasonographic method represent an accurate diagnostic tool in the pre and post-surgical evaluation of patients with hallux valgus, thus allowing a direct and reproducible measurement of metatarsal heads.

**Keywords:** Hallux valgus; Ultrasonography; Metatarsal heads; Forefoot; First metatarsal osteotomy

**Abbreviations:** MTH: Metatarsal Head; US: Ultrasonographic; AOFAS: American Orthopaedic Foot and Ankle Society; PCA: Principal Component Analysis; HMI: Hallux Metatarsophalangeal-Interphalangeal

### Background

Generalized or localized fore foot pain in the region of metatarsal heads is included in metatarsalgia. The repetitive loading of a locally concentrated force in the fore foot during gait is a principal etiological component of metatarsalgia. This is classified in to three types by Espinosa and colleagues: Primary, secondary and iatrogenic [1,2].

The abnormalities of metatarsal anatomy and the relationship between the metatarsal and the rest of the foot causes an overload on the fore foot. This is primary type of metatarsalgia [2]. Frequently, in these patients, the pain is produced during propulsive phase of gait [1]. The most principal cause is excessive length of second metatarsal. Others causes are congenital deformities, neoplastic processes, cavus foot, consequences of surgical procedures or fractures with extension of the metatarsal head and excess plantar flexion of fore foot [2]. Secondary metatarsalgia is caused by others conditions such as trauma, hallux rigidus, inflammatory arthropathy, arthritis, interdigital neuroma, tarsal syndrome tunnel and Freiberg infraction [3]. Iatrogenic metatarsalgia is associated with an alteration of plantar pressure to the fore foot caused by reconstructive procedures [2]. Hallux valgus is a fore foot deformity characterized by progressive lateral deviation of the hallux and medial deviation of the first metatarsal. This condition, frequently associated with metatarsalgia [4], produces a medial prominence on the first metatarsophalangeal joint. The prevalence rate of this deformity is 36% in population over 65 years, while decrease in adult between 18 and 65 years (23%) [5]. In the adult population the hallux valgus is a result of association of environmental and genetic factors

and other different conditions (traumatic events, structural deformity, metabolic disorders) [6]. In these patients, forefoot pain is produced by an incompetence of great toe and first metatarsal in their weight-bearing function [2].

Weight-bearing (standing) anterior-posterior, lateral, and oblique radiographs of the feet are necessary to critically assess the hallux valgus deformity.

The aim of this study is to describe a new ultrasonographic method to assess metatarsal heads in patients with hallux valgus before and after surgical correction.

### Methods

Between May 2016 and May 2018, 38 patients with moderate to severe hallux valgus were prospectively enrolled into this single centre study. The inclusion criterion was symptomatic hallux valgus with no previous surgical intervention. All patients were treated by proximal or distal first metatarsal osteotomies by a single surgeon (DV). We divided our population's study into 2 groups: Group A (men, 7 patients) and

**\*Corresponding author:** Stoppino LP, Section of Diagnostic Imaging, Department of Medical & Surgical Sciences, University of Foggia, Viale Pinto, Foggia, Italy, Tel: +39-0881-736089; Fax: +39-0881-733866; E-mail: [luca.stoppino@unifg.it](mailto:luca.stoppino@unifg.it)

Received May 04, 2019; Accepted May 15, 2019; Published May 22, 2019

**Citation:** Stoppino LP, Cassano A, Cleopazzo E, Moffa AP, Specchiulli LP, et al. (2019) Novel Ultrasonographic Method to Assess Metatarsal Heads Heights in Hallux Valgus Patients: Pre and Post-Surgical Evaluation after First Metatarsal Osteotomy. Clin Res Foot Ankle 7: 289. doi: [10.4172/2329-910X.1000289](https://doi.org/10.4172/2329-910X.1000289)

**Copyright:** © 2019 Stoppino LP, et al. This is an open-access article distributed under the terms of the Creative Commons Attribution License, which permits unrestricted use, distribution, and reproduction in any medium, provided the original author and source are credited.

Group B (women, 31 patients). Demographic characteristics are summarized in Table 1.

All hallux valgus patients underwent Ultrasound (US) examination of Metatarsal Heads (MTHs). In order to evaluate the forefoot in upright position, we designed and achieved a small desk that was composed by a polymethyl methacrylate support plane (4 mm of thickness), specific metal supports to allow upright position of the patient and a small wooden wedge covered with rubber that was positioned below the back foot throughout the examination (Figure 1). Each patient was asked to assume the upright position over the desk and US gel was placed on both sides of the polymethyl methacrylate support plane (Figure 1). All US examinations were performed by one highly experienced musculoskeletal sonographer (LPST) using a 12 MHz linear-array transducer positioned in parallel to metatarsal heads axis. The accurate alignment of the transducer was verified from the clear vision of the longitudinal metatarsal cortex on the sonogram (Figure 2). One week before surgery and 12 months later the US distances (in millimeters) between the inferior surface of all MTHs (MTH1, MTH2, MTH3, MTH4, MTH5) and support plane were assessed in all patients. Furthermore, simultaneously the American Orthopaedic Foot and An-

kle Society (AOFAS) clinical rating score was assessed using the Hallux Metatarsophalangeal-Interphalangeal (HMI) scale [7,8].

All data analyses were performed using the Statistical Package for Social Sciences (v.20, SPSS Inc., Chicago, IL, USA). The differences between the average of MTHs US distances and AOFAS scores in pre and post-operative assessments were compared using the paired Student t-test. ANOVA test was conducted to compare within-group and between group variability. A value of  $p \leq 0.05$  was considered statistically significant. The association between MTHs US distances and AOFAS scores was assessed by Spearman's rank correlation. The Principal Component Analysis (PCA) was performed using the correlation matrix.

## Results


Thirty-eight patients were studied for a total of 40 feet, 23 right feet and 17 left feet. In 2 patients the surgical correction was performed bilaterally. The mean MTH1 US distance pre and post-operatively was 8.97 and 5.25 mm, respectively ( $p < 0.05$ ). The mean MTH2 US distance pre and post-operatively were 7.65 mm and 9.77 mm, respectively. The mean MTH3 US distance pre and post-operatively were 6.98 mm and 8.44 mm, respectively. The mean MTH4 US distance pre and post-operatively were 6.67 mm and 8.26 mm, respectively. The mean MTH5 US distance pre and post-operatively was 6.65 mm and 7.58 mm, respectively (Figures 3 and 4). The student t-test showed a statistically significant difference between the mean values of the US distances for each metatarsal head before and after surgery ( $p \leq 0.05$ ).

In all patients was observed a rebalancing of the forefoot support confirmed by the approach of the I metatarsal head to the support surface with an increase in the average distance between the II, III, IV, V metatarsal heads and the supporting surface. The mean reduction in the MTH1 US distance before and after surgical treatment was 3.79 mm.

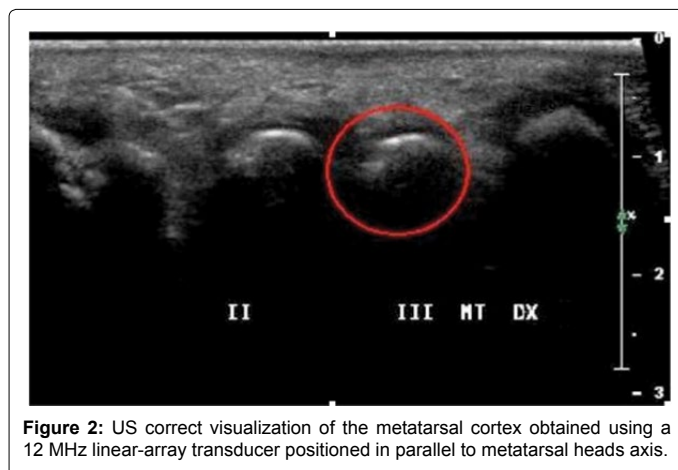
Moreover, also ANOVA test revealed that US measurements of the MTHs distances differ significantly in the pre and post-operative ( $p$ :

Number	38
Sex (F, M)	31.7
Age (years)	57.3 ± 8 (range: 31-71)
Height (cm)	165 ± 12.7 (range: 156-182)
Weight (Kg)	67.8 ± 8.2 (range: 48-85)
Body Mass Index (Kg/m <sup>2</sup> )	24.7 ± 1.72

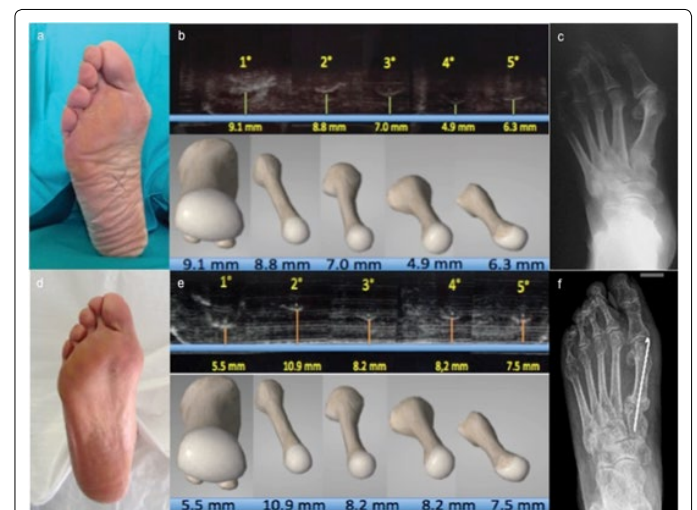
**Table 1:** Patients demographics.



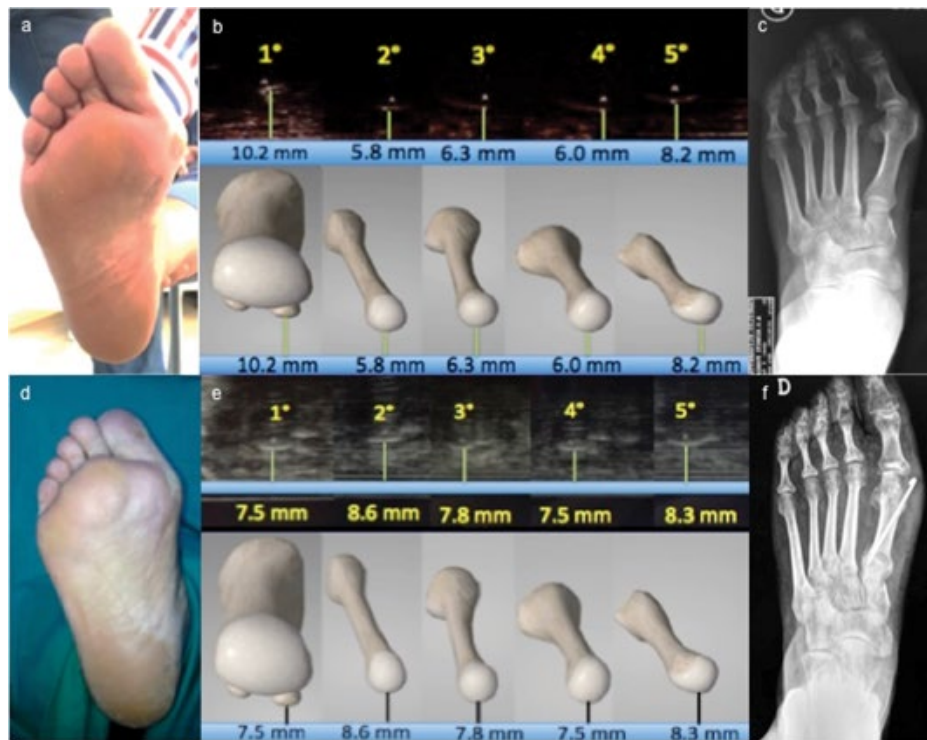
**Figure 1:** (a) Small desk with a polymethyl methacrylate support plane and specific metal supports to allow upright patient's position. (b) US gel was placed on both sides of the desk using a small wedge positioned below the rear foot.



**Figure 2:** US correct visualization of the metatarsal cortex obtained using a 12 MHz linear-array transducer positioned in parallel to metatarsal heads axis.



**Figure 3:** (a) 62-year-old woman with hallux valgus of the right foot, metatarsalgia at III and IV metatarsal heads and failure of I metatarsal. (b) The US measurements performed before and (e) after surgical correction of hallux valgus with osteotomy of the base of I metatarsal bone highlighted the approach of I metatarsal head to the support surface. (d) The increase in distances of the other metatarsal heads compared to the support surface, the reduction of pain and plantar hyperkeratosis to III and IV metatarsal head and the improvement of AOFAS score (32 points preoperatively to 90 points 12 months after surgery) support the rebalancing of the forefoot load. (c, f) Radiographic images also confirm the successful surgical correction of hallux valgus



**Figure 4:** (a) 45-year-old woman with hallux valgus of the right foot and metatarsalgia at II, III and IV metatarsal heads. (b) Preoperative US measurements prove the failure of I metatarsal head and the load transfer on II, III and IV metatarsal heads, (c) confirmed by radiographic images and (a) plantar hyperkeratosis. (e) The US measurements performed 12 months after surgery demonstrate the approach of I metatarsal head to the support surface with rebalancing of the forefoot load. The US results are consistent with clinical score (AOFAS score improved from 26 preoperatively to 75 postoperatively). (d) The reduction of plantar hyperkeratosis and (f) radiographic evaluation also confirm the successful surgical correction of hallux valgus.

Source of variation	SS	DS	MS	F	p-value	Critical F value
Rows	34,21,85,375	39	8,77,39,83,974	82,40,98,754	1,20734 X 10 <sup>-30</sup>	6,29285 X 10 <sup>-69</sup>
Columns	61,68,07,625	9	6,85,34,18,056	6,43,70,90,946	6,29285 X 10 <sup>-30</sup>	6,29285 X 10 <sup>-30</sup>
Error	37,37,01,375	351	1,06,46,76,282			
Total	1,33,26,94,375	399				

Table 2: ANOVA test.

	MTH1	MTH2	MTH3	MTH4	MTH5	AOFAS
MTH1	1.00 (0.00)	0.00 (0.70)	0.00 (0.04)	0.07 (0.66)	0.06 ( )	0.00 (0.81)
MTH2	0.00 (0.70)	1.00 (0.00)	0.38 (0.02)	0.13 (0.41)	0.18 ( )	0.00 (0.77)
MTH3	0.00 (0.04)	0.38 (0.02)	1.00 (0.00)	0.09 (0.56)	0.11 ( )	0.00 (0.24)
MTH4	0.07 (0.66)	0.13 (0.41)	0.09 (0.56)	1.00 (0.00)	0.53 ( )	0.05 (0.77)
MTH5	0.06 (0.69)	0.18 (0.27)	0.11 (0.48)	0.53 (0.00)	1.00 (0.00)	0.00 (0.84)
AOFAS	0.00 (0.81)	0.00 (0.77)	0.00 (0.24)	0.05 (0.77)	0.00 ( )	1.00 (0.00)

Table 3: Matrix of correlations and p-values.

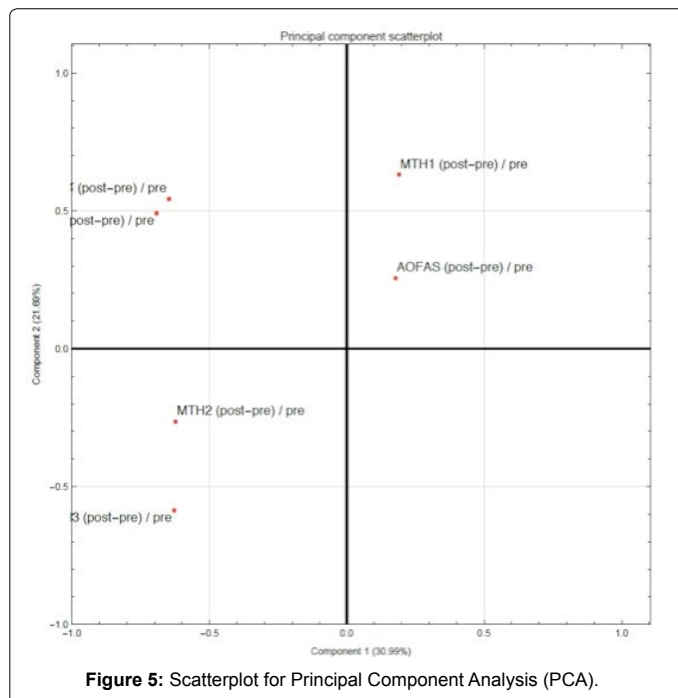
1,20734 X 10<sup>-30</sup> and p: 6,29285 X 10<sup>-30</sup>, respectively) as shown in Table 2.

There was a significant clinical improvement of metatarsalgia with an upgrading of the mean AOFAS score from 37.2 to 85.1 points (pre and postoperative, respectively). In fact, a statistical significant mean improvement of 47 points was observed ( $p \leq 0.05$ ).

The correlation analysis also showed that the following variables MTH1, MTH2, MTH3, MTH4, MTH5 and AOFAS score are all independent and statistically significant (Table 3). Greater “cohesion” was found between MTH2 and MTH3 ( $r=0.38$ ) and between MTH4 and MTH5 ( $r=0.53$ ) (Table 3 and Figure 5).

## Discussion

Hallux valgus is the most common disorder affecting the great toe caused by lateral deviation of the hallux and medial deviation of the first metatarsal resulting in a medial prominence on the first metatarsophalangeal joint [6]. Patients with hallux valgus experienced almost always metatarsalgia, that is a fore foot pain caused by the incompetence of the first ray (great toe and first metatarsal) in its weight-bearing function, causing a pressure transfer to the lesser metatarsals [2]. Also, painful plantar callosities are commonly associated with hallux valgus deformity and are often observed below the second metatarsal head [9]. Conventionally, weight-bearing radiographs of the foot including anterior-posterior, internal oblique and lateral view were performed in order to assess hallux valgus deformity for an accurate treatment planning [1,6].



Although the common forefoot disorders such as osteoarthritis, overuse arthropathy, rheumatoid and psoriatic arthritis, bursitis, Morton's neuroma and bone disorders have been studied using US imaging, to our knowledge there are no published studies about the US assessment of metatarsal heads in hallux valgus patients.

In this study, we attempted to answer the question "Does surgery for hallux valgus have a significant positive effect on foot function?". We evaluated both objective (weight-bearing radiographs of the foot and US examination of metatarsal heads) and subjective (AOFAS Hallux Metatarsophalangeal-Interphalangeal Scale) parameters before and after surgery. This methodology allowed us to obtain reliable data which may be reproduced in other studies.

Already others authors made an US measurement of the MTHs heights and the thickness of the sole beneath the MTHs. Gooding et al. [10] determined the height of MTHs in diabetic patients. Graf et al. [11] used US to assess the plantar flexed metatarsal position evaluating the degree of surgical correction necessary to realign the depressed metatarsal. Moreover, many authors showed that the vertical alignment of the MTH is linear [12,13] and also that the thickness of the sole under MTHs decreases from the first to fifth ray [13].

In this study, we analysed a population with a moderate to severe hallux valgus deformity suggesting an innovative US assessment of the metatarsal heads before and after surgical treatment. Our results showed a statistically significant difference between the mean values of the US distances for each metatarsal head before and after surgical correction of hallux valgus deformity ( $p \leq 0.05$ ). In particular, we observed a decrease in the MTH1 US distance before and after surgical treatment (mean decrease value of 3.79 mm) and an increase in all other MTHs (MTH2, MTH3, MTH4, MTH5) distances before and after surgery. These data explained the fundamental role of the surgery in order to restore a mechanical balance in the forefoot thanks to a decrease of the MTH1 distance and an increase of the distance between remaining MTHs and the supporting plane. Moreover, parallel to the mechanical rebalance data forefoot, we showed significant differences

between preoperative and post-operative values of AOFAS score with a statistical significant mean improvement of 47 points ( $p \leq 0.05$ ). Also, we observed a remarkable reduction of symptomatic plantar callosities. Therefore, our data demonstrate how osteotomy is able to restore the normal distribution of load forces within the forefoot allowing a significant reduction of the metatarsalgia associated to plantar keratosis in patients affected by hallux valgus deformity.

Our US method for the study of the metatarsal heads showed several advantages compared to traditional diagnostic methods. Indeed, US is an easily applicable imaging modality without radiations, rapid, non-invasive, low cost and with a good sensibility and specificity [14]. It represents the only clinically available modality that can provide dynamic information about soft tissue and osseous structures [13] which allows, as in our study, a direct and reproducible measurement of the US distance between the inferior surface of all MTHs and support plane. Nevertheless, the present study has many limitations including the small cohort of patients and its single centre design. Also, being US an operator-dependable imaging modality, we minimized the problem by making all US scans to a single operator [15]. Finally, in order to avoid ultrasound reverberation artefacts generated by polymethyl methacrylate support plane, we changed the slope of US transducer.

## Conclusion

In conclusion, although larger studies are needed to confirm our results, we suggest that our US method is crucial for the assessment of MTHs in patients with hallux valgus deformity associated to metatarsalgia. Therefore, this technique represents an accurate diagnostic tool in the pre and post-surgical evaluation of these patients and may be useful for many other forefoot disorders.

## Ethical Approval

The ethics committee of our hospital approved the study protocol.

## Consent for Publication

The experimental procedure was well explained to each subject and informed consent was obtained.

## Availability of Data and Materials

The datasets used and/or analysed during the current study are available from the corresponding author on reasonable request.

## Competing Interests

The authors declare that they have no competing interests.

## Authors Contributions

LPST was involved in the conception and design of the study, drafted the manuscript, critically reviewed the manuscript, edited the manuscript, prepared the figures and approved the final version of the manuscript. AC was involved in the conception and design of the study, drafted the manuscript, critically reviewed the manuscript, edited the manuscript, prepared the figures and approved the final version of the manuscript. EC was involved in the conception and design of the study, critically reviewed the manuscript and approved the final version of the manuscript. APM and LPSP drafted the manuscript, critically reviewed the manuscript and approved the final version of the manuscript. CG was involved in acquisition, analysis and interpretation of data, critically reviewed the manuscript and approved the final version of the manuscript. RV was involved in the conception and design of the study, critically reviewed the manuscript and approved the final version of the manuscript. DV and LM were involved in the conception and design of the study, critically reviewed the manuscript, approved the final version of the manuscript and are guarantors for the entire piece of work.

## Acknowledgments

Not applicable.

## References

1. Espinosa N, Maceira E, Myerson MS (2008) Current concept review:

- Metatarsalgia. *Foot Ankle Int* 29: 871-879.
2. DiPreta JA (2014) Metatarsalgia, lesser toe deformities, and associated disorders of the forefoot. *Med Clin North Am* 98: 233-251.
  3. Espinosa N, Brodsky JW, Maceira E (2010) Metatarsalgia. *J Am Acad Orthop Surg* 18: 474-485.
  4. Nakagawa S, Fukushi JI, Nakagawa T, Mizu-Uchi H, Iwamoto Y (2016) Association of metatarsalgia after hallux valgus correction with relative first metatarsal length. *Foot Ankle Int* 37: 582-588.
  5. Stewart S, Ellis R, Heath M, Rome K (2013) Ultrasonic evaluation of the abductor hallucis muscle in hallux valgus: A cross-sectional observational study. *BMC Musculoskelet Disord* 14: 45.
  6. Hart ES, de Asla RJ, Grottkau BE (2008) Current concepts in the treatment of hallux valgus. *Orthop Nurs* 27: 274-289.
  7. Ibrahim T, Beiri A, Azzabi M, Best AJ, Taylor GJ, et al. (2007) Reliability and validity of the subjective component of the american orthopaedic foot and ankle society clinical rating scales. *J Foot Ankle Surg* 46: 65-74.
  8. Kitaoka HB, Alexander IJ, Adelaar RS, Nunley JA, Myerson MS, et al. (1994) Clinical rating systems for the ankle-hindfoot, midfoot, hallux, and lesser toes. *Foot Ankle Int* 15: 349-353.
  9. Choi JY, Yeom JW, Suh YM, Suh JS (2017) Comparison of postoperative height changes of the second metatarsal among 3 osteotomy methods for hallux valgus deformity correction. *Foot Ankle Int* 38: 20-26.
  10. Gooding GA, Stess RM, Graf PM, Moss KM, Louie KS, et al. (1985) Heel pad thickness: Determination by high-resolution ultrasonography. *J Ultrasound Med* 4: 173-174.
  11. Graf PM, Farac K, Stess RM, Gooding GA (1988) High-resolution ultrasound in the preoperative and postoperative assessment of distal metatarsal osteotomy. Preliminary report. *Invest Radiol* 23: 827-831.
  12. Bygrave CJ, Betts RP (1992) The plantar tissue thickness in the foot: A new ultrasound technique for loadbearing measurements and a metatarsal head depth study. *Foot* 2: 71-78.
  13. Wang CL, Hsu TC, Shau YW, Shieh JY, Hsu KH (1999) Ultrasonographic measurement of the mechanical properties of the sole under the metatarsal heads. *J Orthop Res* 17: 709-713.
  14. Banal F, Gandjbakhch F, Foltz V, Goldcher A, Etchepare F, et al. (2009) Sensitivity and specificity of ultrasonography in early diagnosis of metatarsal bone stress fractures: A pilot study of 37 patients. *J Rheumatol* 36: 1715-1719.
  15. Uzel M, Cetinus E, Bilgic E, Ekerbicer H, Karaoguz A (2006) Comparison of ultrasonography and radiography in assessment of the heel pad compressibility index of patients with plantar heel pain syndrome. Measurement of the fat pad in plantar heel pain syndrome. *Joint Bone Spine* 73: 196-199.