

## Multiple Nabothians Cysts in a 52 Years Old Woman with Multiple Myofibromas

Amsiguine Najwa\*, Iraqi Zaynab, Halfi Mohamed Ismail and Moatassim billah nabil

Department of Central Radiology, Hospital Ibn Sina, Faculty of medicine, Rabat , Morocco

### Abstract

Nabothian cysts are mucinous benign cysts that are formed due to the accumulation of cervical mucus inside blocked cervical crypts. While the presence of small-sized Nabothian cysts is usually clinically asymptomatic and requires no treatment or intervention, the diagnosis of larger or multiple Nabothian cysts can be mistaken with malignant tumors, including mucin producing carcinomas such as Adenoma malignum. We report the case of a large multiple Nabothian cyst that was correctly diagnosed preoperatively using ultrasonography and magnetic resonance imaging (MRI) in a woman with 2 large myofibromas.

**Keywords:** Naboth; Multiple cysts; Magnetic Resonance Imaging.

### Image Article

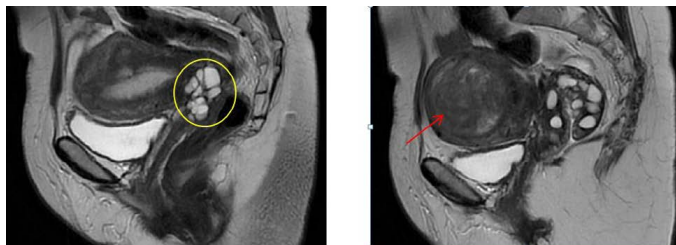
Nabothian cysts are small, asymptomatic, non-neoplastic cervical cysts that are frequently seen in women of reproductive age. No medical intervention is needed since they resolve themselves spontaneously [1]. In our rare case in which a woman of 52 years old with a recent diagnosis of 2 myofibroma via pelvic ultrasound has undergone an MRI to further characterize these lesions. The MRI showed in addition to 2 voluminous fibromas multiple cysts that caused compression of surrounding viscera and further aggravated her symptoms related to mass effect such as constipation and urinary incontinence (Figure 1).

Large and/or multiple nabothian cysts, especially deep nabothian cysts, are difficult to distinguish from minimal-deviation adenocarcinoma (MDA) [2]. Furthermore, neither cytology nor

histology helps substantially discern the two entities. Very few case reports featuring those two entities have been trying to characterize them using MRI. Overall nabothian cysts are usually low on T1WI and high on T2WI, the cyst walls are smooth and not enhanced with intravenous Gadolinium. In contrast to MDA, the absence of a watery discharge and an MR image displaying a round or oval cyst without enhancement after intravenous gadolinium are helpful in the diagnosis of nabothian cysts.

### References

1. Shroff N, Bhargava P (2021) Giant nabothian cysts: A rare incidental diagnosis on MRI. Radiol Case Rep 16: 1473-1476.
2. Oguri H, Nagamasa M, Chiaki I, Tomoaki K, Yorito Y, et al. (2004) MRI of endocervical glandular disorders: three cases of a deep nabothian cyst and three cases of a minimal-deviation adenocarcinoma. Magn Reson Imaging 22: 1333-1337.



**Figure 1:** Sagittal MRI on T2-weighted sequence showing multiples small cystic lesions ranging in diameter from 7 to 14 mm (yellow circle) located in the endocervical canal with no noted enhancement, in addition to a voluminous myometrial mass lateralised on the right, well limited, High on T2WI, the lesion appears adjacent to the serosa with a homogenous enhancement reflecting a stage FIGO 5 myofibroma measuring 71x 63 mm (red arrow).

\*Corresponding author: Amsiguine Najwa, Department of Central Radiology, Hospital Ibn Sina, Faculty of medicine, Rabat , Morocco, E-mail: thealmanac101@gmail.com; ismail.m.halfi@gmail.com

**Received:** 01-Mar-2022, Manuscript No. roa-22-55844; **Editor assigned:** 03-Mar-2022, PreQC No. roa-22-55844(PQ); **Reviewed:** 17-Mar-2022, QC No. roa-22-55844; **Revised:** 22-Mar-2022, Manuscript No. roa-22-55844(R); **Published:** 29-Mar-2022, DOI: 10.4172/2167-7964.1000368

**Citation:** Najwa A, Zaynab I, Ismail HM, Nabil MB (2022) Multiple Nabothians Cysts in a 52 Years Old Woman with Multiple Myofibromas. OMICS J Radiol 11: 368.

**Copyright:** © 2022 Najwa A, et al. This is an open-access article distributed under the terms of the Creative Commons Attribution License, which permits unrestricted use, distribution, and reproduction in any medium, provided the original author and source are credited.