

## Lethal Acetaminophen Poisoning Related to Error Prescription: Medico Legal Implications - About a Case Report

Mesrati MA<sup>1\*</sup>, Mahjoub Y<sup>1</sup>, Boussaid M<sup>1</sup>, Saadoui H<sup>2</sup>, Moussa A<sup>3</sup>, Douki W<sup>2</sup>, Chadly A<sup>1</sup>, HajSalem N<sup>1</sup> and Aissaoui A<sup>1</sup>

<sup>1</sup>Department of Forensic Medicine, University of Monastir, Taher Sfar Hospital, Tunisia

<sup>2</sup>Department of Toxicology, University of Monastir, Fattouma Bourguiba Hospital, Tunisia

<sup>3</sup>Department of Cytology, University of Monastir, Fattouma Bourguiba Hospital, Tunisia

\*Corresponding author: Mesrati MA, Department of Forensic Medicine, University of Monastir, Taher Sfar hospital, Tunisia, Tel: 21673109000; E-mail: mesrati.amin@gmail.com

Received date: July 01, 2017; Accepted date: July 17, 2017; Published date: July 26, 2017

Copyright: © 2017 Mesrati MA, et al. This is an open-access article distributed under the terms of the Creative Commons Attribution License, which permits unrestricted use, distribution, and reproduction in any medium, provided the original author and source are credited.

### Abstract

Acetaminophen poisoning, leading to death, is a serious and dramatic accident for even the family and pediatricians. Prescribing error can engage the physician's responsibility. In this context, we report a case of lethal acetaminophen poisoning related to error prescription, occurred in an infant with underlying liver disease and we discuss its medico-legal implications. He was an 11 month-old boy, without medical history, who was presented to his pediatrician for a nasopharyngitis with gastroenteritis of three days duration. The prescription involved two drug forms of Acetaminophen. The total prescribed dose was 270 mg/kg/day. The death occurred after two days. A blood analysis tested before his death showed a major hepatic cytolysis with toxic level of acetaminophen. Forensic autopsy has been ordered. At dissection, the liver was palish and hemorrhagic. Toxicological screening showed a high level of acetaminophen (79 mg/l). Histological examination concluded to diffuse microvacuolar steatosis. This case report highlights the risk of hepatotoxicity of acetaminophen. This complication is even more serious if the child already has a congenital, unknown liver disease. The physician and the pharmacist's liability, in this case, would be incurred even with partial causal link.

**Keywords:** Acetaminophen; Poisoning, Hepatotoxicity; Medico; Legal aspects

### Introduction

Acetaminophen, also known as paracetamol, is one of the most commonly used drugs in childhood diseases because of its efficacy and being well-established compared to the aspirin. According to international guidelines, it is considered as first-line therapy for the management of fever and mild-to-moderate pain for infants [1]. It has an excellent safety profile when administered in proper therapeutic doses. However, it still remains the most common substance involved in childhood poisoning [2]. Toxicity with paracetamol may occur in cases of misuse, unintended inappropriate dosage or the failure to recognize children at increased risk in whom standard paracetamol doses have been administered [3]. When this therapeutic misadventure results from a prescribing error, it can engage the physician's responsibility.

In this context, we report a lethal case of acetaminophen poisoning which occurred in an infant with underlying liver disease and we discuss the medico-legal implications.

### Case Report

M.B is an 11-month-old boy, without a past medical history, weighing 10 kg. His birth history was unremarkable. His mother, aged 37 years old, had been well during pregnancy with no history of medication. He was the second child of unrelated parents and he had a 10-year-old brother who was well. He was presented to his pediatrician for a nasopharyngitis with gastroenteritis for three days. He was

medicated accordingly. The prescription involved two drug forms of Acetaminophen (rectal suppositories and syrup). The total dose prescribed was 270 mg/kg/day (Figure 1).

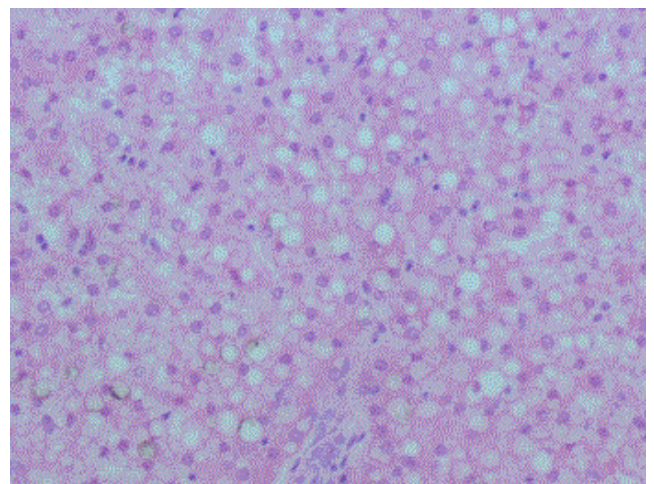


Figure 1: Diffuse Micro vacuolar Steatosis (HEX100).

After two days, he was admitted into the emergency room for malaise. He developed a cardio-respiratory arrest without response to the intensive care resuscitation procedures. A blood sample test analysed just before his death (12 h after taking the last dose of paracetamol) showed a major hepatic cytolysis (ALAT: 7663 UI/L -

ASAT: 9910 UI/L) and toxic level of acetaminophen (73 mg/l) without any other abnormalities. Forensic autopsy was ordered. The external examination revealed no dysmorphic features. The biometrical parameters (height, weight and cephalic perimeter) were within normal range. At dissection, the liver was palish and hemorrhagic. No infectious disease was detected macroscopically. Toxicological screening (22 h after death occurred) revealed a high level of acetaminophen (79 mg/l). Histological examination concluded to diffuse microvacuolar steatosis with centrilobular necrosis.

## Discussion

The availability of acetaminophen in many medical preparations and the contra-indication of aspirin containing products for pediatric use, have made acetaminophen one of the most commonly used analgesic-antipyretic medication in current pediatric medicine [4]. Although it is safe, efficacious and well-established, its ubiquitous presence in the house and easy availability makes it a substance with high potential for harm, both accidentally and non-accidentally [5]. In fact, paracetamol is one of the most commonly implicated substances for poisoning in both children and adults [6]. In children under the age of 5 years acute paracetamol toxicity is usually due to accidental ingestion. In some of cases, the children were given the drug by a parent for therapeutic effect at doses well above those recommended for age and weight. It may occasionally be due to attempted suicide in older children and is rarely due to intentional poisoning for infants. Children may be less prone to paracetamol hepatotoxicity because of developmental differences in the drug's metabolism and its pathways of detoxification [2]. In fact, acetaminophen is primarily metabolized by conjugation in the liver to non-toxic compounds that are eliminated in the urine. In acute overdose or when the maximum daily dose is exceeded over a prolonged period, metabolism by conjugation becomes saturated, and excess acetaminophen is oxidatively metabolized by the CYP enzymes (CYP2E1, 1A2, 2A6, and 3A4) to the hepatotoxic reactive metabolite, N-acetyl-p-benzoquinoneimine (NAPQI). NAPQI has an extremely short half-life and is rapidly conjugated with glutathione and then renal excreted. Under conditions of excessive NAPQI formation or a reduction in glutathione stores, NAPQI covalently binds with liver proteins to cause cellular injury. The amount of toxic metabolite produced and the ability of the liver to remove this metabolite before it binds to liver protein influence the extent of liver injury. Thus, the production of NAPQI, in excess of an adequate storage of conjugating glutathione in the liver tissue, is associated with hepatocellular damage, necrosis, and hepatic failure. Similar enzymatic reactions occur in extrahepatic organs, such as the kidney, and can contribute to a certain degree of extrahepatic organ dysfunction [3].

Acetaminophen has a narrow safety margin. This means that there is little difference between the maximum recommended daily dose and a potentially harmful dose. There is scientific agreement that taking a large amount of acetaminophen over a short period of time causes liver injury, but there are varying views on the specific threshold dose for toxicity [7].

Some individuals may be especially prone to liver injury from acetaminophen. The maximum amount of acetaminophen that can be safely ingested may not be the same for all people. Available data suggest that some individuals, especially those who use alcohol or have liver disease, may have a greater susceptibility to the effects of the toxic metabolite because they produce more of the metabolite or because they are unable to clear it from the body easily [8]. Individuals with

increased susceptibility may experience toxic effects at lower acetaminophen doses than others. In the present case, histological examination concluded to diffuse micro vacuolar steatosis which suggests a congenital hepatic disease or metabolic problems that can potentially aggravate hepatic toxic effects.

Acetaminophen poisoning is histologically manifested by a hepatic necrosis, which is essentially centrolobular. Necrosis may be diffused and associated with a non-specific inflammatory infiltrate. On the other hand, hepatic steatosis is not described in cases of poisoning by paracetamol. Congenital steatosis is most often secondary to mitochondrial genetic pathologies, notably diseases of fatty acid beta-oxidation. This is a large group of diseases that can be treated with hepatic impairment. Most transport molecules and enzymes involved in the mitochondrial uptake of fatty acids or their beta-oxidation may be affected by genetic abnormalities. This results in insufficient degradation of the non-esterified fatty acids and the occurrence of hepatic micro vesicular steatosis [9]. In the case presented, metabolic and genetic studies were not made for lack of resources.

An acetaminophen plasma level is the most important parameter used to determine the risk of hepatotoxicity and therefore the need for n-acetylcysteine therapy. The Rumack/Matthew nomogram predicts risk of hepatotoxicity based on measured plasma or serum acetaminophen concentration at a specified post ingestion time [10]. The graph applies only to plasma levels following a single acute overdose obtained 4-24 hours after ingestion; levels drawn before 4 hours may not represent peak levels and therefore are not recommended. Acetaminophen Poisoning is responsible for cytolytic hepatitis. Transaminases levels are also a very important element of predict prognosis. Indeed, toxicity is very likely if the ASAT and/or ALAT exceed 1000 IU/L [11]. In this case, the pre-mortem dosage of transaminases showed rates higher than 10x normal, which already determines a very poor prognosis. Toxicological screening (22 h after death occurred) revealed a high level of acetaminophen (79 mg/l) which is toxic according to Rumack/Matthew nomogram (Figure 2) [12].

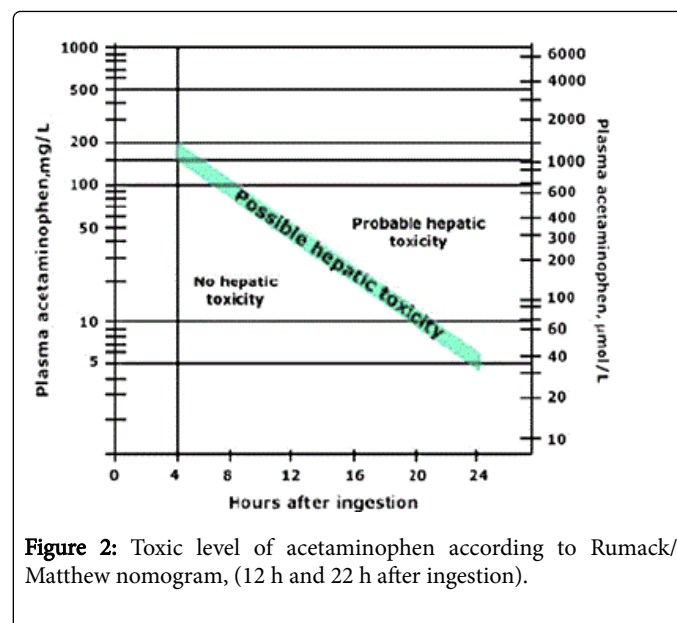


Figure 2: Toxic level of acetaminophen according to Rumack/Matthew nomogram, (12 h and 22 h after ingestion).

Error medication is an avoidable situation that has many medico-legal implications. It was stated as an example of medical inattention.

Nowadays, people are more aware of their rights and they can litigate the prescriber who will face charges of negligence or imprudence.

For medico-legal purposes, medication error is defined as a fact, situation or deviation from a standard of practice likely to cause harm or adverse drug event in the patient. Four major typologies of prescribing errors emerge: errors in administration modalities, interactions, prescription of unnecessary drugs and especially overdoses as in the reported case [13]. Several factors can contribute to this. For children in particular, the need of a precise dosage often results in calculation errors. Also poor communication with parents, lack of information, insufficient knowledge or confusion of drugs and their dosage forms increase this risk [14]. The usual mistake made by the parents is failure to read or understand the prescription instructions [15].

The claims about medical malpractice can be usually subject of trials in both compensation trial and penal judgement. The doctor can be liable in civil law for paying compensation and damages. This situation requires the association of damage, committed fault, and a cause-effect relationship. The imputability is retained only if an underlying disease that may interfere in the mechanism of death is not present. The existence of the latter would bring the process into a mechanism of revelation or aggravation rather than the initial genesis. Steatosis micro vacuolar analysed in the present case, make experts ask questions about its origin and its intervention in the determination of death. Paracetamol with hepatic toxicity can aggravate the pathological ground of the child. The result is that the overdose of paracetamol prescribed by the attending physician precipitated the course of the disease, which in the absence of this requirement would be advanced at low noise and gradually. Even if the causal link in this case is not total, this does not relieve the attending physician of his responsibility. The claim for compensation by the rights holders, leads to a payment of "damages" by the author of the fault. The latter, in the case of a liberal practice, may be covered by his insurance. The Disciplinary Council of the Medical Association may also rule on the case and order the physician for breach of an ethical obligation. The physician must ensure that the right of every person to receive the most appropriate care at his/her age and condition, in accordance with the rules of scientific art, is respected and does not entail risks disproportionate to the expected benefit. Furthermore, if the degree of the negligence is so gross and the doctor's act is careless as to endanger the life of the patient, he would also be made criminally liable. According to the Tunisian Criminal Code (TCC), doctors can be prosecuted under section 225 (involuntary assault by negligence or inattention). They are also punished for involuntary homicide, if death occurs, under section 217 of the TCC.

The pharmacist can also take responsibility. Indeed, he had the technical competence to identify an anomaly given the dosage or therapeutic context of the prescription. He was therefore, obliged to technically control the prescription and detect its imperfection. The pharmacist's fault is of extreme seriousness, since it reveals a notorious

lack of knowledge of the dosage of a medicine which is frequently used. When dispensing a prescribed medication, the pharmacist is subject to the duty of care and diligence. Before issuing a medication, the pharmacist must perform a number of checks and do not place undue reliance on doctors' prescriptions. As a result, the pharmacist and the paediatrician are consequently jointly and severally ordered to pay compensation for the heavy losses suffered.

In conclusion, hepatotoxicity due to paracetamol is a serious but well known complication. To avoid litigation, each professional must think carefully before writing a medical prescription to prevent the error as much as possible. For pediatric doctors, it is above all their responsibility to appropriate the recommendations drawn up from various learned institutions and adapt them to the organization of care.

## References

1. Kaufman DW, Kelly JP, Rosenberg L, Anderson TE, Mitchell AA (2002) Recent Patterns of Medication use in the Ambulatory Adult Population of the United States: The Slone Survey. *JAMA* 287: 337-344.
2. Penna A, Buchanan N (1991) Paracetamol Poisoning in Children and Hepatotoxicity. *Br J Clin Pharmacol* 32: 143-149.
3. Susan EF, Tarabar A (2014) Acetaminophen Toxicity. *Medscape Drugs, diseases and Procedures*. Medscape.
4. American Academy of Pediatrics (2001) Acetaminophen toxicity in children. *Pediatrics* 108: 1020-1024.
5. Ng KC (2003) Paracetamol Ingestions at the Children's Emergency Department-A Three Year Series. *Singapore Med J* 44: 79-83.
6. Meredith TJ, Newman B, Goulding R (1978) Paracetamol poisoning in children. *BMJ* 2: 478-479.
7. Food and Drug Administration (2009) Organ-Specific Warnings; Internal Analgesic, Antipyretic, and antirheumatic Drug Products for Over-the-Counter Human Use; Final Monograph. *Federal Register* 74: 19385-19409.
8. Heard K, Bui A, Mlynarchek SL, Green JL, Bond GR, et al. (2012) Toxicity from Repeated Doses of Acetaminophen in Children: Assessment of Causality and Dose in Reported Cases. *Am J Ther* 21: 174-183.
9. Mégarbane B, Deye N, Baud F (2007) Foie toxique: mécanismes lésionnels et thérapeutiques pharmacologiques spécifiques. *Reanimation* 16: 632-642.
10. Rumack BH, Matthew H (1975) Acetaminophen poisoning and toxicity. *Pediatrics* 55: 871-876.
11. Douglas DR, Sholal JB, Smilkstein MJ (1996) A pharmacokinetic comparison of acetaminophen products (Tylenol Extended Relief vs Regular Tylenol). *Acad Emerg Med* 3: 740-744.
12. Anne ML (2007) Acetaminophen Hepatotoxicity. *Clinics in Liver Disease* 11: 525-548.
13. Doherty K, Segal A, Mckinney PG (2004) The 10 Most Common Prescribing Errors: Tips on Avoiding the Pitfalls.
14. Kohn LT, Corrigan JM, Donaldson MS (2000) *To Err Is Human: Building a safer Health System*. National Academy Press. Washington.
15. Rivera-Penera T, Gugig R, Davis J, McDiarmid S, Vargas J, et al. (1997) Outcome of acetaminophen overdose in pediatric patients and factors contributing to hepatotoxicity. *The Journal of Pediatrics* 130: 300-304.