

## Kimura's Disease Presenting as a Post Cricoid Mass - A Diagnostic Challenge

Mohiyuddin SMA<sup>1</sup>, Raju K, Sumanth KR, Karunasagar A, Maruvala S, Chaudhary S and Thomas L

*Department of Otorhinolaryngology, Head and Neck Surgery, Sri Devaraj Urs Medical College, Tamaka, Kolar, Karnataka 563101, India*

**Corresponding author:** Mohiyuddin SMA, M.S, Professor and Head, Department of Otorhinolaryngology, Head and Neck Surgery, Sri Devaraj Urs Medical College, Tamaka, Kolar, Karnataka 563101, India, Tel: +91 9845373279; E-mail: [azeem\\_hn@yahoo.co.in](mailto:azeem_hn@yahoo.co.in)

**Received date:** August 28, 2017; **Accepted date:** September 13, 2017; **Published date:** September 20, 2017

**Copyright:** © 2017 Mohiyuddin SMA, et al. This is an open-access article distributed under the terms of the Creative Commons Attribution License, which permits unrestricted use, distribution and reproduction in any medium, provided the original author and source are credited.

### Abstract

Kimura's disease (KD) is a rare immune mediated chronic inflammatory disorder of unknown etiology which involves subcutaneous plane and is usually seen in parotid region. It is also known to affect cervical lymph nodes and pharynx. There has been no report of this disease isolated to post cricoid region. We report a case of hoarseness of voice in an elderly lady who was found to have a smooth mass in post cricoid region with forward displacement and fixity of right arytenoid. She had eosinophilia and biopsy revealed lymphoid hyperplasia with infiltration of eosinophils and vascular proliferation, suggestive of Kimura's disease. Diagnosis was confirmed by immunohistochemistry. She was treated with prednisolone at a dose of 1 mg per kg body weight per day for 3 weeks. Patient is symptomatically better and mass has not recurred after a period of 3 months.

**Keywords** Kimura's disease; Post cricoid region; Chronic inflammation; Granulation

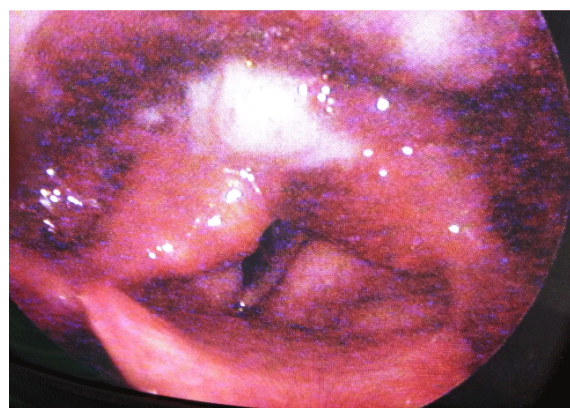### Introduction

Kimura's disease (KD) is a rare immune mediated chronic inflammatory disorder of unknown etiology. It commonly involves subcutaneous plane and is located in parotid region, adjoining the auricle and neck. There have been reports of this disorder in cervical lymph nodes, axilla and groin [1,2]. It usually affects Asian population particularly males in second and third decades of life. In salivary glands and neck it can mimic malignancy. It is characterized histologically by lymphoid hyperplasia, eosinophilic infiltrates and proliferation of capillaries. It is always associated with eosinophilia and raised serum IgE levels [3]. To the best of our knowledge, in literature, there are only two reports of Kimura's disease involving pharynx and larynx but none isolated to the post cricoid region [4,5]. We are reporting a case of Kimura's disease in an elderly lady presenting like a post cricoid mass.

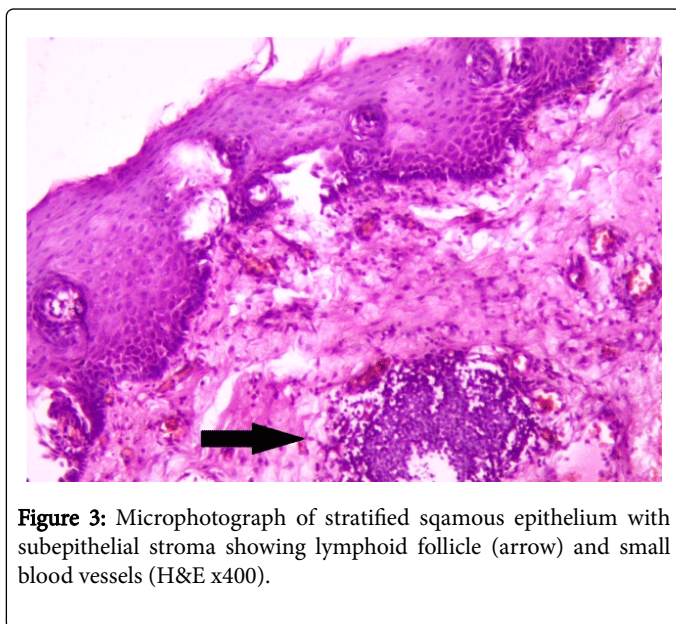
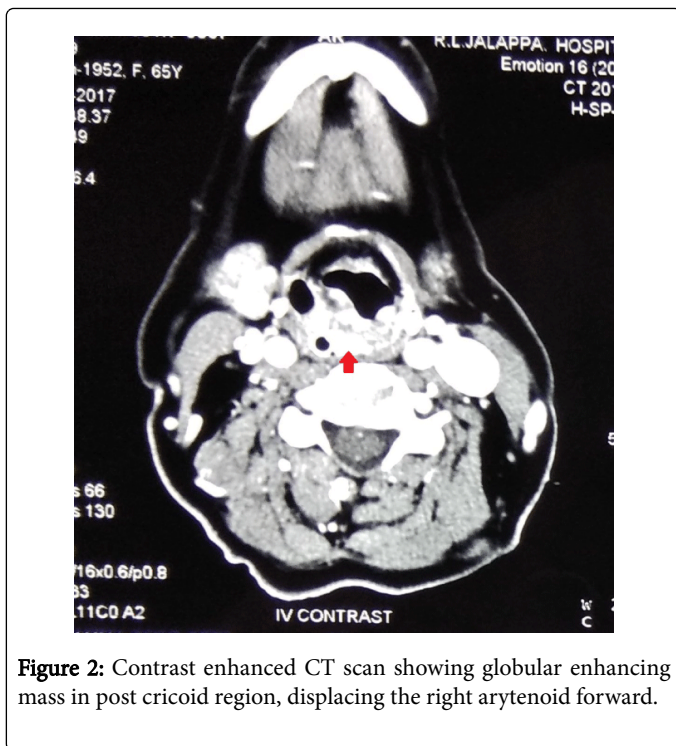
### Case Report

An elderly lady aged 65 years presented with dysphagia for solids of 3 months duration. It was associated with pain during swallowing and hoarseness of voice since 1 month. She had no history of dyspnoea or neck swelling. Videolaryngoscopy revealed edema of both arytenoids and false cords. The right arytenoid was pushed anteriorly with restricted movement. A globular mass with smooth mucosal surface was seen in postcricoid region, more towards right side (Figure 1). Contrast enhanced CT scan showed a smooth globular enhancing mass of 2.5 cm diameter in postcricoid region. This was suggestive of a benign lesion in post cricoid region (Figure 2). On direct laryngoscopy a smooth globular mass with restricted mobility was found in postcricoid region extending from upper border of arytenoid to the cricopharyngeal sphincter. Mobility of right arytenoid was restricted. Histopathological examination of the biopsy revealed benign

inflammatory lesion. A repeat biopsy was done resecting bulk of the postcricoid mass. Both biopsy specimens were reviewed by two senior pathologists. The final histopathology was reported as lymphoid hyperplasia with eosinophilic infiltrates and proliferation of capillaries suggesting Kimura's disease (Figure 3). This was confirmed by Immunohistochemistry. The patient was found to have eosinophilia and raised serum IgE levels. Patient was treated with prednisolone at a dose of 1 mg per kg body weight per day for a period of 3 weeks and later tapered down over 2 weeks. The dysphagia improved, however the mobility of right arytenoid remains restricted (Figure 4).



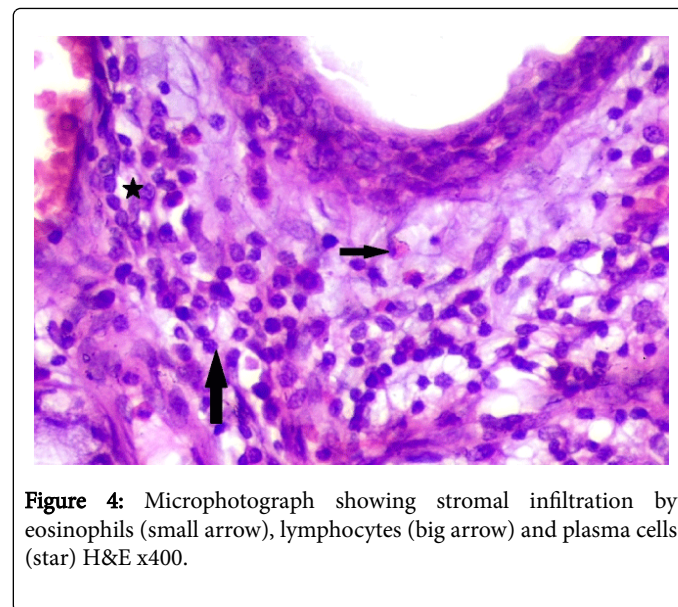
**Figure 1:** Videolaryngoscopic picture showing postcricoid mass, pushing right arytenoid with fixity of right cricoarytenoid joint.



## Discussion

Kimura in 1948 described a rare granulation tissue of unknown etiology mimicking a tumor [6]. It was characterized by lymphoid hyperplasia, vascular proliferation and infiltration of eosinophils and was associated with eosinophilia. Subsequently various cases were reported with similar histological picture and eosinophilia predominantly affecting Asians in the second and third decade of life. It usually involved the parotid region, neck, post auricular region, axilla and affected the subcutaneous plane. It mimics a tumor and is an immune mediated chronic inflammatory disorder marked by raised IgE levels. It has to be differentiated from angiolymphoid hyperplasia

with eosinophilia and low grade lymphoma. There have been few case reports of this disorder affecting the larynx and axilla. To the best of our knowledge there are only two case reports of Kimura's disease involving the pharynx.



Our patient had an isolated lesion of Kimura's disease involving the post cricoid region and posterior surface of right crico-arytenoid joint, thereby displacing the right arytenoid forward. There has been no report of Kimura's disease isolated to postcricoid region in literature. The pharyngeal cases reported by department of otorhinolaryngology, Singapore general hospital in 2000 [4] and by department of otorhinolaryngology, PSG medical college, Coimbatore [7] in 2014 involved the lateral wall of pharynx with bulk of disease in oropharynx.

Our patient was a diagnostic challenge as she was an elderly lady and presented with dysphagia to solids which was followed by hoarseness of voice. This clinical presentation mimicked postcricoid malignancy. The smooth globular lesion in postcricoid region had to be differentiated from other benign tumors, low grade lymphoma and angiolymphoid hyperplasia. The eosinophilic infiltrates among the lymphoid hyperplasia, along with raised serum IgE levels and absence of a definite plane around the tumor aroused our suspicion of Kimura's disease. This was confirmed by histopathology and immunohistochemistry. The histopathological picture and eosinophilia were similar to reports by various authors from South India, Singapore and few western countries. The patient responded well to steroids [prednisolone] as reported by various other authors. After 3 months follow up, patient is symptomatically better. However the arytenoid mobility remains restricted and long term follow up of the patient is required as this condition is known to recur. The treatment for recurrent disease involves repeated use of systemic steroids, immunosuppressive drugs like cyclophosphamide and cyclosporine [8]. Low dose radiotherapy (20-30 Gy) also helps as reported by Itami [9]. Few authors have also used antihistaminic drugs and leukotriene inhibitors as a part of treatment [10].

The aim of having reported this case was to highlight the rare diagnosis involving rare site thereby posing a diagnostic challenge.

## Conclusion

This patient with post cricoid mass was found to be a case of the rare Kimura's disease at a rare site. This posed a diagnostic challenge. Histopathological examination, eosinophilia, raised IgE levels and immunohistochemistry confirmed the diagnosis and ruled out low grade lymphoma and angiolymphoid hyperplasia. This is the only case report of Kimura's disease isolated to postcricoid region.

## References

1. Chusid MJ, Rock AL, Sty JR, Oechlerc HW, Bsted DJ (1997) Kimura's disease: An unusual cause of cervical tumor. *Arch Dis Child* 77: 153-154.
2. Takahashi S, Ueda J, Furukawa T (1996) Kimura disease. CT and MR findings. *Am J Neuroradiol* 17: 382-385.
3. Viswanatha B (2007) Kimura's disease in children: A 9 years' prospective study. *Int J Pediatr Otorhinolaryngol* 71: 1521-1525.
4. Chong VE, Balakrishnan A, Fong KW (2000) Kimura's disease of the pharynx. *Clin Radiol* 55: 649-651.
5. Yamamoto T, Minamiguchi S, Watanabe Y, Tsuji J, Asato R, et al. (2014) Kimura disease of the epiglottis: A case report and review of literature. *Head Neck Pathol* 8: 198-203.
6. Kimura T, Yoshimura S, Ishikawa E (1948) On the unusual granulation combined with hyperplastic changes of lymphatic tissue. *Trans Soc Patho Jpn* 37: 179-180.
7. Sharma C, Dayanand A, Nirmala V (2014) Kimura's disease of the pharynx - A case report of "unusual granulation" at an unusual location. *Int J Health Sci Res* 4: 288-292.
8. Sato S, Kawashima H, Kuboshima S, Watanabe K, Kashiwagi Y, et al. (2006) Combined treatment of steroids and cyclosporine in Kimura disease. *Pediatrics* 118: e921-e923.
9. Itami J, Arimizu N, Miyoshi T, Ogata H, Miura K (1989) Radiation therapy in Kimura's disease. *Acta Oncol* 28: 511-514.
10. Ohtsuka Y, Shimizu T, Fujii T, Sato T, Saito M, et al. (2004) Pramlukast regulates tumour growth by attenuating IL-4 production in Kimura disease. *Eur J Pediatr* 163: 416-417.