

Intra-Articular Calcaneal Fracture in Patient of 11 Years, What Treatment is the Most Adequate?

Peña Fernández MP* and Quijada Rodríguez JL

Department of Orthopedic Surgery and Traumatology, Hospital Virgen de la Luz, Cuenca, Spain

*Corresponding author: Peña Fernández MP, Department of Orthopedic Surgery and Traumatology, Hospital Virgen de la Luz, Cuenca, Spain, Tel: +34 969 17 99 00; E-mail: pilarpf1204@yahoo.es

Rec date: Jan 03, 2018; Acc date: Jan 19, 2018; Pub date: Jan 26, 2018

Copyright: © 2018 Peña Fernández MP, et al. This is an open-access article distributed under the terms of the Creative Commons Attribution License, which permits unrestricted use, distribution, and reproduction in any medium, provided the original author and source are credited.

Abstract

Calcaneal fractures in children are uncommon injuries. Most of such injuries are due to low impact traumas, and are usually slightly displaced and extra-articular. However, in the case of high impact trauma (a fall from a high place or a traffic accident), displaced intra-articular injuries can occur. Currently, there is no consensus about the most appropriate treatment for such injuries. We present the case of an 11-year-old patient who suffered a fall from 2 m high, having pain and functional impotence in the left foot. After a radiological study by simple radiography and CT, he is diagnosed of intra-articular fracture of displaced calcaneus. It was decided to apply a conservative treatment by immobilization and discharge during 8 weeks, obtaining satisfactory clinical and functional results after more than one year of follow-up.

Keywords: Calcaneal fracture; Children; pediatric fracture; Intra-articular fracture; Computed tomography

Introduction

Tarsal fractures in children are considered extremely rare and represent less than 1% of all fractures in childhood [1]. Calcaneal fractures are uncommon tarsal fractures that represent around 0.005-0.41% [1-11]. Few cases are available in the literature on the treatment of these fractures in children [5-9]; the first case was described in 1969 by Thomas [12], followed by another case by Moyson et al. [13] in 1971. In children, seventy-five percent of calcaneal fractures are caused by low-energy traumas [3,14,15], being usually extra-articular [7,15] and little displaced [8], and they rarely affecting the subtalar joint. However, other times, when the trauma is more violent [9], due to a fall from a high place or to a traffic accident, more serious joint injuries occur [3,6,8,14,15]. When dealing with calcaneal fractures in children, we must bear in mind that it is an immature bone, which gives it some peculiar characteristics [3,12,16]. On the one hand, the greater thickness of the cartilage offers greater elasticity, so the calcaneus has greater power to recover the original form, as it occurs to a greater or lesser degree in child's fractures [3,10]. On the other hand, we must not forget the great capacity of remodeling that the immature bone has [1,3,16,17]. A growing number of publications suggest that many pediatric calcaneal fractures might have been overlooked in the past. It has been described that between 20-68% of these injuries could pass unnoticed [2,4,6,7,18,19]. Radiographic findings can be very subtle, since many of these fractures have little displacement. It is advisable, in cases with clinical suspicion, to perform the three classic radiographic projections of the calcaneus (dorsal-plantar, lateral and axial) [3,9,17,20]. In the case of confirming the joint fracture, it is indicated to perform a CT scan to assess more accurately the degree and direction of the displacement [3,15]. The objective of this publication is to relate and discuss the diagnosis and treatment of a calcaneal fracture in a child, what is an atypical presentation despite the high energy trauma system.

Case Report

An 11-year-old male patient who was referred to the Emergency Department of the Hospital after a casual fall from approximately 2 meters high, landing on his feet, as he referred. The physical examination showed he was conscious and oriented. After the general examination, a swelling and bruising at the level of the left heel accompanied by pain and functional impotence for walking and mobilization of the ankle are highlighted. Mobility, sensitivity and distal vascular conserved. After a complete radiological study, an intra-articular left calcaneal fracture with a Böhler angle of 40° and a Gissane angle of 109° was diagnosed, type 5B of the classification of pediatric calcaneal fractures (compression fracture of the subtalar joint with joint depression) (Figure 1).

The study was complemented by performing a CT scan showing a complex fracture of the calcaneus with involvement of the subtalar joint, crushing and sagging of the articular surface of the thalamus, fracture of the sustentaculum tali and the body of the calcaneus with multiple fragments (type IV of the Sanders' classification) (Figure 2). In the emergency room, the extremity was immobilized with a suropedic splint and then hospital admission to monitor the edema and compartment syndrome.

After evaluating the case, conservative treatment was decided. The patient remained immobilized with suropedic splint, discharge for 8 weeks and subsequent rehabilitation. The rehabilitation consisted of 20 sessions of physiotherapy in order to retrain the gait and get stretching of the Achilles tendon and plantar fascia. Six weeks after the removal of the splint, the patient did sports and returned to normal life. During the periodical controls, a satisfactory radiological evolution with preservation of the subtalar joints and the Böhler angle (38°) was observed (Figure 3). After more than one year of follow-up, the patient has a normal life, is asymptomatic and has complete joint mobility. No obvious deformity or precise use of plantar orthosis for walking.

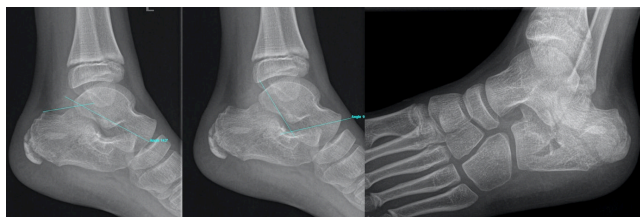

Figure 1: Simple radiograph showing the intra-articular fracture of the calcaneus with Böhler angle of 40° and Gissane angle of 109°, type 5B of the classification of pediatric calcaneal fractures (compression fracture of the subtalar joint with joint depression).

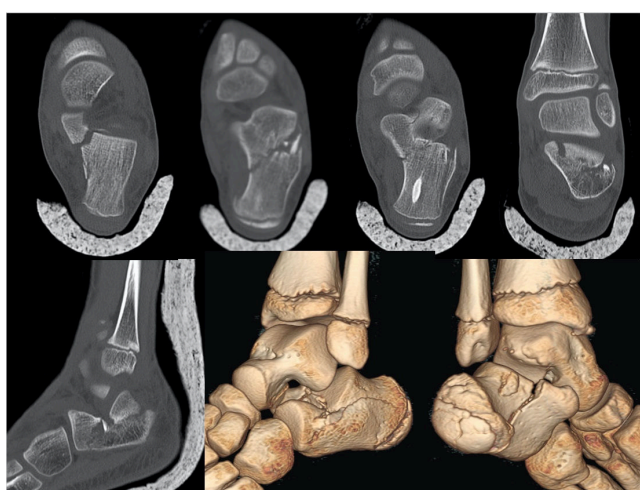


Figure 2: CT showing a complex fracture of the calcaneus with involvement of the subtalar joint, crushing and sagging of the articular surface of the thalamus, fracture of the sustentaculum tali and the body of the calcaneus with multiple fragments (type IV of the Sanders classification).

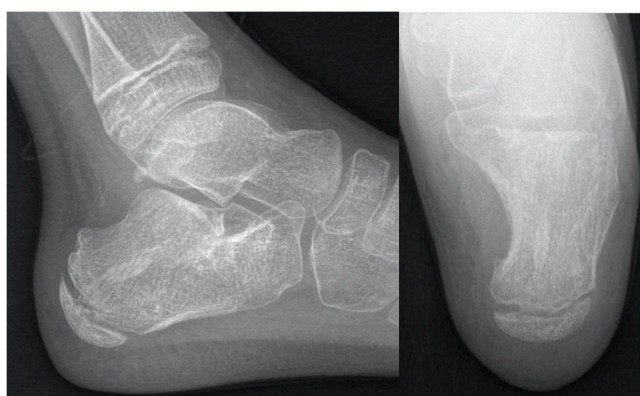

Figure 3: Simple radiography after more than 12 months of follow-up.

Discussion

Calcaneal fractures in children are very rare, and those with intra-articular displacement are even less so. For this reason, so they couldn't be unnoticed, in their diagnosis it is necessary to have a high clinical suspicion and to base on image techniques such as the classic radiographic images of the calcaneus (dorsal-plantar, lateral and axial), CT and MRI [3,9,15,17,20]. In addition, a quarter of patients have associated injuries of the soft parts of the ankle and foot, and in a third of them also other fractures, such as fractures of the same lower limb below the knee, fractures of the forearm, vertebrae and pelvic ring [1,10,11,16,21]. These associated injuries are less frequent the younger the child is [16,21].

Historically, the treatment of these fractures in children has been orthopedic, obtaining satisfactory results. This is due to several factors: the ability to reshape, low-energy trauma in most cases and the great cartilaginous elasticity of the calcaneus mentioned before [1,3,16,17].

Several case series studies have suggested that children with non-displaced or minimally displaced intra-articular fractures can be treated conservatively, with good clinical outcomes [1,9,12,14,18,19,21-26]. Some authors, such as Thomas [12], defend the conservative treatment consisting of immobilization and discharge during 4 to 6 weeks. This therapeutic option is defended because those fractures with involvement of the Böhler angle are later compensated by the remodeling of the articular surfaces of the calcaneus and talus when children grow [1,3,16,17,19]. Thomas suggested that children under 10 years old have sufficient potential for remodeling joint damage on the surface of the calcaneus, so that this angle is corrected, obtaining a subtalar joint with a relatively conserved anatomy and a maintained hind foot function [12,22,27].

Brunet and colleagues [22] reviewed the late results, at 16.8 years (on average) after the injury, of the treatment of calcaneal fractures in 17 children (19 fractures). With the exception of one patient, all fractures were treated conservatively. All patients, except two, had full or slightly reduced mobility of the subtalar joint, with unrestricted foot function, including the ability to walk painlessly on irregular surfaces. The radiological abnormalities of the hindfoot were common; there were two cases of post-traumatic osteoarthritis. The results suggest that almost all children achieve excellent long-term functional results with conservative treatment and that surgery should only be used in adolescents with severe displacement.

On the other hand, other authors such as Sangüesa [16] argue that a fracture of the calcaneus in a child that depresses or simply interrupts the joint requires a perfect reconstruction of the joint surface. The surgical treatment of these fractures in the pediatric age has been poorly developed due to its infrequent frequency, existing now great controversy about it [1,3,10,11,15,28]. They refer that, considering that children will experience the result of the treatment used for these fractures throughout their life and that the standard treatment for adults is surgical reduction to restore the anatomical configuration, the only reason not to treat intra-articular fractures surgically displaced in children (displacement greater than 4 mm or a posterior space of more than 1 cm in tongue-like fractures) [6,8,15] is that there are difficulties in obtaining or maintaining the reduction, or that they present preoperative contraindications or postsurgical complications, because few studies have specifically addressed intra-articular fractures with substantial displacement in the immature skeleton and have not compared children with adults [19,22]. However, it is not clear to other authors that skeletally immature patients experience the same benefits

of a surgical intervention to obtain an anatomic reduction than in adulthood [15,17,29].

In the literature, we find several surgical treatments for displaced intra-articular calcaneal fractures in children. Open reduction and plate osteosynthesis [3,4,6,7,9,17,29-32], reduction and osteosynthesis with cannulated screws [16,31], closed reduction and osteosynthesis with Kirschner wires (K) [11,32], reduction using the Essex-Lopresti technique and osteosynthesis with Steinmann [10], and combination of techniques such as external fixator type Ilizarov and osteosynthesis with K needles [5] or reduction and osteosynthesis with cannulated screws and K needles [8]. In all cases good clinical and radiological results are obtained. But all these techniques are not free of complications. The injury of the periosteum can cause a defective union and a delayed healing, as well as infection and chronic postoperative pain.

Conclusions

Calcaneal fractures in children are rare because this bone has a greater cartilaginous structure at this age, greater elasticity and more density trabecular bone. These factors dissipate the forces transmitted through this bone. In addition, children have a high elasticity in their bone structure and a high capacity for remodeling.

The choice of treatment is unanimous in the case of non-displaced fractures, choosing an orthopedic treatment with immobilization and discharge. However, there is controversy among the displaced fractures. Some authors defend the non-surgical posture given the bone remodeling capacity. Nonetheless, other authors, based on the foundations of it, defend the anatomical reduction, especially in children older than 10 years, to avoid aftermath in adulthood. The lack of studies with long-term follow-up and the possibility of performing both treatments make that surgeons can choose one of these options.

In our case, a conservative treatment was performed by splinting and discharging for 8 weeks, obtaining a satisfactory clinical and radiological result after more than one year of follow-up.

References

1. Guterres LW, Ribeiro DA, Ribeiro TA (2015) An atypical calcaneal fracture in a child: A literature review concerning the treatment. *J Clin Med Res* 7: 52-55.
2. Hensinger RN, Beaty JH (1992) Operative management of lower extremity fractures in children. American Academy of Orthopaedic Surgeons, Rosemont, Illinois, USA.
3. López PM, Fernández IA, Traverso GL, González HJ, Rodríguez-de la Cueva JM (2013) Calcaneal fractures in the child: Conservative vs. surgical treatment. *Rev Traum Ort* 30: 71-75.
4. Tudor A, Sestan B, Nemeč B, Prpic T, Rubinic D (2003) Intra-articular calcaneal fracture in a 14-year-old competing skier: Case report. *Croat Med J* 44: 764-766.
5. Faroug R, Stirling P, Ali F (2013) A novel technique for closed reduction and fixation of paediatric calcaneal fracture dislocation injuries. *Case Rep Orthop* 2013: 1-4.
6. Al-Ashhab ME (2015) "ORIF" for displaced intra-articular calcaneal fractures in children. *Foot* 25: 84-88.
7. Pickle A, Benaroch TE, Guy P, Harvey EJ (2004). Clinical outcome of pediatric calcaneal fractures treated with open reduction and internal fixation. *J Pediatr Orthop* 24:178-180.
8. Schantz K, Rasmussen F (1987) Calcaneus fracture in the child. *Acta Orthop Scand* 58: 507-509.
9. Rodríguez HP, Santana RS, Pastor-de ÁE (2012) Bilateral calcaneal fracture in pediatric age. About a case. *Rev Traum Ort* 29: 9-15.
10. Dudda M, Kruppa C, Gemann J, Seybold D, Schildhauer TA (2013) Pediatric and adolescent intra-articular fractures of the calcaneus. *Orthop Rev* 5: 82-85.
11. Thomas HM (1969) Calcaneal fracture in childhood. *Br J Surg* 56: 664-666.
12. Moyson F, Sand EA, Godart S (1971) Accidents involving children: Etiology and prevention. *Brux Med* 51: 857-874.
13. Wiley JJ, Proft A (1984) Fractures of the os calcis in children. *Clin Orthop Relat Res* 188: 131-138.
14. Rammelt S, Godoy-Santos AL, Schneiders W, Fitze G, Zwipp H (2016) Foot and ankle fractures during childhood: Review of the literature and scientific evidence for appropriate treatment. *Rev Bras Ortop* 51: 630-639.
15. Sangüesa MJ, Maruenda JJ, Darder A, Gascó J (1989) Comminuted intra-articular calcaneus fracture in a 6-year-old girl. Surgical treatment. *Rev Esp Cir Ost* 191: 8.
16. Summers H, Ann Kramer P, Benirschke SK (2009) Pediatric calcaneal fractures. *Orthop Rev* 1: 9.
17. Ishikawa SN (2005) Conditions of the calcaneus in skeletally immature patients. *Foot Ankle Clin* 10: 503-513.
18. Mora S, Thordarson DB, Zions LE, Reynolds RA (2001) Pediatric calcaneal fractures. *Foot Ankle Int* 22: 471-47.
19. Rasmussen F, Schantz K (1986) Radiologic aspects of calcaneal fractures in childhood and adolescence. *Acta Radiol Diagn* 27: 575-580.
20. Schmidt TL, Weiner DS (1982) Calcaneal fractures in children: An evaluation of the nature of the injury in 56 children. *Clin Orthop* 171: 150-155.
21. Brunet JA (2000) Calcaneal fractures in children long term results of treatment. *J Bone Joint Surg* 82: 211-216.
22. Walling AK, Grogan DP, Carty CT, Ogden JA (1990) Fractures of the calcaneal apophysis. *J Orthop Trauma* 4: 349-355.
23. Matteri RE, Frymoyer JW (1973) Fracture of the calcaneus in young children: Report of 3 cases. *J Bone Joint Surg Am* 55: 1091-1094.
24. Inokuchi S, Usami N, Hiraishi E, Hashimoto T (1998) Calcaneal fractures in children. *J Pediatr Orthop* 18: 469-474.
25. De Beer JD, Maloon S, Hudson DA (1989) Calcaneal fractures in children. *S Afr Med J* 76: 53-54.
26. Mayr J, Peicha G, Grechening W, Hammerl R, Weiglein A, et al. (2006) Fractures and dislocations of the foot in children. *Clin Podiatr Med Surg* 23: 167-189.
27. Abdelgawad AA, Kanlic E (2015) Minimally invasive (sinus tarsi) approach for open reduction and internal fixation of intra-articular calcaneus fractures in children: Surgical technique and case report of two patients. *J Foot Ankle Surg* 54: 135-139.
28. Petit CJ, Lee BM, Kasser JR, Kocher MS (2007) Operative treatment of intraarticular calcaneal fractures in the pediatric population. *J Pediatr Orthop* 27: 856-862.
29. Yu GR, Zhao HM, Yang YF, Zhou JQ, Li HF (2012) Open reduction and internal fixation of intra-articular calcaneal fractures in children. *Orthopedics* 35: 874-879.
30. Lu D, Zhu SY, Yang J, Chen H, Sun LJ (2016) IA comparison of two minimally invasive procedures for intra-articular displaced calcaneal fractures in older children. *Acta Orthop Belg* 82: 779-786.
31. Zeman J, Matějka J (2014) Surgical treatment of intra-articular calcaneal fractures in children. *Acta Chir Orthop Traumatol Cech* 81: 407-411.
32. Huang ZS, Zhao Z, Ji YY, Li KL, Zheng JH, et al. (2011) Effective analysis of percutaneous reduction and Kirschner pin fixation for the treatment of intraarticular fractures of the calcaneus in children. *Zhongguo Gu Shang* 24: 834-837.