

Infectious Thoracic Aortitis: A Case Report

Chemchik H^{1*}, Achèche W¹, Amara A¹, Abidi S¹, Kotas C², Alimi F² and Said R¹

¹Departement of Anesthesiology, Sahloul University Hospital, Sousse, Tunisia

²Cardiothoracic Surgery Departement, Sahloul University Hospital, Sousse, Tunisia

*Corresponding author: Heithem Chemchik, Anesthesiology Departement, Sahloul University Hospital, Route de ceinture, 4054, Sousse, Tunisia, Tel: +216 25 575 676; E-mail: heithem_1@yahoo.fr

Rec date: Jul 24, 2014; Acc date: Nov 21, 2014; Pub date: Nov 28, 2014

Copyright: © 2014 Chemchik H, et al. This is an open-access article distributed under the terms of the Creative Commons Attribution License, which permits unrestricted use, distribution, and reproduction in any medium, provided the original author and source are credited.

Abstract

Aortitis is a term that refers to infectious or noninfectious conditions in which there is abnormal inflammation of the aortic wall. Here we report the case of a 32 years old woman who presented a diabetic Ketoacidosis. The thoraco abdominal CT scan showed endoluminal defect of the thoracic aorta with splenic and reanl infarction. Transesophageal echocardiogram showed a normal aortic and mitral valve and an obstructive vegetation lining the aortic wall. Blood culture were negative, Methicillin-resistant Staphylococcus aureus was isolated. The patient died after surgery (vegetectomy).

Keywords: Thoracic aorta; Aortitis; Vegetation; Surgery

Introduction

Aortitis is a pathologic term for the presence of inflammatory changes of the aortic wall, the inflammation may be infectious or more commonly noninfectious due to large-vessel vasculitides [1]. Infectious aortitis is a rare life threatening disorder, its diagnosis is difficult to establish because of the highly variable presentation and often established when complications occur. Although most cases of aortitis are noninfectious, the possibility of an infectious cause must be considered because treatment of both types varies widely [2].

In this report, we present a case of an infectious aortitis diagnosed during an acute diabetic decompensation.

Case Report

A 32 years old woman, with no past medical history was admitted in intensive care unit department because of inaugural decompensation of diabetes. The patient presented, the first time, with the chief complaint of dry cough and fever, she was treated symptomatically (antipyretic and antitussive). Fifteen days later she presented the second time to the emergency department with purulent sputum and persistent fever, she received oral antibiotic: amoxicillin +clavulanic acid.

After five days, she developed neurobehavioral impairment with persistent fever and she was admitted in the intensive care unit. The patient Physical examination on admission revealed: a persistent fever (38.5°) with altered mental state (Glasgow coma scale: 11/15), normal deep tendon reflexes and pupillary light reflex. The patient had normal blood pressure (120/80 mmHg) with sinus tachycardia and cool extremities. She also had respiratory distress manifested by tachypnea (32 cycle per minute) and pulse oximeter saturation value of 85% breathing room air and 99% breathing supplemental oxygen. On auscultation, bronchial rales were perceptible at right pulmonary base, heart sounds were normal. No abdominal mass was present.

The laboratory results were as follows : metabolic acidosis (PH :7.2 PaO₂ : 220 mmHg, PCO₂ : 34 mmHg, SaO₂ : 99%, HCO₃⁻ : 14.1), renal failure with no ionic disorder (serum creatinine :168umole/l, Na⁺/k⁺ : 139/4,4 mmole/l), high blood glucose level (42.1 mmole/l), leucocyturia +++, acetonuria +++, high C-Reactive protein level (580 mg/l) , pathologic blood cells count (White blood cell count 28500/mm³). All bacteriological investigations (Blood and urine cultures) were negative.

The chest X-ray showed right basal pneumonia (Figure 1). The CT brain scan was normal (Figure 2). After analyzing clinical, biological and radiological data, the final diagnosis was diabetic Ketoacidosis with pneumonia as the precipitating factor.

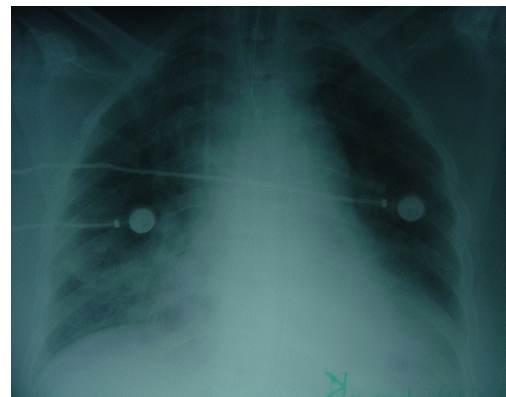

Figure 1: X-Ray chest showing right basal pneumonia

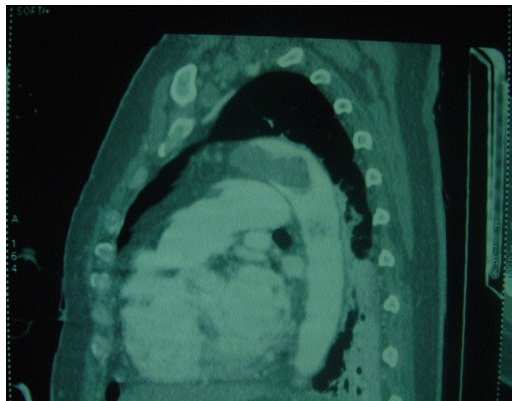


Figure 2: Thoraco abdominal CT scan showing endoluminal defect of the thoracic aorta

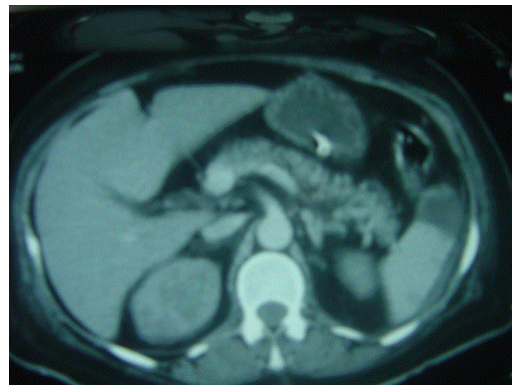


Figure 3: Thoraco abdominal CT scan showing splenic infarction with abscess.

The patient needed invasive ventilation, antimicrobial treatment was changed to clavulanic acid-amoxicillin at the dose of 1g IV three times a day and ciprofloxacin at the dose of 400 mg IV twice a day. Treatment with infusion of isotonic saline (0.9% sodium chloride) at a rate of 20 mL/kg per hour during the first hour and then 500 cc per hour was started. Regular insulin was administered by means of continuous intravenous infusion at a rate of 0.1 UI/Kg/h.

After two days of treatment, we had normal blood glucose level in contrast with unfavorable evolution of infectious syndrome (fever up to 40°, white blood cell count 23000/mm³, C-Reactive protein 269 mg/l) with hemodynamic deterioration requiring continuous intravenous infusion of noradrenalin (0.5 mg/h) and the adjunction of antifungal agents (Fluconazole at the dose of 400 mg on the first day followed by 200 mg IV once a day) to prior antibiotherapy.

Further investigations were performed: Repeated bacteriological investigations (blood and urine cultures, examinations of tracheal aspirates) were negative, and thoraco-abdominal CT scan showing an endoluminal defect of thoracic aorta, a splenic abscess and renal infarction (Figures 3-5). Trans esophageal echocardiogram showed a normal aortic and mitral valve. A splenectomy was performed isolating Methicillin-resistant *Staphylococcus aureus*. Based on these findings, the diagnosis of infectious aortitis was confirmed. The patient was then treated using vancomycin 2 g/day IV, rifampicin 600mg IV twice a day and gentamycin 240 mg IV/day.

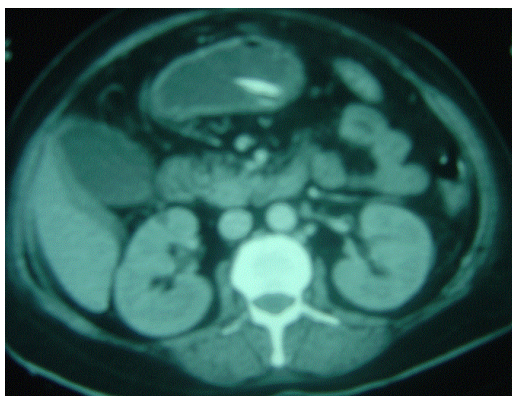


Figure 4: Thoraco abdominal CT scan showing right kidney infarction.

After four days and despite of appropriate antibiotic therapy, the patient had persistent fever and developed altered hemodynamic status.

A median sternotomy and cardiopulmonary bypass was performed with femoral cannulation.

Four aortic vegetations were found in the thoracic aorta, there was no evidence of dissection at the aorta, the aortic valve was competent, and heart was edematous and hypertrophied. On microscopic examination of the infected aortic segmental coats of the aorta were infiltrated with neutrophils aggregated into abscesses, there was partial necrosis of the medial lamellae. Bacterial cultures from the aortic vegetations revealed Methicillin-resistant *Staphylococcus aureus*.

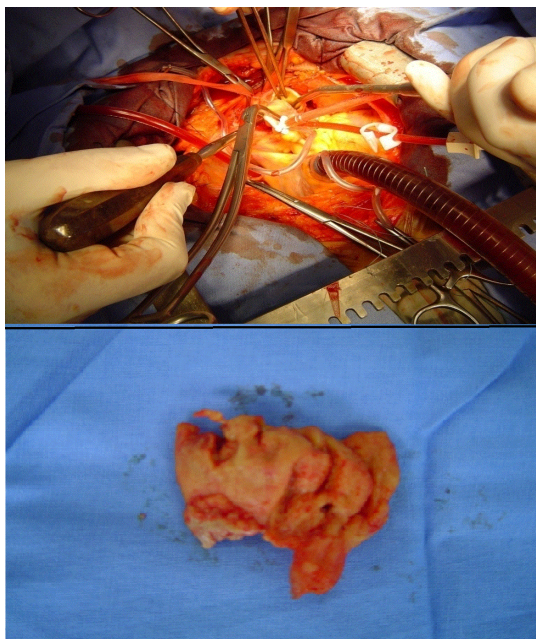


Figure 5: Aortic vegetations.

The myocardial biopsy showed a myocarditis with diffuse neutrophil infiltration of myocardium, myocyte destruction and myocardial edema. Unfortunately the patient died after surgery because of severe myocarditis.

Discussion

Infectious thoracic aortitis, is a rare entity in the antibiotic era, it has a male predominance and the mean age at diagnosis is 65 years old. If it occurs associated to an infectious endocarditis, there is no gender predominance and the mean age at diagnosis is 40 years old [3].

Risk factors for aortic infections are the same as those for atherosclerosis, aortic trauma, congenital aortic anomalies and conditions causing impaired immunity such as cancer, diabetes, alcoholism, and immunosuppressive therapies [3].

Diagnosis is frequently delayed since clinical manifestations are usually nonspecific or the first symptoms often result from expansion or rupture of an aneurysm. Infectious thoracic aortitis should always be considered in elderly patients with atherosclerosis, history of thoracic, abdominal, or back pain, and vague symptoms such as nausea, vomiting and fever [4].

In our case, the only risk factor was diabetes; the patient was young and had only respiratory symptoms misleading the diagnosis. Since infectious aortitis usually affects patients with associated infectious endocarditis, trans esophageal echocardiogram is frequently the first imaging modality to be performed in daily practice. The thoracic aorta should be promptly examined for evidence of aneurysm or vegetations. The immediate proximity of the esophagus to the great vessels allows optimal imaging. Moreover, tissue Doppler echocardiography can improve structural identification. Trans esophageal echocardiogram can distinguish intramural hematoma, aneurysm, pseudo aneurysm, and dissection of the thoracic aorta [5].

CT scan is considered an imaging technique of choice, some radiological findings such as periaortic nodularity, change in aorta size, air in the aortic wall, and aneurysm, may lead to an early diagnosis. But small vegetations and milder degrees of inflammation or wall edema may be missed [4].

Although our patient had trans esophageal echocardiogram and CT scan, no exam showed abnormalities of the aortic wall.

The initial treatment of suspected infectious aortitis is intravenous antibiotics with broad antimicrobial coverage of the most likely pathological organisms, particularly staphylococcal species and Gram-negative rods. Antibiotics should be initiated as soon as the diagnosis of infectious aortitis is suspected [2]. It seems reasonable to perform a course of antibiotics for 2 to 4 weeks prior to surgery to improve local surgical conditions [6]. We could not wait for this period of prior antibiotherapy to surgery because the patient went into septic shock. Although no clinical studies have established the optimal duration of antibiotic therapy for aortitis, a treatment course of at least 6 to 12 weeks after surgical debridement and clearance of blood cultures is generally recommended [7,8].

The standard surgical management of infectious aortitis involves resection of the infected aortic segment with in situ or extra-anatomic reconstruction. In this case, we did not perform resection of the aortic infected segment, only vegetations were removed because we believed that the aortic wall was not involved: Both trans esophageal and CT scan showed normal aortic wall and the vegetations were endoluminal.

Despite aggressive therapy, mortality associated with infectious aortitis remains high and may reach 90% in reported series with medical treatment alone [2].

A combination of surgical and medical therapy improves the prognosis and may lead to a survival rate of 75% to 100% before aneurysm formation [3]. Aneurysm formation worsens the prognosis and survival rate may reach 62%, after aneurysm rupture, surgical mortality rates may reach 65% [9].

Factors linked to a worse prognosis are advanced age, diagnosis delay, gram-negative bacilli infection, immunodepression, thoracic location, medical treatment alone, and complications occurrence (rupture, embolization, or septic shock) [9].

Conclusion

Infectious aortitis is an exceptional cause of persistent fever. It is a life threatening disease. Clinical manifestations are often nonspecific making its diagnosis difficult.

Death rates are high; a combination of surgical and medical therapy may lead to a better survival rate. Complete surgical excision of the infected aorta in combination with large coverage antibiotherapy remains the best choice of treatment.

References

1. Restrepo CS, Ocazonez D, Suri R, Vargas D (2011) Aortitis: imaging spectrum of the infectious and inflammatory conditions of the aorta. *Radiographics* 31: 435-451.
2. Gornik HL, Creager MA (2008) Aortitis. *Circulation* 117: 3039-3051.
3. Revest M, Decaux O, Cazalets C, Verohye JP, Jego P, et al. (2007) Thoracic infectious aortitis: microbiology, pathophysiology and treatment. *Rev Med Interne*. 28: 108-115.

4. Narang AT, Rathlev NK (2007) Non-aneurysmal infectious aortitis: a case report. *J Emerg Med* 32: 359-363.
5. Malouf JF, Chandrasekaran K, Orszulak TA (2003) Mycotic aneurysms of the thoracic aorta: a diagnostic challenge. *Am J Med* 115: 489-496.
6. Wein M, Bartel T, Kabatnik M, Sadony V, Dirsch O, et al. (2001) Rapid progression of bacterial aortitis to an ascending aortic mycotic aneurysm documented by transesophageal echocardiography. *J Am Soc Echocardiogr* 14: 646-649.
7. Lopes RJ, Almeida J, Dias PJ, Pinho P, Maciel MJ (2009) Infectious thoracic aortitis: a literature review. *Clin Cardiol* 32: 488-490.
8. Yih Lim PC, Hua Lee JM, Chua YL, Chia S (2013) Staphylococcal thoracic aortitis complicated by aortic dissection. *World J Emerg Med* 4: 154-156.
9. Ting AC, Cheng SW, Ho P, Poon JT, Tsu JH (2005) Surgical treatment of infected aneurysms and pseudoaneurysms of the thoracic and abdominal aorta. *Am J Surg* 189: 150-154.