

Hazards of Using Guiding Elastics for Maxillo Mandibular Fixation (MMF) after Open Reduction and Internal Fixation (ORIF) of Upper Mid Face Fracture: A Case Report

Nidarsh B Hegde^{1*}, Mithra N Hegde², Freddy Kersi Mistry³ and Saurabh M Gohil³

¹Department of Oral and Maxillofacial, Mangalore, India

²Department of Conservative Dentistry and Endodontics A.B. Shetty Memorial Institute of Dental Sciences, Mangalore, India

³Department of Oral and Maxillofacial Surgery, Mangalore, India

Abstract

In the view of current literature there is no need for Maxillo Mandibular Fixation (MMF) after Open Reduction and Internal Fixation (ORIF) of midfacial fracture. But in order to achieve primary bone healing across fractured segments many surgeons still put the patients on MMF postoperatively for a period of time depending on the extent of fracture in order to achieve primary bone healing. There are various methods in the literature for MMF. We present a case report of a patient undergoing MMF with arch bar and guiding elastics after ORIF of midfacial fracture in order to achieve primary bone healing and the disadvantages we faced post operatively in relation to the occlusion along with its management.

Keywords: Maxillo mandibular fixation (MMF); Open reduction and internal fixation (ORIF); Lefort I fracture; Zygomatic complex fracture; Guiding elastics; Stainless steel wire

Introduction

The management of fractures of the maxillofacial complex remains a challenge for the oral maxillofacial surgeon, demanding both skill and expertise [1]. The anatomy of the head is complex; skin, bone and brain have very different physical properties, in view of the fact that the facial skeleton components articulate and interdigitate in a complex fashion, it is difficult to fracture one bone without disrupting its neighbor. The incidences, demographic distribution, of the fractures vary depending on the geographical area, socioeconomic trends, road traffic accidents, alcohol and drug abuse and seasons [2]. Fractures of the facial skeleton vary in the pattern of presentation, depending on the etiology of injury. Common causes of facial bone fractures are traffic accidents (include motorcycle, automobile, bicycle, pedestrian hit), assault, fall from a height, stumbling, sports, industrial/work related accidents and others/miscellaneous (gunshot injuries, train accidents, pathological fractures) [3]. According to WHO Global Status Report on Road Safety, 2015 Road Traffic Accidents (RTA) is the leading cause of deaths in the world for persons aged 15-29 years. According to this report 1.25 million deaths occurred in the world due to RTA in 2013 [4]. According to a multi-center study in Karnataka, India the common cause for the facial fractures was found to be traffic accidents (72.7%) with a male preponderance and peak incidence during 20-30 years of age. Isolated mandibular fractures were most frequent (41.7%) followed by isolated mid face fractures (21.2%). Among mid face fractures, zygomatic bone and arch were most frequently involved [3].

Case Report

A 50 years old male came with alleged history of RTA. He was admitted in local hospital where primary management was done and was referred to our hospital for further management.

On extra-oral inspection, there was gross facial asymmetry, right periorbital edema and ecchymosis, right sub-conjunctival hemorrhage, multiple abrasions noted over right zygomatic region, supraorbital, temporal region reduced mouth opening and inability to open the right eye completely although eye movements were normal in all gazes. On

palpation step deformity was elicited bilaterally over zygomatic region, right zygomatic arch region and right infraorbital rim. Tenderness was present in right zygomatic arch and malar region (Figure 1).

On intra-oral inspection, occlusion was deranged with edge-to-edge bite and ecchymosis was present in the right buccal mucosa. On palpation, mobility of maxilla was noted in the region of premolars and molars. Tenderness was present in the buccal vestibule in the premolar region (Figures 2 and 3).

Investigations

CBCT showed fracture of lateral orbital wall, infraorbital rim, lateral

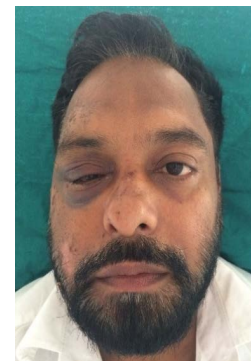

Figure 1: Extra-oral examination showing facial asymmetry with right periorbital edema and ecchymosis.

***Corresponding author:** Freddy Kersi Mistry, Post Graduate Department of Oral and Maxillofacial Surgery, Mangalore, India, E-mail: drfreddymistry@gmail.com

Received April 19, 2015; **Accepted** August 02, 2016; **Published** August 06, 2016

Citation: Hegde NB, Hegde MN, Mistry FK, Gohil SM (2016) Hazards of Using Guiding Elastics for Maxillo Mandibular Fixation (MMF) after Open Reduction and Internal Fixation (ORIF) of Upper Mid Face Fracture: A Case Report. *Cosmetol & Oro Facial Surg* 2: 108.

Copyright: © 2016 Hegde NB, et al. This is an open-access article distributed under the terms of the Creative Commons Attribution License, which permits unrestricted use, distribution, and reproduction in any medium, provided the original author and source are credited.

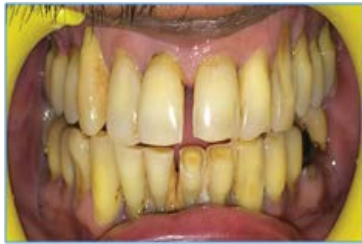

Figure 2: Intra-oral examination showing deranged occlusion with edge-to-edge bite.

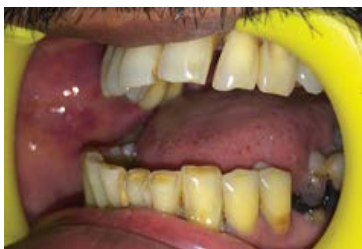

Figure 3: Intra-oral examination showing ecchymosis in right buccal mucosa extending to maxillary vestibular region.

wall of maxillary sinus, opacification of maxillary sinus on right side. Panoramic reconstruction showed fracture of floor of sinus extending interdental till the alveolar crest between 14 and 15 (Figures 4-8).

Diagnosis

After thorough clinical and radiological examination we arrived at a diagnosis of Lefort I Fracture with Right Zygomatic Complex Fracture, Dentoalveolar Fracture w.r.t. 15-16 region.

Treatment

Patient underwent open reduction and internal fixation under general anesthesia. After nasotracheal intubation preparatory surgical protocol was followed by painting the patient with Betadine (10% Povidone Iodine solution) and draping with sterile drapes, arch bars were placed in both the upper and lower arches. Via lateral eye brow approach the fronto zygomatic suture was exposed to identify the fracture line. The fracture segments were reduced and stabilized with 2 hole with gap miniplate (S. K. Surgicals, Pune, India) (Figure 9). The next step was maxillary vestibular approach for reduction and fixation of Lefort I fracture. On exposure the fracture segments were undisplaced on left side. One L-shaped plate (S. K. Surgicals, Pune, India) was placed near the left maxillary buttress region while one 2-hole plate with gap (S. K. Surgicals, Pune, India) was placed near the left piriform region (Figure 10). For right ZMC fracture, reduction was difficult to achieve due to comminution of fractured segments, after reducing with bone holding forceps, one 4-hole plate with gap (S. K. Surgicals, Pune, India) was used near piriform region and two 2-hole plate with gap (S. K. Surgicals, Pune, India) was used each for buttress region and for body of zygoma for fixation (Figure 11). Intermaxillary fixation was done and patient was placed on guiding elastics post-operatively (Figure 12). Post-operative Paranasal Sinus View was taken to evaluate the anatomical reduction and fixation (Figure 13).

Follow-up

After 15 days: On first follow-up after 15 days it was observed that the patient had anterior cross bite (Figure 14). Guiding elastics were

removed and patient was guided into proper occlusion and rigid MMF was done with 26 Gauge Stainless Steel Wire (Figure 15).

After 1 month: There was no mobility of the maxillary segment and proper occlusion was maintained.

Discussion

As a rule, early reduction of a Lefort I fractures presents minimal

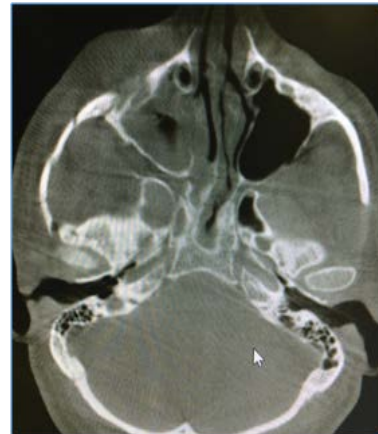

Figure 4: CBCT-Axial section showing fracture of right zygomatic arch and anterior wall of maxillary sinus with haemosinus.

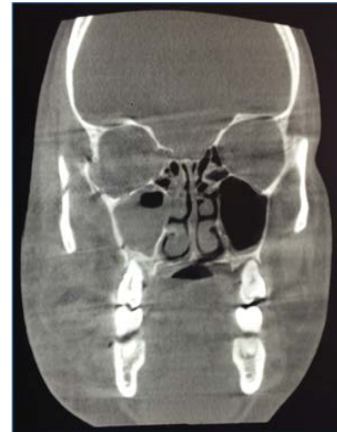

Figure 5: CBCT-Coronal section showing right fronto-zygomatic fracture with intact orbital floor.

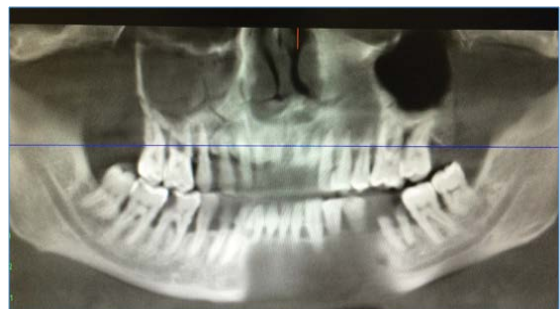

Figure 6: CBCT-Panoramic Reconstruction showing fracture line running between 1st and 2nd premolars.

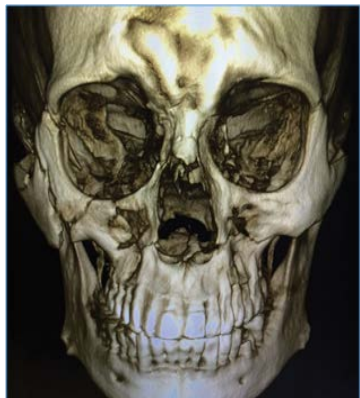

Figure 7: CBCT-3D-Reconstruction frontal view showing Le-Fort I maxillary and right zygomaticomaxillary complex fracture.

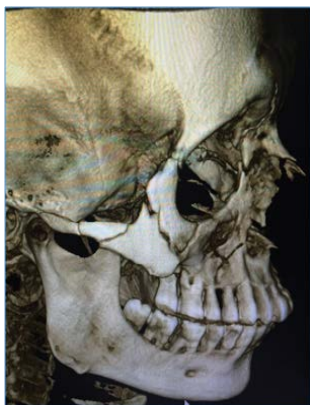

Figure 8: CBCT-3D-Reconstruction lateral view showing right zygomaticomaxillary complex fracture.

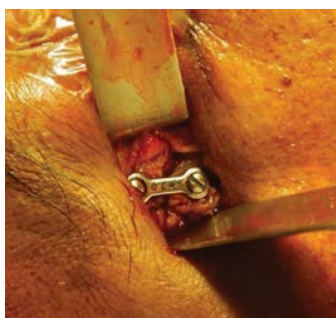

Figure 9: Right Fronto-zygomatic region fixed with one plate of 2 hole with gap.

difficulty. Beyond 7-10 days, increasing force has to be applied to complete reduction. A minimally displaced fracture is reduced and immobilized ideally by open reduction and immobilization carried out by appropriate plating devices. Alternatively and less ideally, 4 weeks of intermaxillary fixation is usually sufficient for healing to occur. In case of severe comminution, it may be necessary to extend the period to 6 weeks. An impacted fracture or one not easily reduced because of early fibrous union should be reduced by the use of either Rowe or Hayton-Williams disimpaction forceps. Two point fixation is minimal requirement for stability in case of unilateral Lefort I fracture [5].

The fact that so many techniques are available for reduction and fixation of zygomaticomaxillary complex (ZMC) fractures indicates that no one technique is always superior to others. It is not so much the actual technique, but the proper application of principles produces satisfactory results. Each ZMC fractures should be treated aggressively

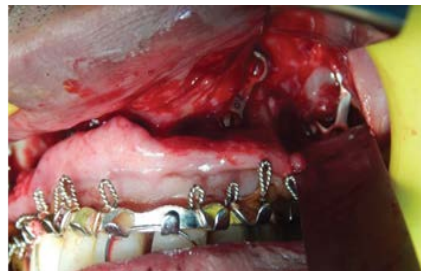

Figure 10: Left undisplaced Lefort I fracture line fixed with two plates.

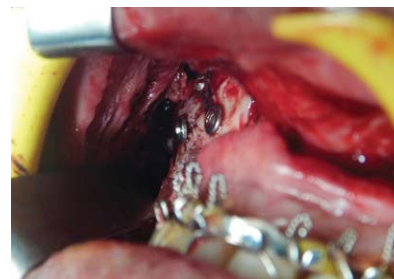


Figure 11: Right ZMC region fixation with two plates.

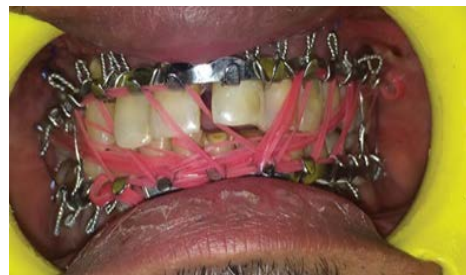

Figure 12: Post-operative occlusion with guiding elastics.

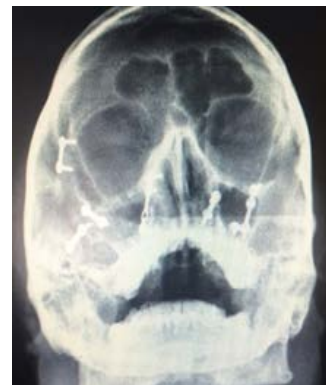


Figure 13: PNS View postoperatively showing anatomic reduction and fixation.

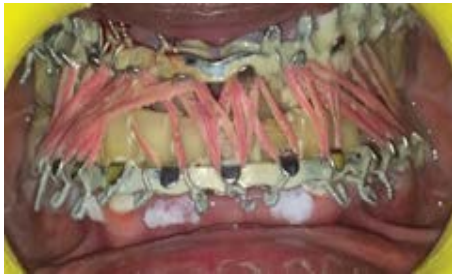

Figure 14: Postoperative day 15 showing anterior cross bite.

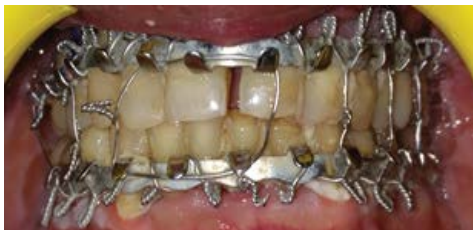

Figure 15: Guiding elastics removed and rigid MMF done with 26 gauge wire.

with open reduction and internal fixation of at least two of its four major processes [6].

In our case, since the Lefort 1 fracture line was undisplaced there was no need for reduction and only fixation was done with plates to improve the stability, as the zygomaticomaxillary complex was comminuted conventional reduction was not possible and anatomical reduction of the fragments was achieved by instrumental manipulation with fixation at 3 points (frontozygomatic, infraorbital and zygomaticomaxillary buttress region).

Immobilization and maintenance of the occlusion in order to facilitate primary healing are the main goals of using MMF for patients treated with ORIF. There are various studies in the literature for MMF using various techniques [7]. On doing through literature search there aren't any studies comparing the efficiency of the guiding elastics over the stainless steel wire for immobilization after arch bar fixation. Surgeons prefer elastics over wire because of the ease of cutting elastics by the patient or the bystander in case of emesis or airway problems. Thus we would suggest that a through longitudinal trial should be carried out comparing the efficacy of the guiding elastics over stainless steel wire for immobilization after arch bar fixation.

Conclusion

From our experience with the case we would suggest not to use Guiding Elastics as the method of MMF after ORIF of mid facial fracture. If in case MMF is required it is always advantageous to use 26 gauge stainless steel wires for MMF as a method of rigid fixation.

References

1. Thomas DW, Hill CM (2000) Etiology and changing patterns of maxillofacial trauma. In: Booth PW, Schendel SA, Hausamen JE (eds) *Maxillofacial surgery*, vol. 1. Churchill Livingstone.
2. Banks P, Brown A (2001) Etiology, surgical anatomy and classification. In: Banks P, Etiology, surgical anatomy and classification. In: Banks P, Brown A (eds), *Fractures of the facial skeleton*. Philadelphia, USA, pp: 1-4.
3. Shankar AN, Shankar VN, Hegde N, Sharma, Prasad R (2012) The pattern of the maxillofacial fractures e A multicentre retrospective study. *Journal of Cranio-Maxillo-Facial Surgery* 40: 675-679.
4. World Health Organisation (2014) *Global Health Estimates*.
5. Fonseca RJ, Walker RV, Betts NJ, BarberHD, Powers MP (2005) *Oral and maxillofacial Trauma*. (3rd edn.), Volume 2, Elseiver.
6. Fonseca RJ, Walker RV, Betts NJ, BarberHD, Powers MP (2005) *Oral and maxillofacial Trauma*. (3rd edn.), Volume 1, Elseiver.
7. Mcginn JD, Fedok FG (2008) Techniques of maxillary-mandibular fixation. *Operative Techniques in Otolaryngology-Head and Neck Surgery* 19: 117-112.

Citation: Hegde NB, Hegde MN, Mistry FK, Gohil SM (2016) Hazards of Using Guiding Elastics for Maxillo Mandibular Fixation (MMF) after Open Reduction and Internal Fixation (ORIF) of Upper Mid Face Fracture: A Case Report. *Cosmetol & Oro Facial Surg* 2: 108.

OMICS International: Publication Benefits & Features

Unique features:

- Increased global visibility of articles through worldwide distribution and indexing
- Showcasing recent research output in a timely and updated manner
- Special issues on the current trends of scientific research

Special features:

- 700+ Open Access Journals
- 50,000+ editorial team
- Rapid review process
- Quality and quick editorial, review and publication processing
- Indexing at major indexing services
- Sharing Option: Social Networking Enabled
- Authors, Reviewers and Editors rewarded with online Scientific Credits
- Better discount for your subsequent articles

Submit your manuscript at: www.editorialmanager.com/medicalsciences