

Early Outcome of Prostate Intensity Modulated Radiation Therapy (IMRT) Incorporating a Simultaneous Intra-Prostatic MRI Directed Boost

Michael H Schild, Steven E Schild*, William W Wong, Sujay A Vora, Alvin C Silva, Annelise M Silva, Thomas B Daniels and Sameer R Keole

Department of Radiation Oncology, Mayo Clinic Arizona, Scottsdale 85259, USA

Abstract

This study assessed the feasibility and outcomes of treating prostate cancer with intensity modulated radiotherapy (IMRT) incorporating a Magnetic Resonance Imaging (MRI) directed boost. Seventy-eight men received IMRT for localized prostate cancer. The entire prostate received 77.4Gy in 43 fractions and simultaneous intra-prostatic boosts (SIB) of 83Gy were administered to increase the dose to the MRI identified malignancy. In 16 (21%) patients, the MRI didn't detect a neoplasm and these patients received an SIB of 81Gy to the posterior prostate. Androgen Deprivation Therapy (ADT) was also administered to 32 (41%) patients. The 3-year rates of biochemical control, local control, distant control, and survival were 92%, 98%, 95%, and 95% respectively. While grade 1-2 toxicities were common, there were only 2 patients who suffered grade 3 toxicity. These patients developed strictures which were dilated resulting in improvement in symptoms such that both had grade 1-2 toxicity at last follow up examination. The results of this program of IMRT incorporating a MRI directed intra-prostatic boost suggest this technique is feasible and well tolerated. This technique appears to shift the therapeutic index favorably by boosting the malignancy to the highest dose without increasing the doses administered to the bladder and rectum.

Keywords: MRI directed boost; Simultaneous intra-prostatic boost; Image guided radiation therapy; Toxicity survival; Biochemical disease control

Introduction

Prostate cancer is the most common malignancy in men. In 2014, there was an estimated 233,000 new cases of prostate cancer and 29,480 deaths from prostate cancer in the U.S.[1]. Common definitive treatment options for prostate cancer include radical prostatectomy, External Beam Radiation Therapy (EBRT), and brachytherapy. For select patients with early stage, low grade cancer, active surveillance is also reasonable. In the last decade, significant technological advances have been accomplished in EBRT [2,3]. Intensity Modulated Radiation Therapy (IMRT) is now the most common form of EBRT used in the U.S. for prostate cancer, replacing 3-D conformal therapy (3-DRT). Doses of radiation delivered to the prostate gland are limited by the tolerance of bladder and rectum. Using 3-DRT, 70Gy was generally the highest dose administered to the prostate in routine practice. In recent years, advances in image guidance allow better localization of the prostate. The use of image guidance, together with IMRT, has allowed clinicians to use smaller margins decreasing the rectum and bladder within the high dose region. Doses greater than 75Gy are now routinely delivered with acceptable toxicity [4].

For EBRT treatment planning, Computed Tomography (CT) is generally used to define the prostate volume. However, CT cannot differentiate normal tissue from neoplasm within the gland. Multi-Parametric Magnetic Resonance Imaging (MP-MRI) is a superior imaging modality to visualize the prostate itself and the malignancy within the gland. It is generally accepted that two functional sequences in addition to T2-weighted imaging should be included in a multi-parametric prostate exam [5]. A combination of T2-weighted imaging (T2-WI), Diffusion Weighted Imaging (DWI), and Dynamic Contrast-Enhanced (DCE) imaging can differentiate prostate cancer from normal prostate tissue [5-7].

Several randomized trials have demonstrated that dose escalation of EBRT leads to significantly improved Biochemical Control (BC) of prostate cancer with acceptable toxicity [8,-12]. If the neoplasm can be clearly identified on MRI, further dose escalation can be administered

with a Simultaneous Intra-Prostatic Boost (SIB), while the entire prostate receives a relatively high dose. Co-registration of treatment planning CT with MP-MRI allows localization of the Intra-Prostatic Lesion (IPL) for a SIB. This strategy may improve the therapeutic ratio by increasing the dose delivered to the region containing the greatest concentration of cancer while limiting the dose to the surrounding normal tissue. The feasibility for MRI guided SIB has been demonstrated in a very limited number of studies [13,14]. This study assessed the feasibility and outcomes of treating prostate cancer with Intensity Modulated Radiotherapy (IMRT) incorporating a Magnetic Resonance Imaging (MRI) directed boost.

Materials and Methods

Previously, patients with localized prostate cancer were treated at Mayo Clinic Arizona, Department of Radiation Oncology with image guided IMRT delivering 75.6-77.4 Gy in daily 1.8 Gy fractions to the entire prostate. After 2/2009, MP-MRI scans were used to identify the IPL for treatment planning. The IPL was identified by a diagnostic radiologist specializing in genitourinary imaging. The IPL was targeted for a SIB of up to 83 Gy while the entire prostate gland received 77.4 Gy. In 16 (21%) of the 78 patients, the MRI did not detect an IPL and an SIB of 81Gy was given to the posterior and central prostate. The present analysis reviews our experience with this technique in terms of disease control and toxicity.

From 2/2009-2/2013, 78 patients with clinical stage T1-3, N0,

*Corresponding author: Steven E Schild, Mayo Clinic, 13400 E. Shea Blvd, Scottsdale, AZ 85259, USA, Tel: 480-301-8000; Fax: 480-342-3972; E-mail: sschild@mayo.edu

Received October 20, 2014; Accepted November 17, 2014; Published November 20, 2014

Citation: Schild SE, Schild MH, Wong WW, Vora SA, Silva AC, et al. (2014) Early Outcome of Prostate Intensity Modulated Radiation Therapy (IMRT) Incorporating a Simultaneous Intra-Prostatic MRI Directed Boost. OMICS J Radiol 3: 170. doi:10.4172/2167-7964.1000170

Copyright: © 2014 Schild SE, et al. This is an open-access article distributed under the terms of the Creative Commons Attribution License, which permits unrestricted use, distribution, and reproduction in any medium, provided the original author and source are credited.

M0 prostate cancers were treated with this technique. The primary objectives of the study were to assess the feasibility of administering IMRT with an MRI-directed SIB and outcome in terms of toxicity, urinary function, disease control and survival. This study was approved by the Mayo Clinic IRB. Patient characteristics are found in (Table 1). The initial evaluation included physical examination and laboratory studies (PSA levels, CBC, and serum chemistry). Diagnostic pelvic CT and bone scans were performed at the discretion of the treating physician. 1.5Tesla (T) MP-MRI was performed for 77 patients while one patient had a 3-Tesla scan before CT simulation. T2-weighted, diffusion-weighted, and Dynamic Contrast-Enhanced (DCE) images were obtained to define the IPL. The areas within the prostate suggestive of malignancy were identified. Following the MRI, four fiducial markers were placed within the prostate. CT simulation was then performed and the images co-registered. The IPL when visible on MRI were designated within the planning system (Eclipse) on the corresponding images to design the SIB.

The entire prostate gland received 77.4 Gy in 43 fractions, while the IPL received 83Gy as a SIB. In patients with MRI scans which didn't detect an IPL, a boost of 81 Gy was administered to the posterior and central prostate. Treatment was delivered with either 7-field (63 patients) or 9-field IMRT (7 patients) or Volumetric Modulated Arc Therapy (VMAT(rotational IMRT)) (8 patients) using 6 or 18-MV X-rays. The prostate volume was expanded by 3mm to create the PTV with no expansion used for the SIB volume. Uninvolved seminal vesicles received 54 Gy and involved seminal vesicles received 75-77.4 Gy. The prostate was localized prior to each treatment with KV matching of the fiducial markers. Normal tissue dose constraints were as follows: $\leq 30\%$ of the rectum or bladder could receive ≥ 70 Gy; $\leq 10\%$ of the rectum or bladder could receive ≥ 75 Gy; and ≤ 1.8 cm³ of the rectum or bladder could receive ≥ 81 Gy. The median IPL volume was 2.18 cm³. The SIB dose was 81 Gy in the 16 (21%) patients with no MRI lesion detected and 83Gy in the 62 (79%) patients with lesions detected on MRI (Figure 1).

Androgen Deprivation Therapy (ADT) was administered at the discretion of the treating physician and was recommended for intermediate and high risk disease. Patients in the intermediate-risk group were advised to receive 6 months of ADT (leuprolide) and

Total number of patients		78
Age	Median:76 (range:59-89)	
T stage	T1c	28 (36%)
	T2a	20 (26%)
	T2b	16 (21%)
	T2c	13 (17%)
	T3	1 (1%)
PSA(ng/ml)	Median:6.7 (range:2.1-43)	
Gleason score	6	26(33%)
	7	39 (50%)
	8	12 (15%)
	3	1 (1%)
Perineural invasion	No	56 (72%)
	Yes	22(28%)
NCCN risk group	Low	18(23%)
	Intermediate	43(55%)
	High	17(22%)
ADT*	No	46(59%)
	Yes	32(41%)

*ADT=Androgen Deprivation Therapy (range 6-38mo)(median=14mo)

Table 1: Patient Characteristics.

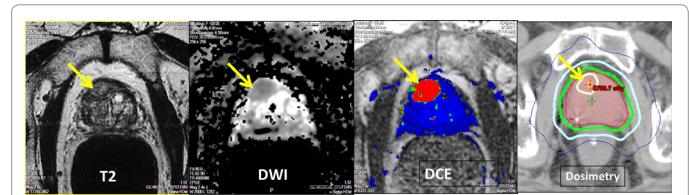


Figure 1: First 3 images are multi parametric axial MRI acquisitions (T2-weighted, diffusion-weighted (DWI), and dynamic contrast-enhanced (DCE) images). The malignancy is shown with an arrow. The fourth image is the dosimetry from this example radiotherapy plan with various isodose lines shown including a boost of 83 Gy (yellow) around the tumor, 77Gy (lime green) around the prostate, 60 Gy (light blue) and 40 Gy (dark blue).

	Grade1 n (%)	Grade2 n (%)	Grade3 n (%)
Maximum acute GU toxicity	26 (33)	41 (53)	0
Maximum chronic GU toxicity	10 (14)	19 (26)	2 (3%)
GU toxicity at last follow-up	3 (4)	18 (23)	0
Maximum acute GI toxicity	40 (51)	15 (19)	0
Maximum chronic GI toxicity	7 (9)	3 (4)	0
GI toxicity at last follow-up	1 (1)	1 (1)	0

Table 2: Genito urinary (GU) and Gastrointestinal (GI) Toxicity.

patients in the high-risk group were advised to receive 24-36 months of ADT. Not all patients consented to ADT. After radiotherapy, patients were evaluated at 3-12 month intervals with serum PSA measurement, physical examination, and toxicity assessments. Gastrointestinal (GI) and genitourinary (GU) side effects were graded using Common Terminology Criteria for Adverse Events (CTCAEv.4). Acute side effects were defined as those which occurred during and within 3 months of radiotherapy. Thereafter, toxicity was considered chronic. Treatment outcomes were defined in terms of Biochemical Control (BC) with failure defined as a rise of PSA of 2.0 above the nadir, Overall Survival (OS), local control, and distant control rates. Local failure was defined as palpable or biopsy positive relapse within the prostate. The Kaplan-Meier method was used to estimate the disease control rates.

Results

Table 1 summarizes patient characteristics. The median follow up was 36 months (range: 4-57 months). The median IPL volume was 2.18cm³. The 3-year biochemical control rate for all patients was 92%. The 3-year biochemical control rates for low risk, intermediate risk and high risk diseases were 91%, 94%, and 89%, respectively (p=0.99). The 3-year rates of local control, distant control and survival were 98%, 95%, and 95%, respectively. Three patients died at the time of this analysis from causes other than prostate cancer. Toxicity was graded as maximum acute, chronic, and at last follow-up. The toxicity at last follow-up was included to examine the trend in toxicity over time. (Table 2) summarizes the toxicity data.

Sexual function was recorded as either sufficient for intercourse or not. Of the 19 patients who had erections sufficient for intercourse before treatment, 10 (52.6%) developed erectile dysfunction. Seven (70%) of these 10 patients received ADT. Thus, of the 12 patients with erections adequate for intercourse prior to therapy who received IMRT alone, only 3 (25%) developed erectile dysfunction.

Discussion

There have been many technical advances in the radiation therapy such as 3-D treatment planning and image guidance which have

	Fonteyne [11]	Ippolito [13]	Miralbell [15]	Aluwini [2]	De MeerLeer [7]	Present Series
No.Pts	230	40	50	50	15	78
Median F/U	9mo	19mo	63mo	23mo	NS	36mo
Prostate Dose (Boost Dose)	78 (81-82)	72 (80)	64+2x either 5,6,7,or8	38 (40.3-53.8)	78 (80)	77.4 (81-83)
Acute GU Toxicity(%)	%	%	%	%	%	%
Grade 2	41	30	46	15	40	53
Grade 3	7	2.5	4	8	6.7	0
Grade 4	0	0	0	NS	NS	0
Chronic GU Toxicity(%)	%	%	%	%	%	%
Grade 2	NS	5	12	10	NS	26
Grade 3	NS	NS	0	6	NS	3
Grade 4	NS	2.5	0	NS	NS	0
Acute GI Toxicity(%)	%	%	%	%	%	%
Grade 2	11	15	8	12	20	19
Grade 3	0	5	0	2	0	0
Grade 4	0	0	0	NS	NS	0
Chronic GI Toxicity(%) Grade 2	%	%	%	%	%	%
Grade 3	NS	2.5	10	3	NS	4
Grade 4	NS	2.5	10	0	NS	0
	NS	0	0	NS	NS	0

EBRT=external beam radiation therapy, NS=Not stated, Doses(Gy), mo=months

Table 3: Doses and Toxicity from Studies incorporating an MRI directed EBRT boost.

allowed the safe escalation of dose [4,2,3]. In addition, IMRT was developed due to progress in computer technology which included the development of dynamic multileaf collimators and inverse treatment planning algorithms. Prostate cancer treatment is one of the most common applications for IMRT, achieving improved sparing of the bladder and rectum compared to conventional 3-D conformal RT [15,16]. Clinically, reductions in acute and chronic rectal and bladder toxicity have been observed using IMRT [17].

Both prospective randomized [18] and non-randomized trials [19] have demonstrated improvements in biochemical control with higher doses. A meta-analysis including 2,812 patients participating in 7 randomized controlled trials concluded that increasing the radiotherapy dose reduces the risk of biochemical failure by approximately 1.8% for each 1-Gy increase in dose delivered to the prostate. They also concluded that doses greater than 80 Gy would be expected to improve BC in all risk groups [20]. Cellini et al. reported that local failure after radiotherapy for prostate cancer generally occurs at the site of the original tumor [21]. These findings have prompted greater interest in the use of other imaging modalities to identify disease within the prostate gland for further dose intensification to potentially improve the therapeutic ratio. MRI is better than CT for identifying disease within the prostate gland. Anderson et al. reported on the use of multi parametric MRI (mp-MRI) for prostate cancer [22]. The mp-MRI identified lesions in 84% (48/57) of the patients. Similarly, an IPL was detected in 79% of patients in the present study.

Several investigators have focused on boosting the dominant lesion [2]. Pickett et al., Van Lin et al., and Riches et al. demonstrated the feasibility of delivering a SIB to an IPL defined with Magnetic Resonance Spectroscopy Imaging (MRSI), while treating the entire prostate gland to acceptable doses [13,14,23]. This study included these concepts with the hypothesis that increased radiation dose to the dominant tumor site with a concomitant high dose to the entire prostate would achieve favorable disease control without increased toxicity. It was believed that delivering an 81 Gy to 83 Gy SIB to the IPL, while treating the entire prostate gland to 77.4 Gy would create a

meaningful dose escalation without increasing the dose to the rectum or bladder beyond acceptable limits. This concept was consistent with the previously mentioned meta-analysis finding that doses greater than 80 Gy would be expected to improve BC in all risk groups [20]. The goal of the present study was to determine the feasibility and outcome of delivering a SIB to an IPL, defined by MRI, using image guided IMRT for prostate cancer.

To our knowledge, there are only 6 studies evaluating the delivery of a SIB to an IPL defined by MRI/MRSI with EBRT. These studies are compared to the present study in (Table 3). Fonteyne et al. [24] reported on 230 patients treated with IMRT. The prostate plus a 4mm margin received 78 Gy in 39 fractions. In 118 patients, the IPL plus an 8mm margin received 81-82Gy. The IPL was defined by 1.5T MRI with endorectal coil with T1-weighted imaging and T2-WI, or using MRI plus MRSI. Transabdominal-ultrasound was used for image guidance. No long term outcome data was reported. Toxicities were scored using the Radiation Therapy Oncology Group (RTOG) toxicity scale. They concluded that the acute toxicity was low and acceptable (Table 3). There were no significant differences between the groups who did or didn't receive boosts.

Ippolito et al. [25] reported a prospective study of 40 patients treated with IMRT. The prostate and seminal vesicles plus 1cm were treated to 72 Gy in 40 fractions. The IPL plus 5 mm were treated to 80Gy. A 1.5T MRI with endorectal coil was used to define the IPL. The MRI was confirmed with biopsy. All patients received adjuvant ADT and patient position was verified with daily port films. Toxicity was evaluated using RTOG scales. The 2-year actuarial incidence of \geq grade 2 GI toxicity was 9.5% and GU toxicity was 13.3%. Short follow up precluded reporting other outcome measures.

Miralbell et al. [26] conducted a prospective study of 50 patients treated with IMRT. The IPL was defined using MRI and endorectal coil using T2-WI and DCE sequences. The IPL was confirmed by biopsy. The prostate plus seminal vesicles received 64-64.4 Gy in 32 fractions. Two hypofractionated boosts of 5 Gy, 6 Gy, 7 Gy or 8 Gy were delivered stereotactically to the IPL+3 mm. The boost was

delivered in a horseshoe shaped pattern that encompassed the majority of the prostate and spared the urethra. Toxicities were graded based on RTOG scoring. Skin markers were used for treatment guidance and rectal balloons were used. Two-thirds of their patients receive ADT. Two patients developed Grade 3 acute urinary toxicity. The 5-year probabilities of Grade 2 or greater late GU and GI toxicity were 18% and 28%, respectively. The 5-year biochemical disease-free survival (b-DFS) and disease-specific survival were favorable at 98% and 100%, respectively.

De Meerleer et al. [27] reported a retrospective study of 15 patients. IPL was defined by 1.5T MRI with T2-WI sequences and confirmed by biopsy. The prostate plus 7-10mm were treated to 74Gy and there was no margin around the 80Gy boost. The RTOG toxicity scale was used to grade toxicity. Image guidance was accomplished with transabdominal ultrasound. Of the 15 patients, one (7%) patient developed grade 3 GU toxicity. Grade 2 GI and GU toxicity was observed in four (27%) and six (40%) patients, respectively.

Scarborough et al. [28] demonstrated that image guidance with internal fiducial markers and daily kV imaging was more accurate than transabdominal ultrasound for localizing the prostate. The present study is one of only three studies to use gold seeds for image guidance while delivering an SIB with EBRT to an MRI defined IPL. One of these studies was performed by Singh et al. [29], and included 3 patients. The investigators reported early results of a SIB to 94.5 Gy to an MRI defined IPL while treating the entire prostate to 75.6 Gy/42 fractions. Two patients developed grade 2 acute GU toxicities and one patient developed acute grade 1 GI toxicity. However, their cohort was too small for a clear estimate of toxicity or control rates. The other study using this approach was conducted by Aluwini et al. [30]. These investigators prospectively treated 50 patients with low- or intermediate-risk prostate cancer with Stereotactic Body Radiation Therapy (SBRT). The entire prostate plus 3 mm received four daily fractions of 9.5Gy for a total of 38Gy with a SIB of 11Gy per fraction delivered to the IPL. T1 and T2-weighted sequences on a 1.5T MRI without an endorectal coil were used to define the IPL. Gold fiducial seeds were implanted 1 week prior to CT and MRI and used for image guidance. They reported relatively low toxicity but follow up was too short to determine disease control rates. Toxicity for studies that delivered an SIB with EBRT to an IPL defined by MRI is shown in (Table 3).

Our results demonstrate similar toxicity as other prostate IMRT studies. Zelefsky et al. [3] reported 9% grade 2 and 3% grade 3 GU toxicity and 1.6% grade 2 and 0.1% grade 3 GI toxicity. The prostate was treated to 81Gy, while in the present study only the IPL or posterior/central regions received 81-83Gy.

The present series reported acute and chronic grade 2 GU toxicities that are slightly higher than other studies employing SIB to MRI defined IPLs (Table 3). Patients in the present study with any GU discomfort were given ibuprofen or alpha-1blockers. In the present study the use of any medication to treat GU symptoms was considered as grade 2 GU toxicity. This probably accounts for the higher grade 2 GU toxicity. The GI toxicity levels are similar to the other studies. The use of various toxicity scales by investigators accounts for many of the differences in toxicity reported in these studies.

This trial found that it was possible to increase the dose administered to the prostate cancer without exceeding the tolerance of the normal tissues. Additionally, the severity of side effects decreased over time. Although 2 patients developed urethral strictures and were graded as having chronic grade 3 GU toxicity, both had urethral dilation with improvement of their symptoms. One patient had a decrease in toxicity

to grade 0 after urethral dilation and the other had a decrease in toxicity to grade 2. No patients had grade 3 or higher GU toxicity at their final follow-up.

Studies implementing various imaging and treatment modalities to boost IPL have been reported [31]. Wong et al. [2] reported a prospective trial including 71 patients treated with IMRT. The IPL was defined on Indium-111-Capromab Pendetide(ProstaScint) imaging. The prostate and seminal vesicles(when involved) received 75.6Gy in 42 fractions of IMRT and the IPL received 82Gy as a SIB. Transabdominal ultrasound was used for image guidance. Seventeen (24%) of patients received ADT. The 5-year BC rates were 94% for the entire cohort and 97%, 93%, and 90% for low-, intermediate-, and high-risk groups, respectively. A modified RTOG scale was used to grade toxicity. Severe acute grade 3 and 4 GU toxicity occurred in 1% and 0% of patients, respectively. Severe late grade 3 and 4 GU toxicity occurred in 4% and 1% of patients. There were no grade 3 or 4 GI toxicities. Ellis et al. [32] used ProstaScint imaging to guide brachytherapy dose escalation to the region containing the IPL. Pinkawa et al. [33] used 18F-Fluorocholine Positron Emission Tomography to define an IPL and delivered an SIB with IMRT. Schick et al. [34] used MRI to guide dose escalation via brachytherapy. Dibiasi et al. [35] and Zelefsky et al. [36] used MRSI to guide dose escalation via brachytherapy.

This study reports 3-year rates of biochemical control, local control, distant control, and survival. Limitations include the use of retrospective methodology and relatively short median follow-up time (36 months). Additionally, MR protocols evolved during this time frame due to hardware and software upgrades, specifically with improvements in DWI and DCE. Additionally, 21% of our patients had no IPL detected on MRI and received a boost to the posterior and central prostate. Our study includes acute and chronic toxicities as well as clinical outcomes for comparative purposes. In the future, 3T MRI will be used to improve targeting when designing the SIB.

This study demonstrated the feasibility of using MRI to define an intra-prostatic lesion for SIB to 81- 83Gy while treating the entire prostate gland to 77.4Gy. The present study is one of only three studies to use gold seed fiducial markers for image guidance while delivering a MRI directed boost. The treatment employed resulted in low GI and GU toxicities. The three year biochemical control was favorable at 92%. MRI directed SIB deserves further study to potentially improve the treatment of prostate cancer. It allowed the increase of dose delivered to the region of highest cancer cell concentration while sparing the normal surrounding dose limiting organs from receiving excessive radiation. The initial results appeared promising but longer follow up and more investigation is needed to improve treatment further.

Acknowledgment

This study was conducted with support from federally funded work study earnings through Midwestern University. This study was conducted with support for SES's research time from the North Central Cancer Treatment Group and Mayo Clinic. The content is solely the responsibility of the authors and does not necessarily represent the views of the National Cancer Institute or the National Institute of Health. With funding from Public Health Service (CA-25224, CA-37404, CA-35267, CA-35431, CA-35195, CA-63848, CA-63849, CA-35113, CA-35103, CA-35415, CA-35101, CA-35119, CA-35090).

References

1. Siegel R, Naishadham D, Jemal A (2013) Cancer statistics 2013. *CA Cancer J Clin* 63: 11-30.
2. Wong WW, Schild SE, Vora SA, Ezzell GA, Nguyen BD, et al. (2011) Image-guided radiotherapy for prostate cancer: a prospective trial of concomitant boost using indium-111-capromab pendetide (ProstaScint) imaging. *Int J Radiat Oncol Biol Phys* 81: e423-429.

3. Zelefsky MJ, Fuks Z, Hunt M, Yamada Y, Marion C, et al. (2002) High-dose intensity modulated radiation therapy for prostate cancer: early toxicity and biochemical outcome in 772 patients. *Int J Radiat Oncol Biol Phys* 53: 1111-1116.
4. Vora SA, Wong WW, Schild SE, Ezzell GA, Andrews PE, et al. (2013) Outcome and toxicity for patients treated with intensity modulated radiation therapy for localized prostate cancer. *J Urol* 190: 521-526.
5. Gupta RT, Kauffman CR, Polascik TJ, Taneja SS, Rosenkrantz AB (2013) The state of prostate MRI in 2013. *Oncology (Williston Park)* 27: 262-270.
6. Verma S, Rajesh A (2011) A clinically relevant approach to imaging prostate cancer: review. *AJR Am J Roentgenol* 196: S1-10 Quiz S11-4.
7. Wu LM, Xu JR, Ye YQ, Lu Q, Hu JN (2012) The clinical value of diffusion-weighted imaging in combination with T2-weighted imaging in diagnosing prostate carcinoma: a systematic review and meta-analysis. *AJR Am J Roentgenol* 199: 103-110.
8. Alicikus ZA, Yamada Y, Zhang Z, Pei X, Hunt M, et al. (2011) Ten-year outcomes of high-dose, intensity-modulated radiotherapy for localized prostate cancer. *Cancer* 117: 1429-1437.
9. Peeters ST, Heembergen WD, Koper PC, van Putten WL, Slot A, et al. (2006) Dose-response in radiotherapy for localized prostate cancer: results of the Dutch multicenter randomized phase III trial comparing 68 Gy of radiotherapy with 78 Gy. *J Clin Oncol* 24: 1990-1996.
10. Pollack A, Zagars GK, Starkschall G, Antolak JA, Lee JJ, et al. (2002) Prostate cancer radiation dose response: results of the M. D. Anderson phase III randomized trial. *Int J Radiat Oncol Biol Phys* 53: 1097-1105.
11. Spratt DE, Pei X, Yamada J, Kollmeier MA, Cox B, et al. (2013) Long-term survival and toxicity in patients treated with high-dose intensity modulated radiation therapy for localized prostate cancer. *Int J Radiat Oncol Biol Phys* 85: 686-692.
12. Zietman AL, DeSilvio ML, Slater JD, Rossi CJ Jr, Miller DW, et al. (2005) Comparison of conventional-dose vs high-dose conformal radiation therapy in clinically localized adenocarcinoma of the prostate: a randomized controlled trial. *JAMA* 294: 1233-1239.
13. Pickett B, Vigneault E, Kurhanewicz J, Verhey L, Roach M (1999) Static field intensity modulation to treat a dominant intra-prostatic lesion to 90 Gy compared to seven field 3-dimensional radiotherapy. *Int J Radiat Oncol Biol Phys* 44: 921-929.
14. van Lin EN, Fütterer JJ, Heijmink SW, van der Vight LP, Hoffmann AL, et al. (2006) IMRT boost dose planning on dominant intraprostatic lesions: gold marker-based three-dimensional fusion of CT with dynamic contrast-enhanced and 1H-spectroscopic MRI. *Int J Radiat Oncol Biol Phys* 65: 291-303.
15. Cella L, Lomax A, Miralbell R (2001) Potential role of intensity modulated proton beams in prostate cancer radiotherapy. *Int J Radiat Oncol Biol Phys* 49: 217-223.
16. Luxton G, Hancock SL, Boyer AL (2004) Dosimetry and radiobiologic model comparison of IMRT and 3D conformal radiotherapy in treatment of carcinoma of the prostate. *Int J Radiat Oncol Biol Phys* 59: 267-284.
17. Sveistrup J, af Rosenschold PM, Deasy JO, Pommer T, Petersen PM, et al. (2014) Improvement in toxicity in high risk prostate cancer patients treated with image-guided intensity-modulated radiotherapy compared to 3D conformal radiotherapy without daily image guidance. *Radiat Oncol* 9: 44.
18. Dearnaley DP, Sydes MR, Graham JD, Aird EG, Bottomley D, et al. (2007) Escalated-dose versus standard-dose conformal radiotherapy in prostate cancer: first results from the MRC RT01 randomised controlled trial. *Lancet Oncol* 8: 475-487.
19. Vora SA, Wong WW, Schild SE, Ezzell GA, Halyard MY (2007) Analysis of biochemical control and prognostic factors in patients treated with either low-dose three-dimensional conformal radiation therapy or high-dose intensity-modulated radiotherapy for localized prostate cancer. *Int J Radiat Oncol Biol Phys* 68: 1053-1058.
20. Viani GA, Stefano EJ, Afonso SL (2009) Higher-than-conventional radiation doses in localized prostate cancer treatment: a meta-analysis of randomized, controlled trials. *Int J Radiat Oncol Biol Phys* 74: 1405-1418.
21. Cellini N, Morganti AG, Mattiucci GC, Valentini V, Leone M, et al. (2002) Analysis of intraprostatic failures in patients treated with hormonal therapy and radiotherapy: implications for conformal therapy planning. *Int J Radiat Oncol Biol Phys* 53: 595-599.
22. Anderson ES, Margolis DJ, Mesko S, Wang PC, Kamrava M, et al. (2014) Multiparametric MRI identifies and stratifies prostate cancer lesions: implications for targeting intraprostatic targets. *Brachytherapy* 13: 292-298.
23. Riches SF, Payne GS, Desouza NM, Morgan VA, Morgan SC, et al. (2014) Effect on therapeutic ratio of planning a boosted radiotherapy dose to the dominant intraprostatic tumour lesion within the prostate based on multifunctional MR parameters. *Br J Radiol* 87: 20130813.
24. Fonteyne V, Villeirs G, Speleers B, Lumen N, D Neve W, et al. (2008) Intensity-modulated radiotherapy as primary therapy for prostate cancer: report on acute toxicity after dose escalation with simultaneous integrated boost to intraprostatic lesion. *Int J Radiat Oncol Biol Phys* 72: 799-807.
25. Ippolito E, Mantini G, Morganti AG, Padula GD, Macchia G, et al. (2012) Intensity-modulated radiotherapy with simultaneous integrated boost to dominant intraprostatic lesion: preliminary report on toxicity. *Am J Clin Oncol* 35: 158-162.
26. Miralbell R, Mollà M, Rouzaud M, Hidalgo A, Toscas JI, et al. (2010) Hypofractionated boost to the dominant tumor region with intensity modulated stereotactic radiotherapy for prostate cancer: a sequential dose escalation pilot study. *Int J Radiat Oncol Biol Phys* 78: 50-57.
27. De Meerleer G, Villeirs G, Bral S, Paelinck L, De Gerssem W, et al. (2005) The magnetic resonance detected intraprostatic lesion in prostate cancer: planning and delivery of intensity-modulated radiotherapy. *Radiother Oncol* 75: 325-333.
28. Scarbrough TJ, Golden NM, Ting JY, Fuller CD, Wong A, et al. (2006) Comparison of ultrasound and implanted seed marker prostate localization methods: Implications for image-guided radiotherapy. *Int J Radiat Oncol Biol Phys* 65: 378-387.
29. Singh AK, Guion P, Sears-Crouse N, Smith S, Holly N, et al. (2007) Simultaneous integrated boost of biopsy proven, MRI defined dominant intraprostatic lesions to 95 Gray with IMRT: early results of a phase I NCI study. *Radiat Oncol* 2: 36.
30. Aluwini S, van Rooij P, Hoogeman M, Kirkels W, Kolkman-Deurloo IK, et al. (2013) Stereotactic body radiotherapy with a focal boost to the MRI-visible tumor as monotherapy for low- and intermediate-risk prostate cancer: early results. *Radiat Oncol* 8: 84.
31. Bauman G, Haider M, Van der Heide UA, Ménard C (2013) Boosting imaging defined dominant prostatic tumors: a systematic review. *Radiother Oncol* 107: 274-281.
32. Ellis RJ, Zhou H, Kaminsky DA, Fu P, Sodee DB, et al. (2007) Rectal morbidity after permanent prostate brachytherapy with dose escalation to biologic target volumes identified by SPECT/CT fusion. *Brachytherapy* 6: 149-156.
33. Pinkawa M, Piroth MD, Holy R, Winz OH, Krohn T, et al. (2012) Dose-escalation using intensity-modulated radiotherapy for prostate cancer - evaluation of quality of life with and without (18)F-choline PET-CT detected simultaneous integrated boost. *Radiat Oncol* 7: 14.
34. Schick U, Popowski Y, Nouet P, Bieri S, Rouzaud M, et al. (2011) High-dose-rate brachytherapy boost to the dominant intra-prostatic tumor region: hemirradiation of prostate cancer. *Prostate* 71: 1309-1316.
35. DiBiase SJ, Hosseinzadeh K, Gullapalli RP, Jacobs SC, Naslund MJ, et al. (2002) Magnetic resonance spectroscopic imaging-guided brachytherapy for localized prostate cancer. *Int J Radiat Oncol Biol Phys* 52: 429-438.
36. Zelefsky MJ, Cohen G, Zakian KL, Dyke J, Zaider M, et al. (2000) Intraoperative conformal optimization for transperineal prostate implantation using magnetic resonance spectroscopic imaging. *Cancer J* 6: 249-255.