

Otolaryngology: Open Access

September, 2015, <http://dx.doi.org/10.4172/2161-119X.1000i002>

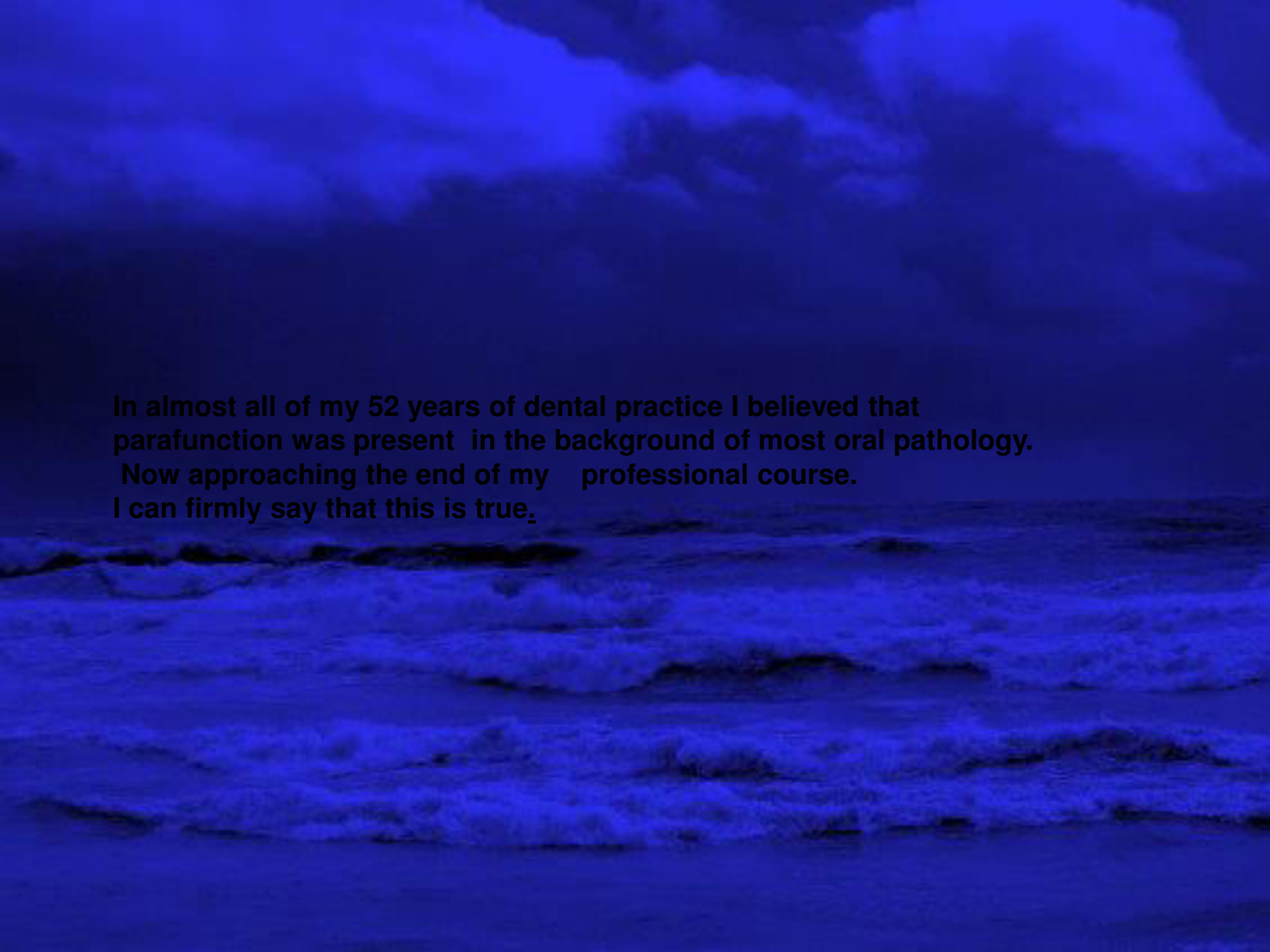
Volume 5. Issue 5. 1000i002

***Pere Harster**

Title: Bonadex Dentistas

National Council of Dentistry, Spain

E-mail: pereharster@gmail.com



In almost all of my 52 years of dental practice I believed that parafunction was present in the background of most oral pathology. Now approaching the end of my professional course. I can firmly say that this is true.

¿What is parafunction?

It's not easy to define, in most of the medical dictionaries the term does not exist.

It is a muscular disorder, from neural origin, it is repetitive, unconscious and without utilitarian sense.

In the mouth. Mainly there are two types of parafunctions:

The ones related to chewing.


The ones related to deglutition.

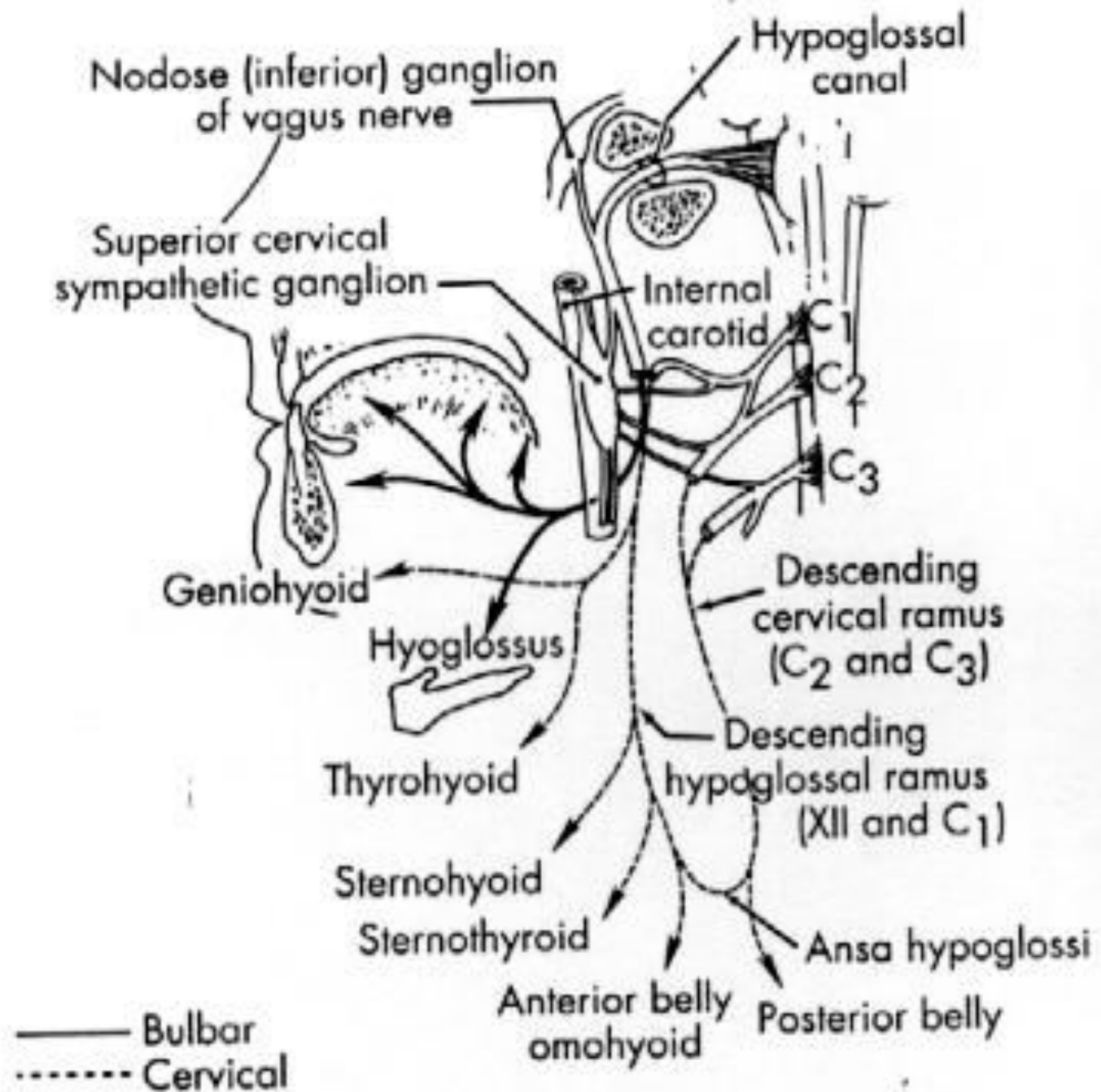
The first related to the stress and anxiety.

The second probably related to the “memes”
(parcels of neuromuscular information transmitted like “genes” or by cultural imitation).

(Memes, a term used in neurosciences)

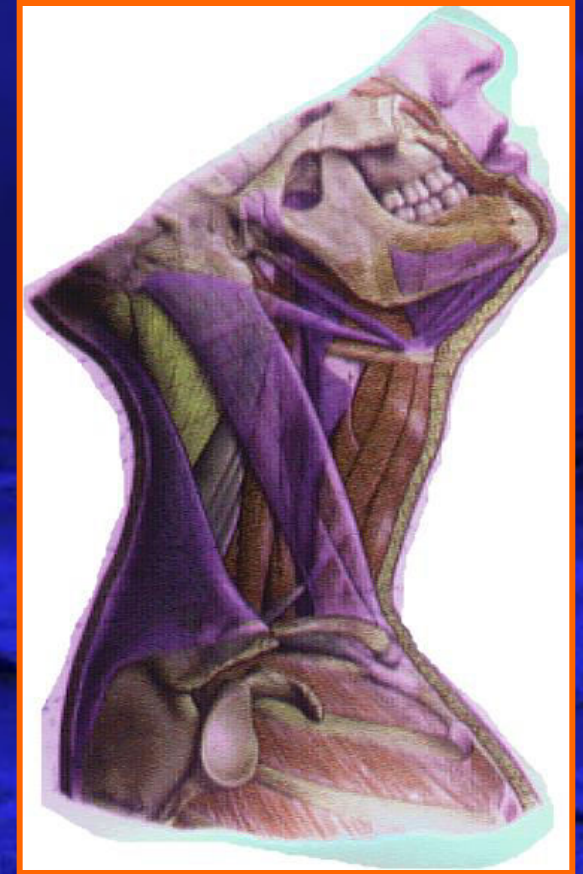The two are expressed by mussels and conducted by the nervous system

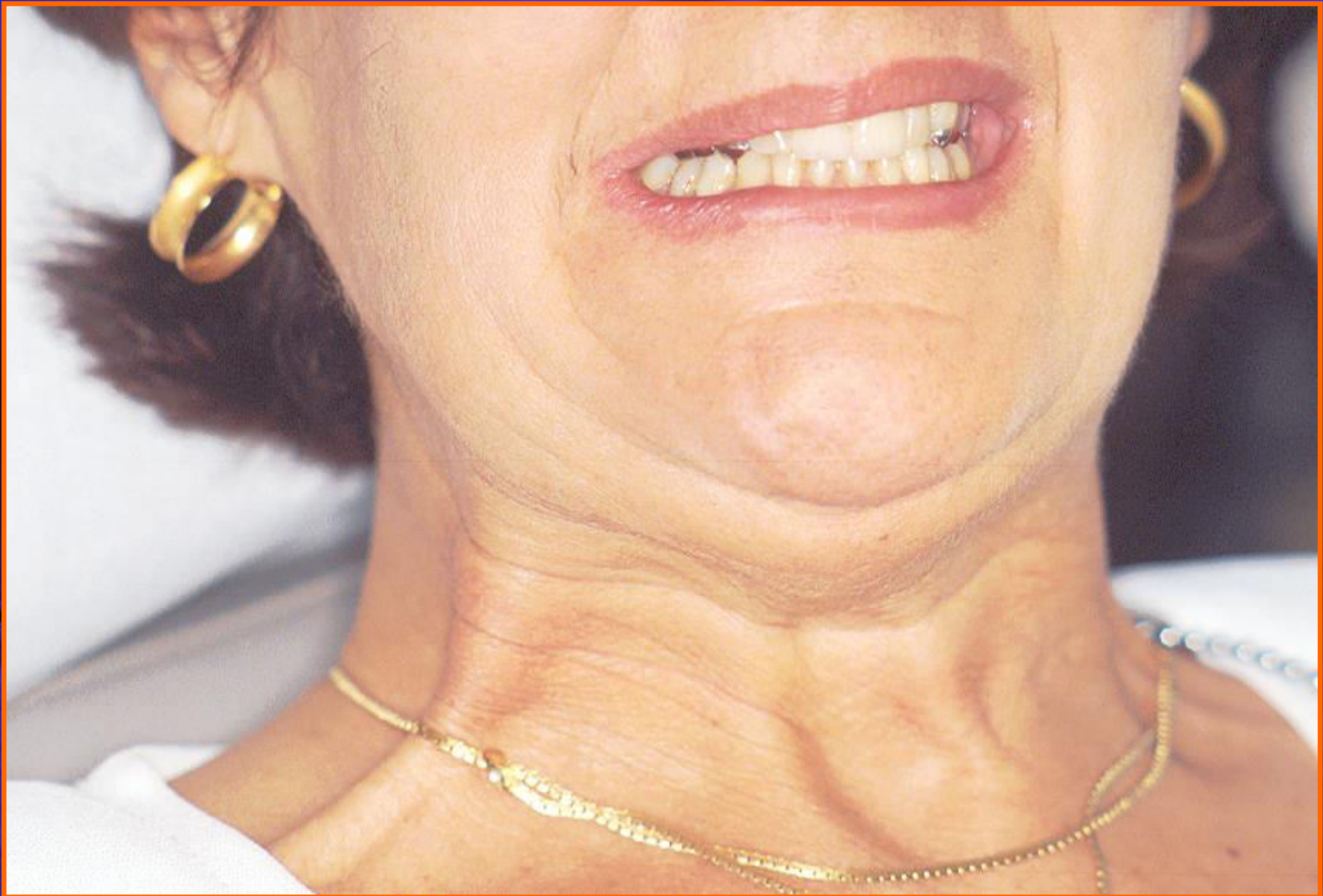



Dentist frequently do not pay sufficient attention to opener muscles

- Digastric m.
- Estilohioideus & Genihioideus m.
- Milohioideus m.
- Hioglossus m.
- A very special three: Estiloglossus, Estilofaringeus and Estilohioideus m.
- Omohioideus m.
- Sterno tiroideus m.
- Tirohioideus m
- Sterno hioideus m.





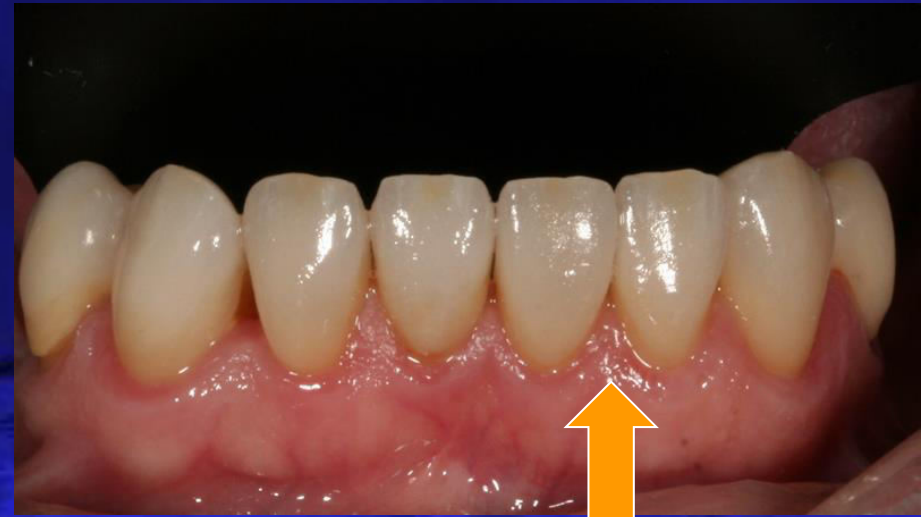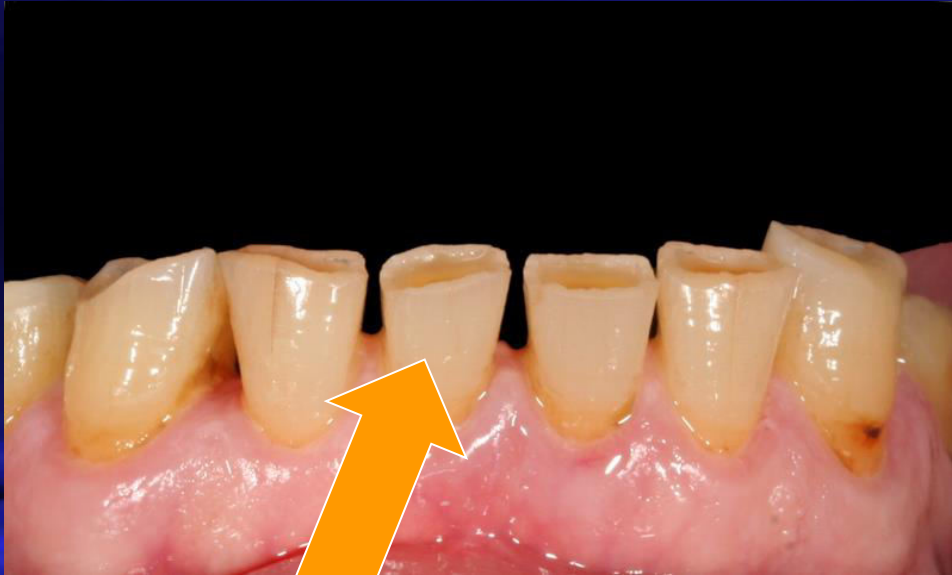Lack of coordination : simultaneous contraction of agonistic and antagonistic muscles.

The parafunctional profile

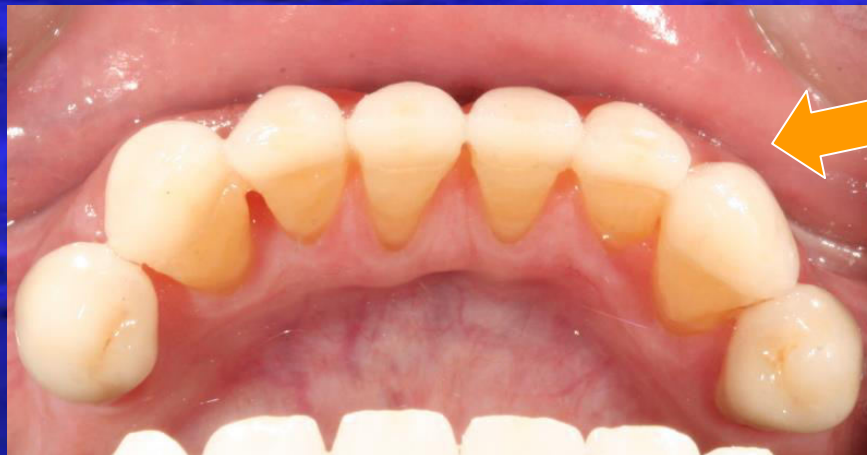- **Injury of the hard tissues of teeth and/or alveolar bone.**
- **Thickness of the mandible angle.**
- **Elongated styloid processes.**
- **Enlarged maxillary sinuses.**

Abrasion

wear and tear by mechanical rubbing
is it parafunction? Definitely yes



Undisturbed

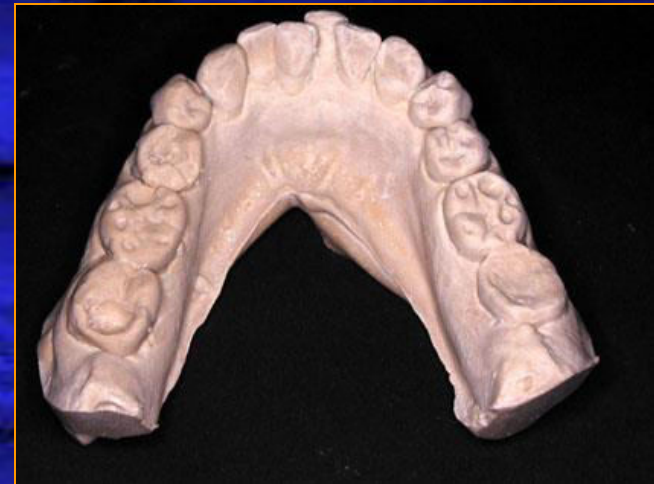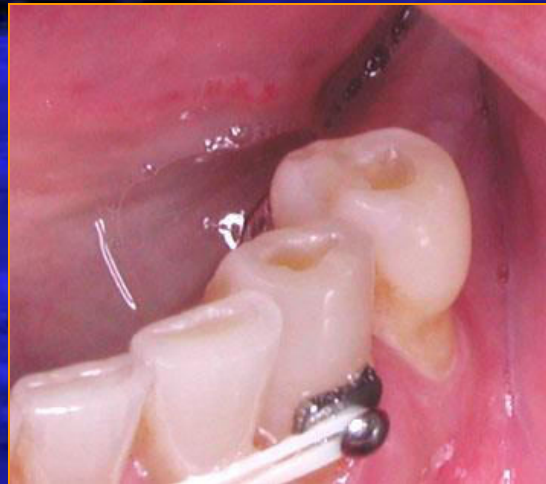

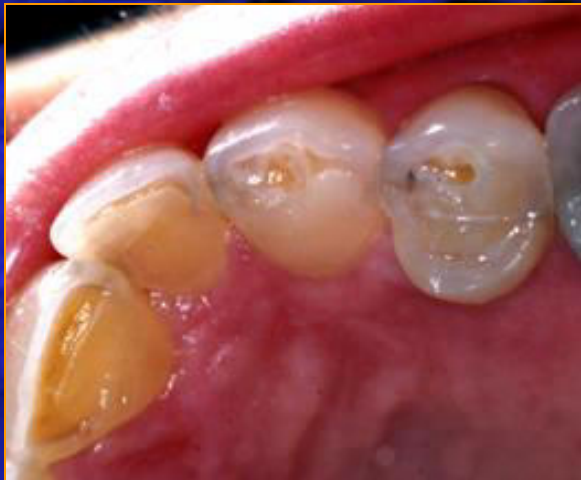
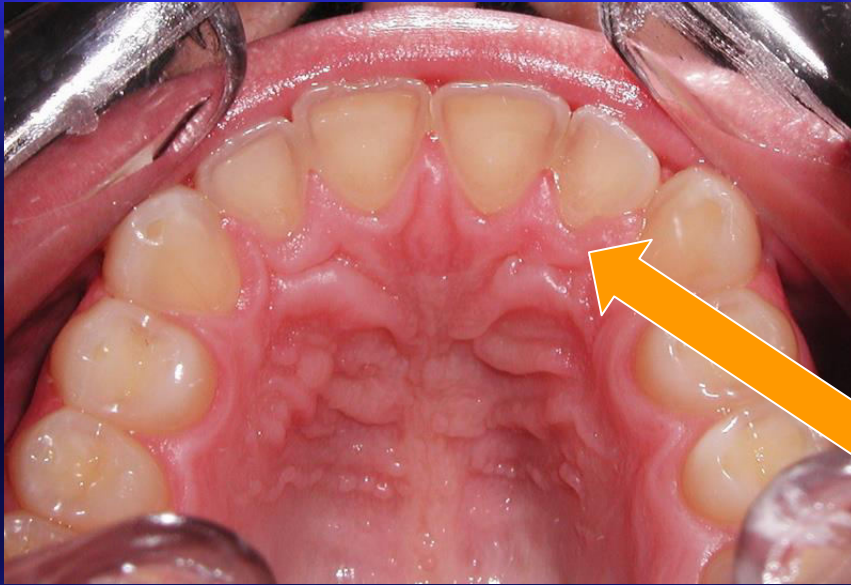
Treated by porcelain
Veneers

Erosion

Low salivary Ph. There are dissolution injuries.
Causes: intake of citrics, carbonic beverages.
Esofagal regurgitations

Are these parafunctions? Probably not, but in some cases mixed origins could exist

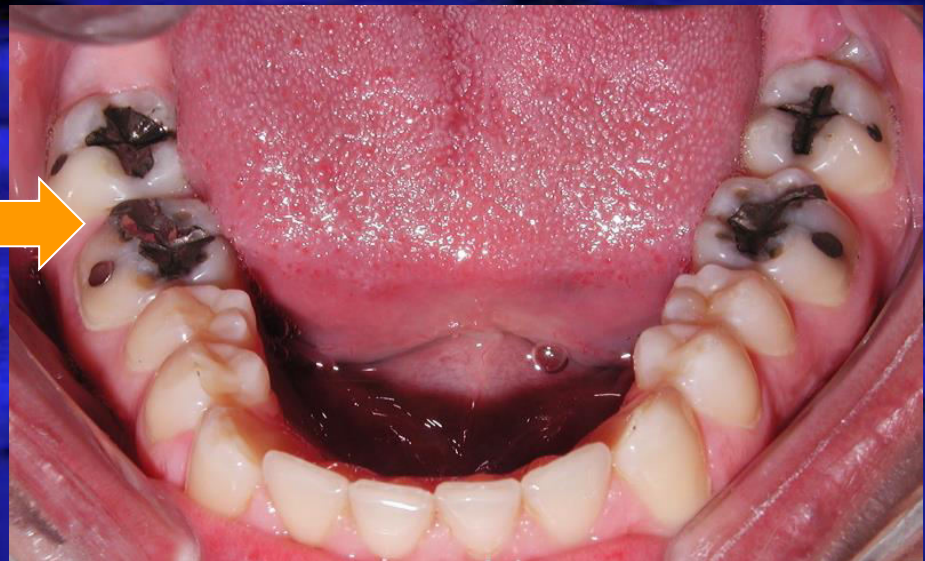



Erosions suggesting esophagal regurgitations.
Possibly caused by bulimia
(continuous and self -provoked vomiting).

Lingual aspect of anterior teeth

Rounded cusp
And incisal edges

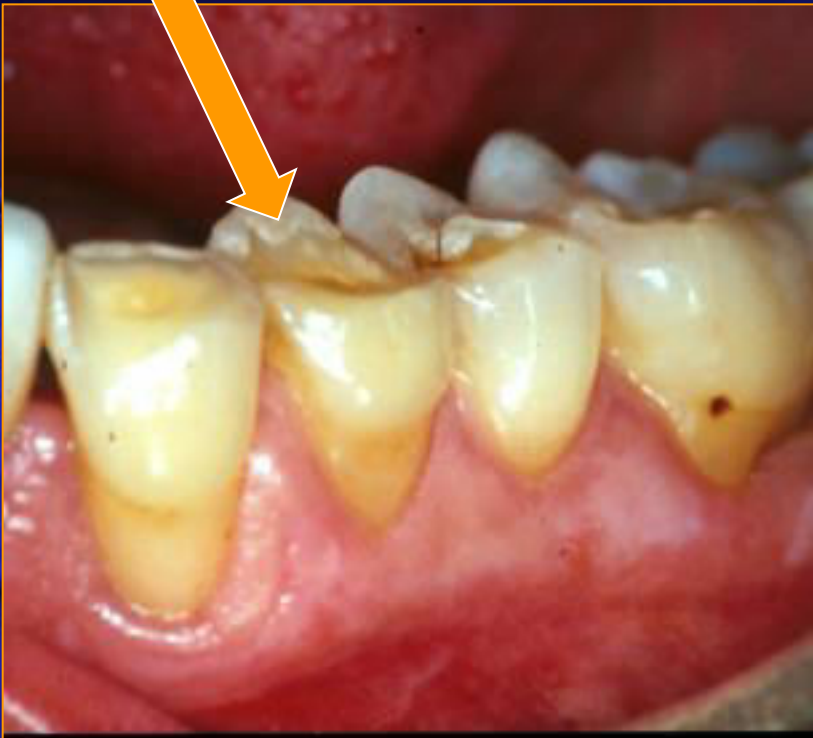


Abfractions:

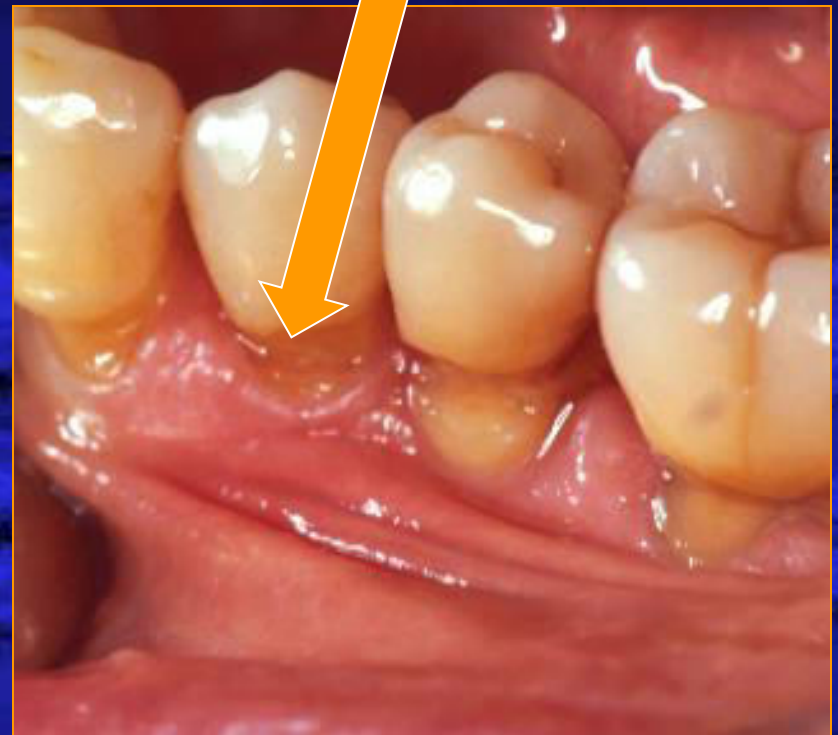
Lost of dental structure in the collar of the tooth

Are these pictures images of parafunction? Probably yes but of different origin

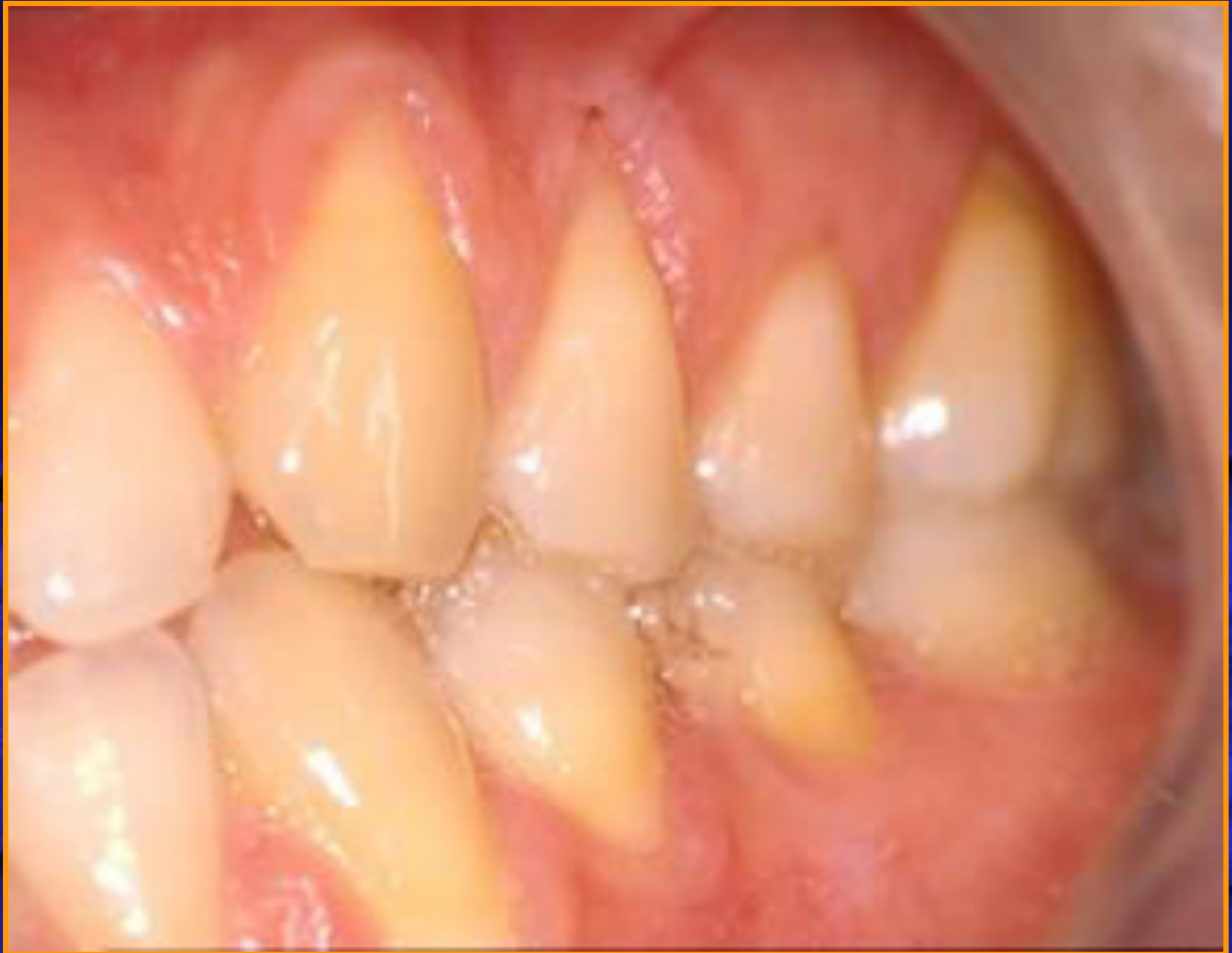Coincide with bruxism



Coincide with tongue thrust



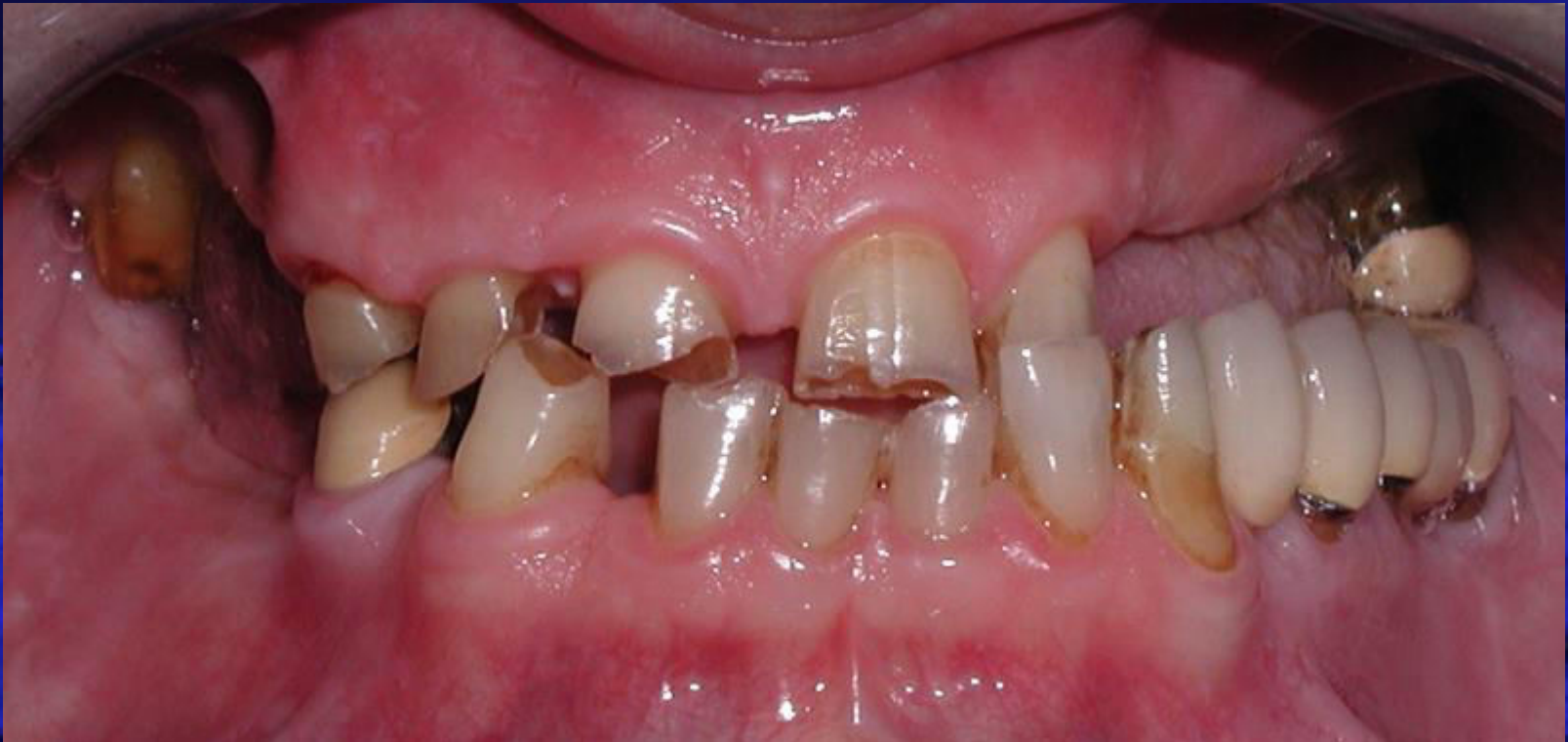Do not mix up abfractions whith dehiscencies, in these there is not a lost of dental structures



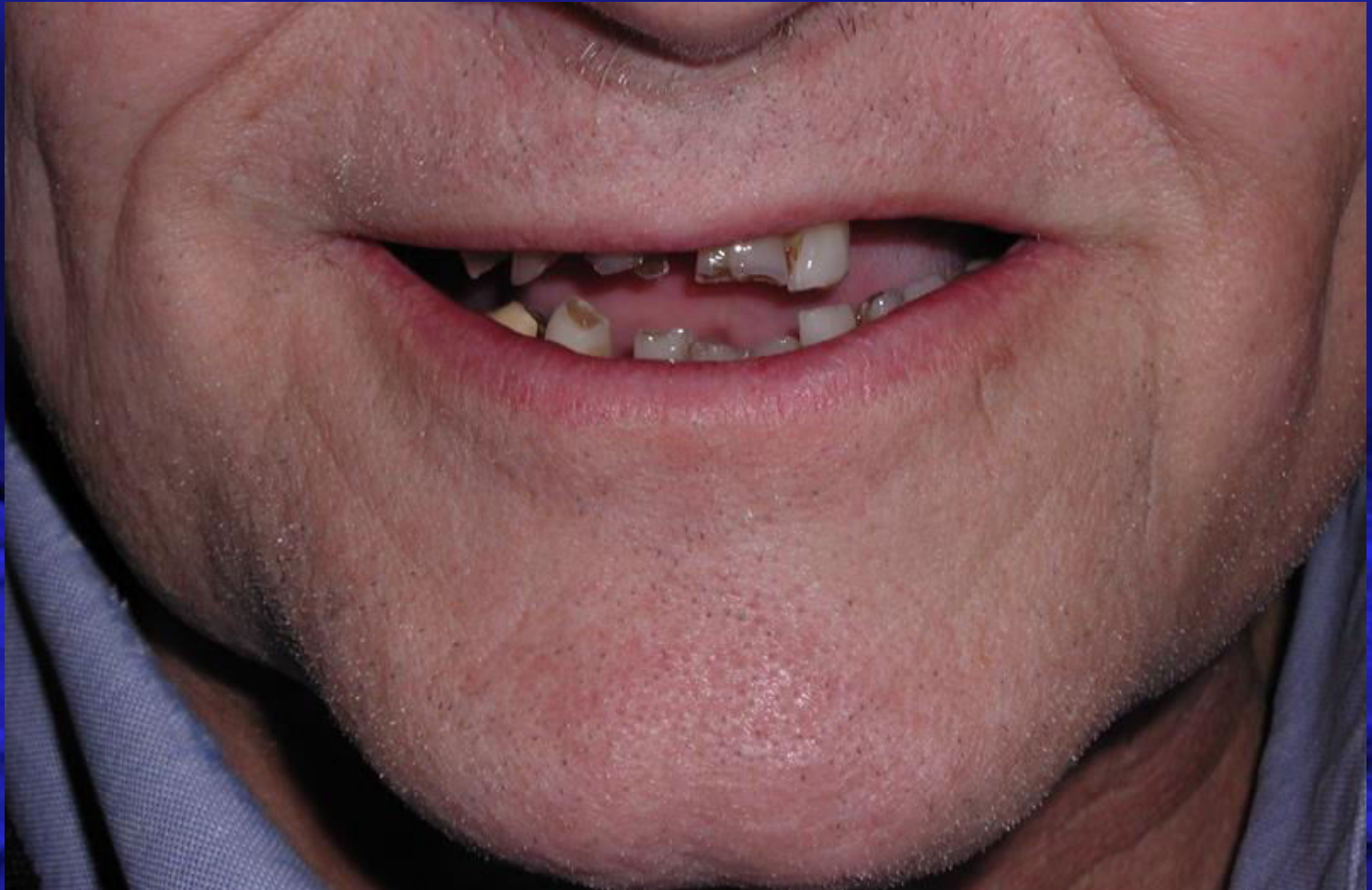**Is it due to parafunction?
Probably yes but of the tongue**

Tony is a happy man

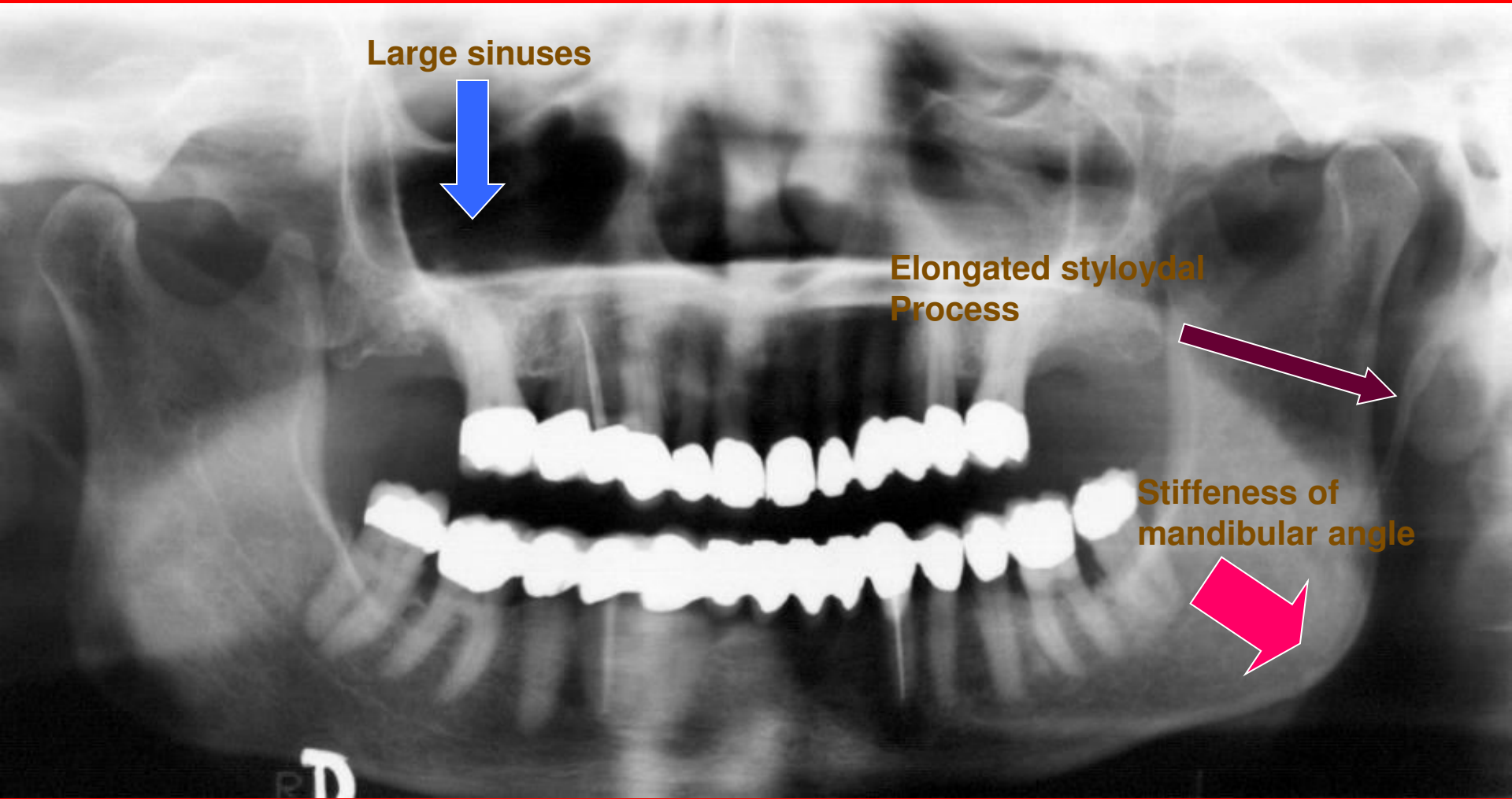
People are often symptoms free



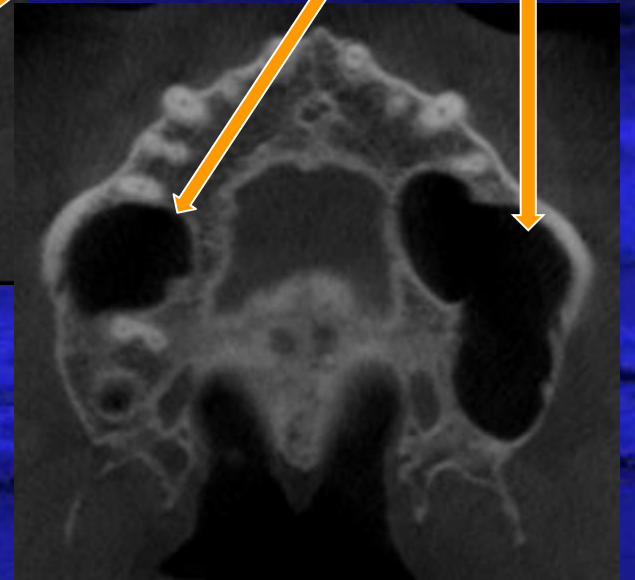
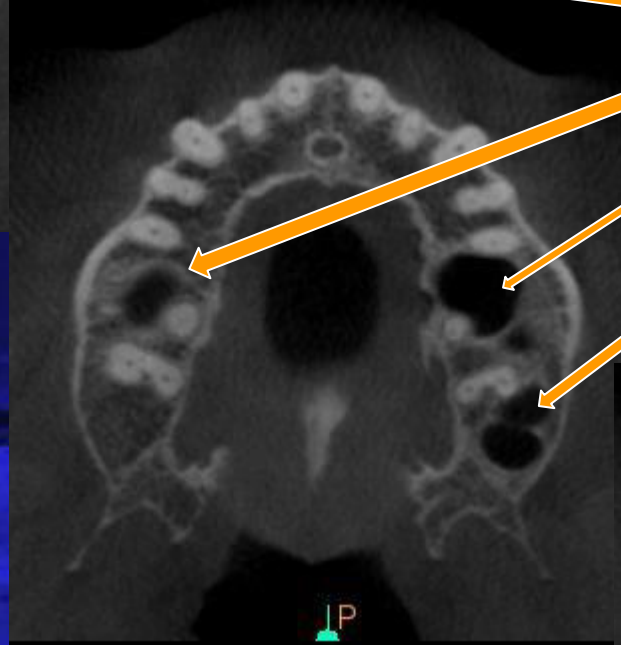
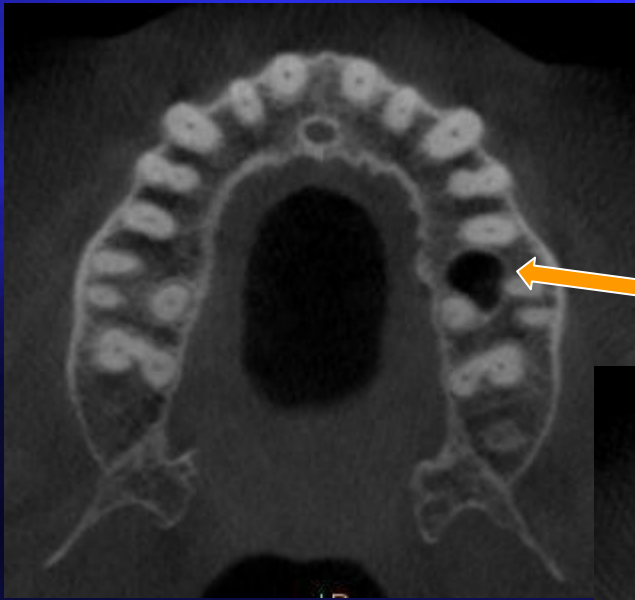
He complains only of poor esthetics



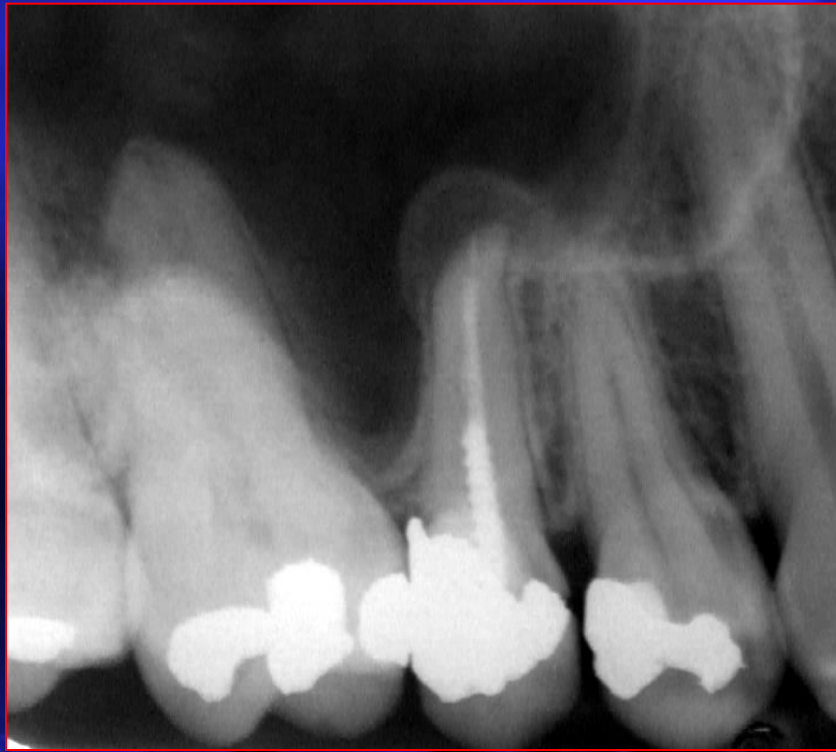Extraoral signs of bruxism



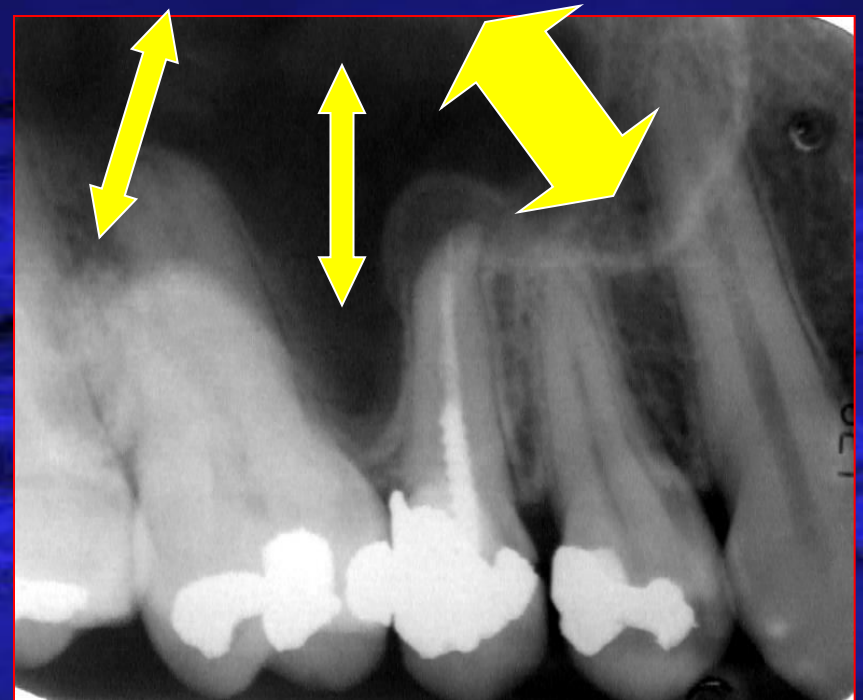
Horizontal cuts in a 3D image



Sinuses



Hiperpneumatic sinus



Lingual Parafunctions

Signs:

Deshiscencies.

Anocclusions, extrusions, tilting.

Diasthems.

“Lingua serrata”.

Burning syndrome (may be).

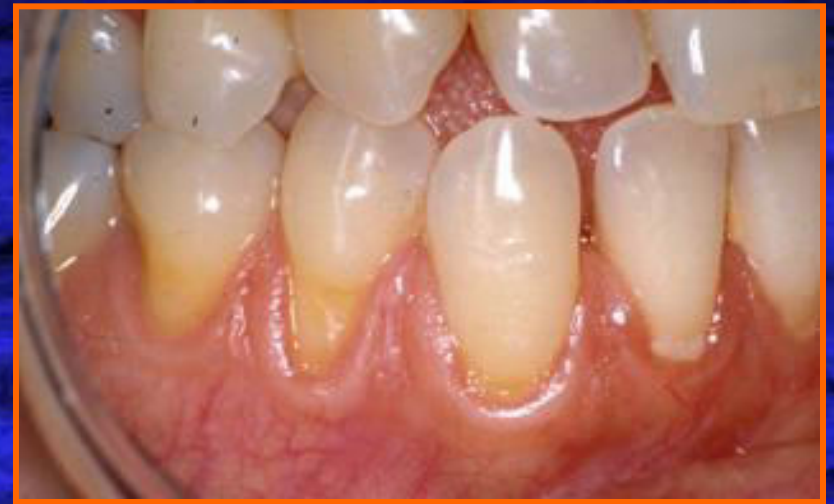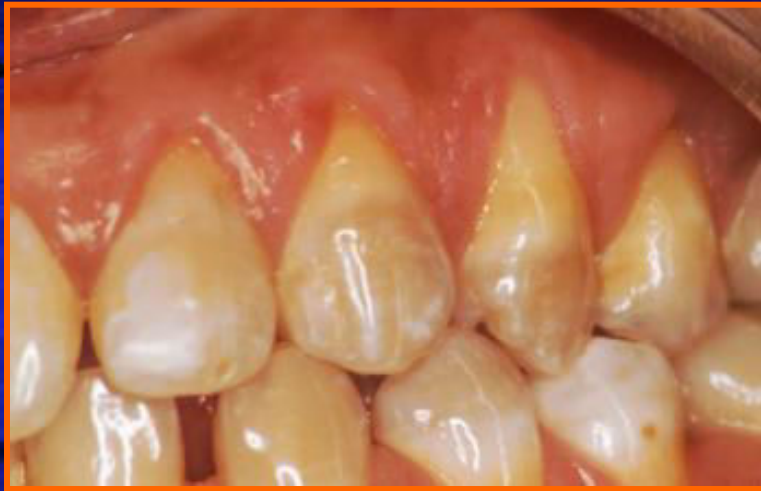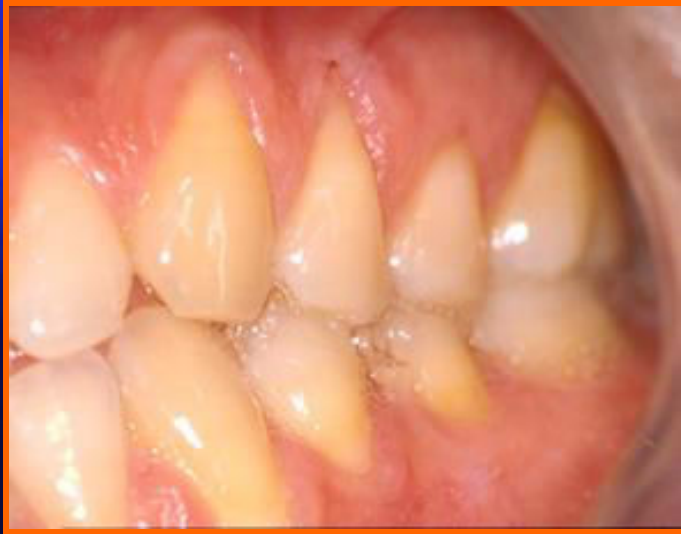Gingival and mucosal growths.

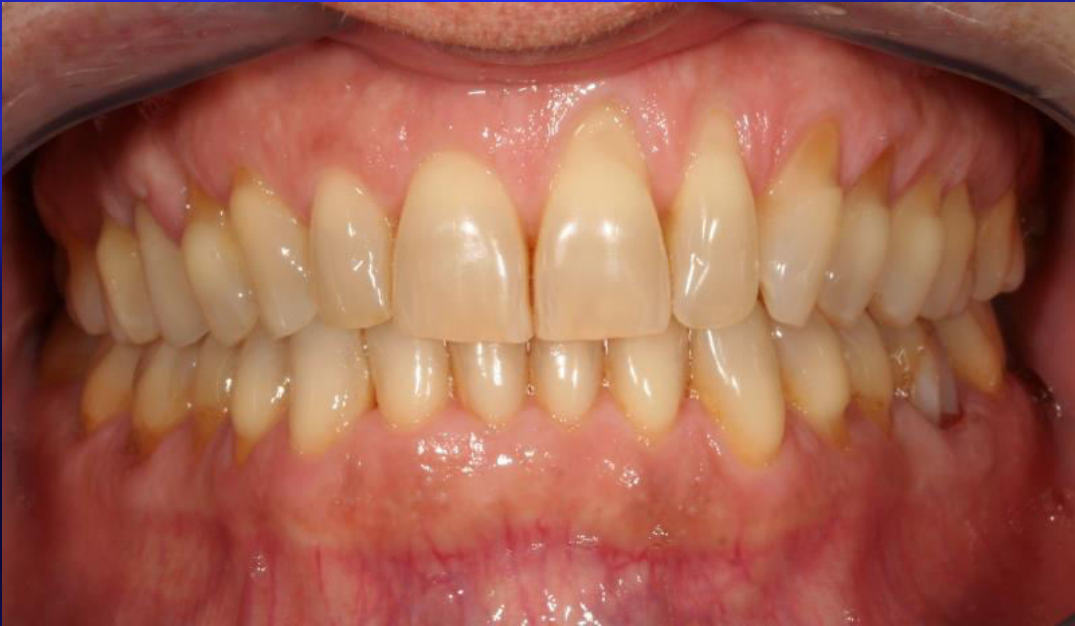Black interdental triangles.

Glossodinitias.

Dehiscenties

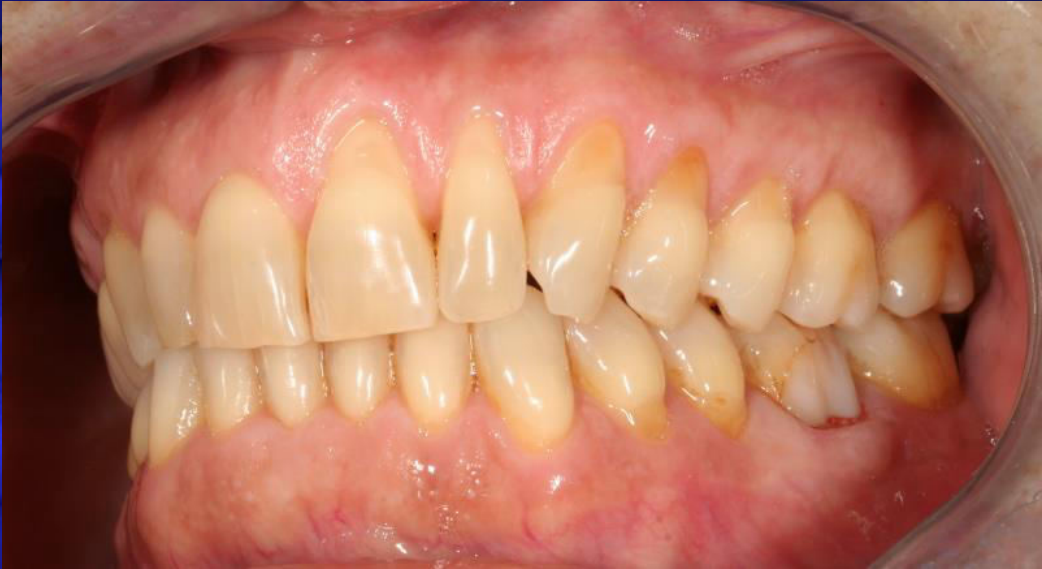Tongue pushes teeth outward putting pressure on the thin osseous vestibular crest, pressure promotes reabsorption. Bad brushing and bruxism can aggravate the signs.



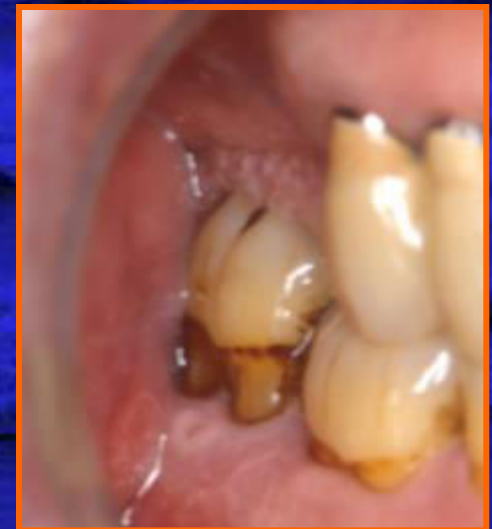
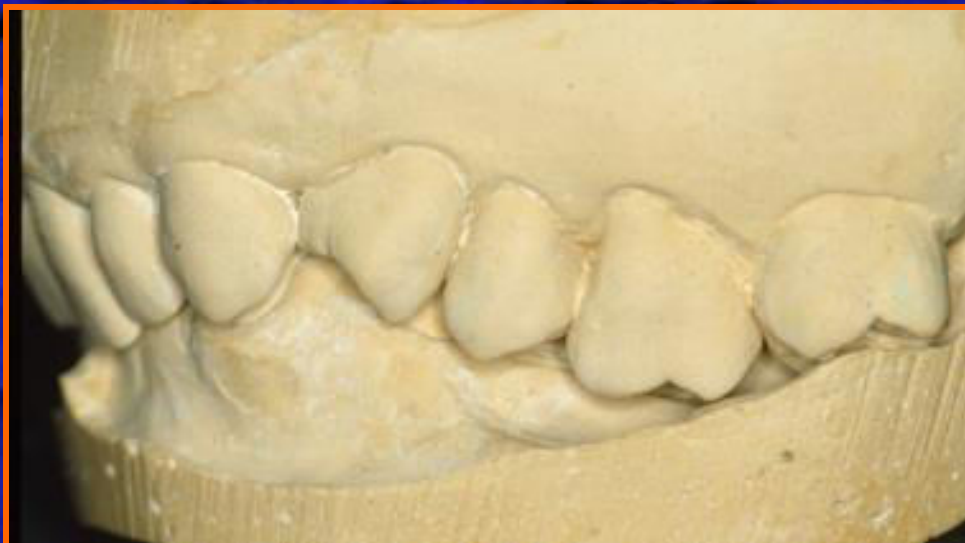
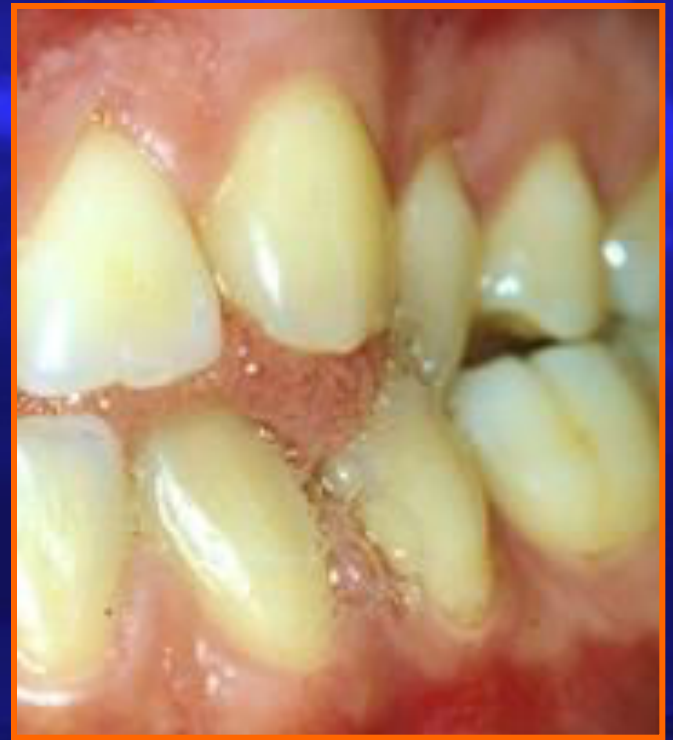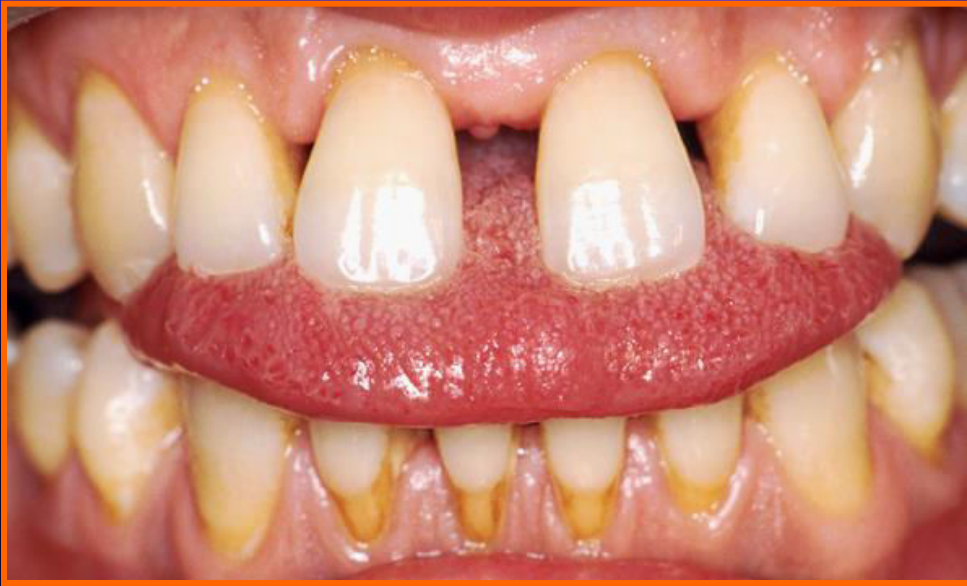¿Why?

No occlusal trauma
No excessive brushing
Not periodontal
disease



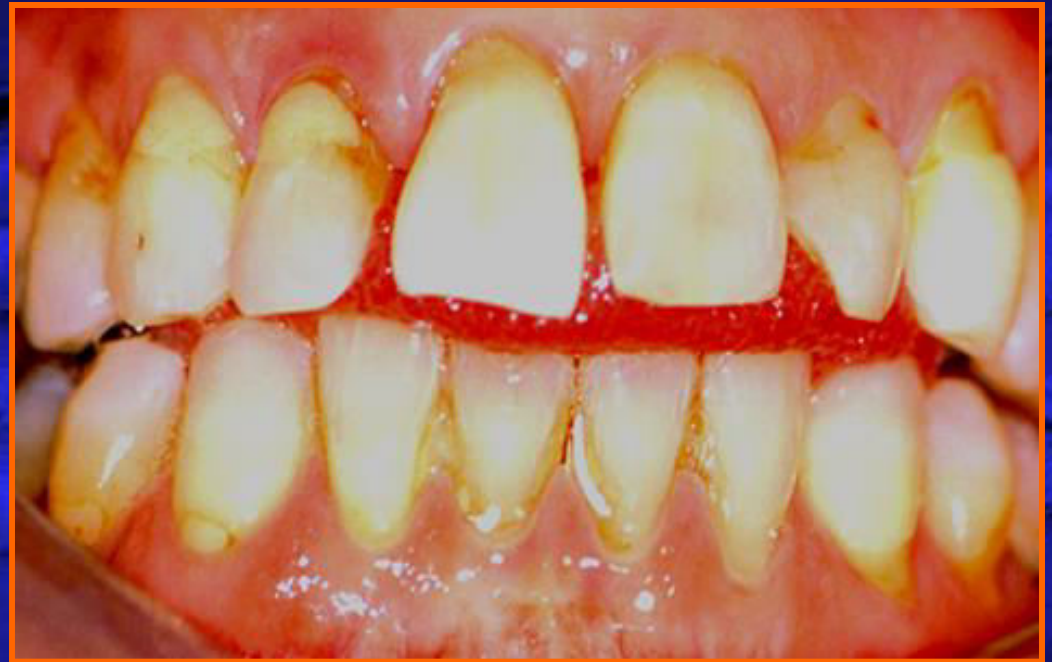- **Extrusions**
- **Migrations**
- **Anocclusions**

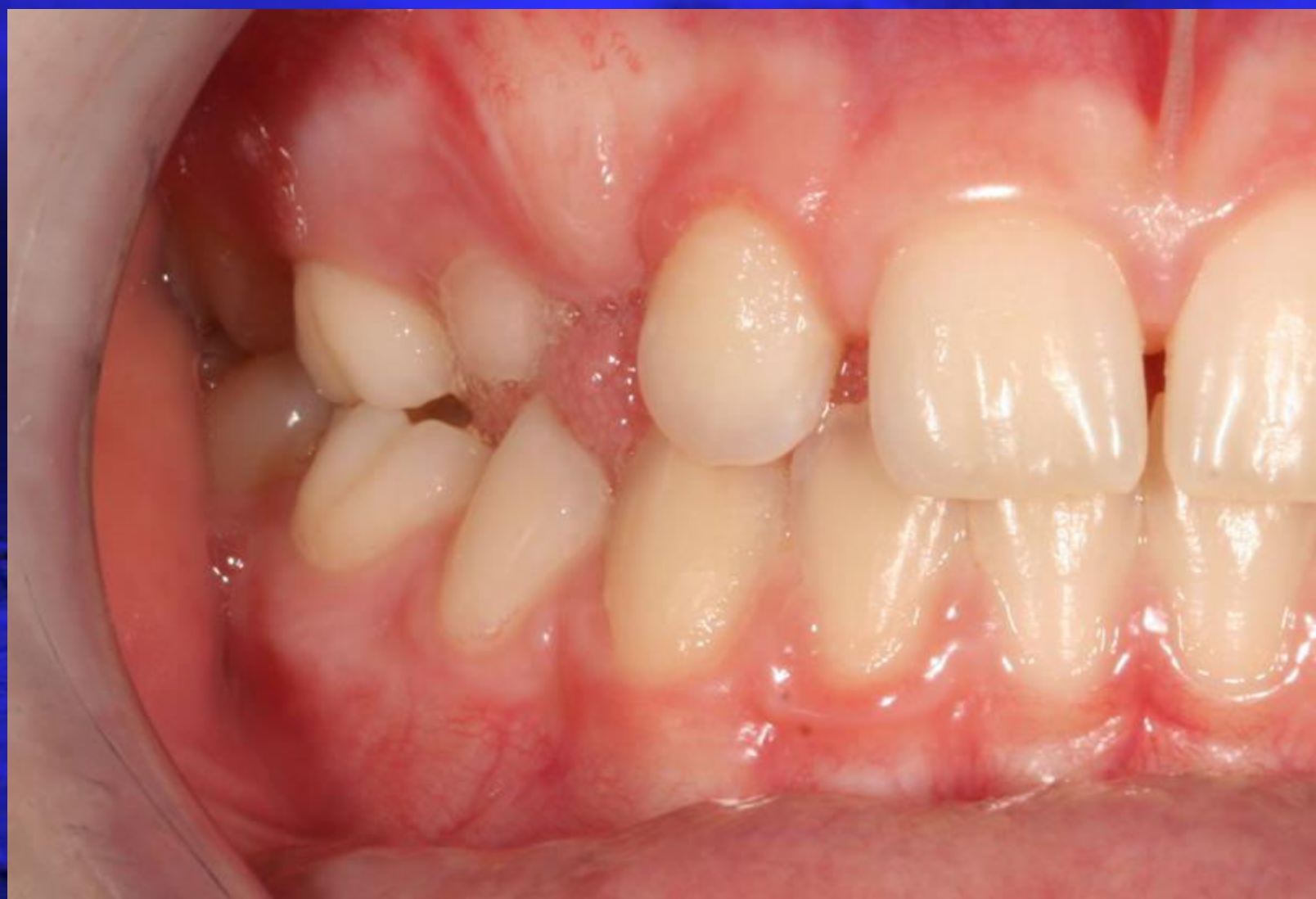


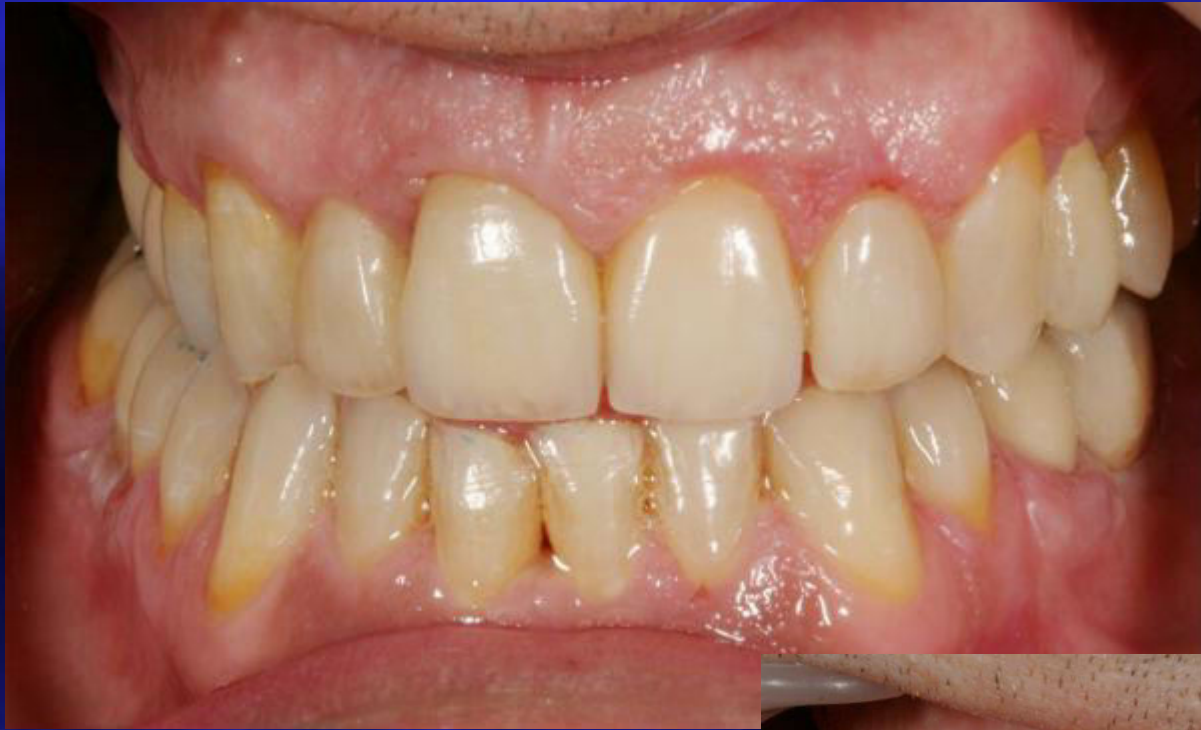
Interdental separation

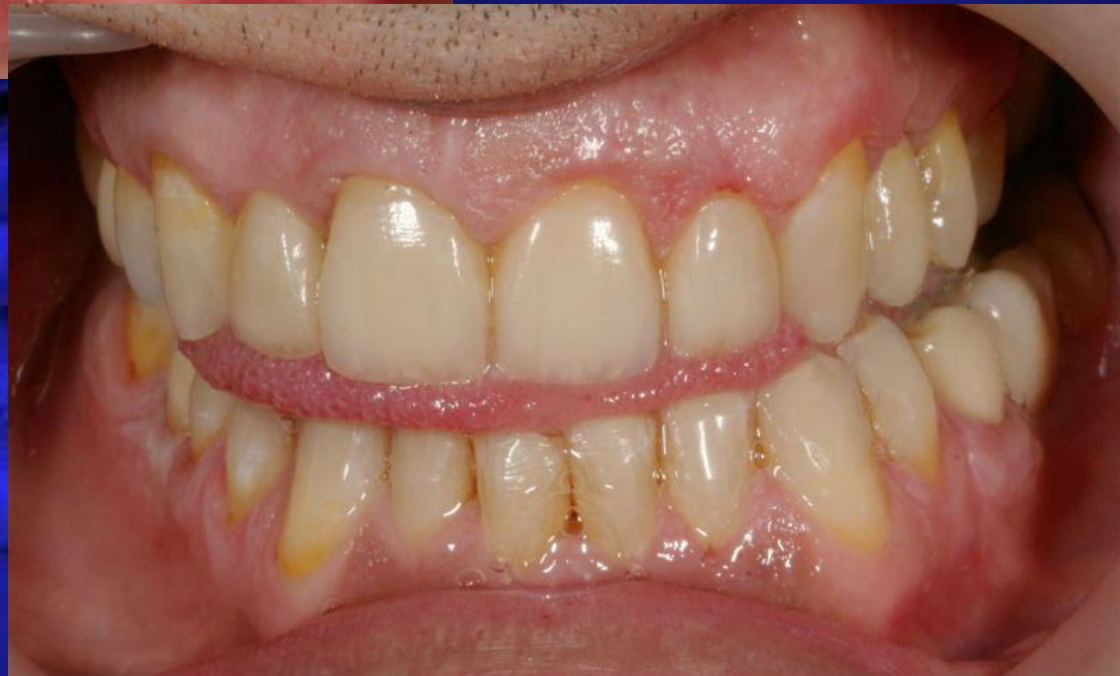Tongue is always Present.





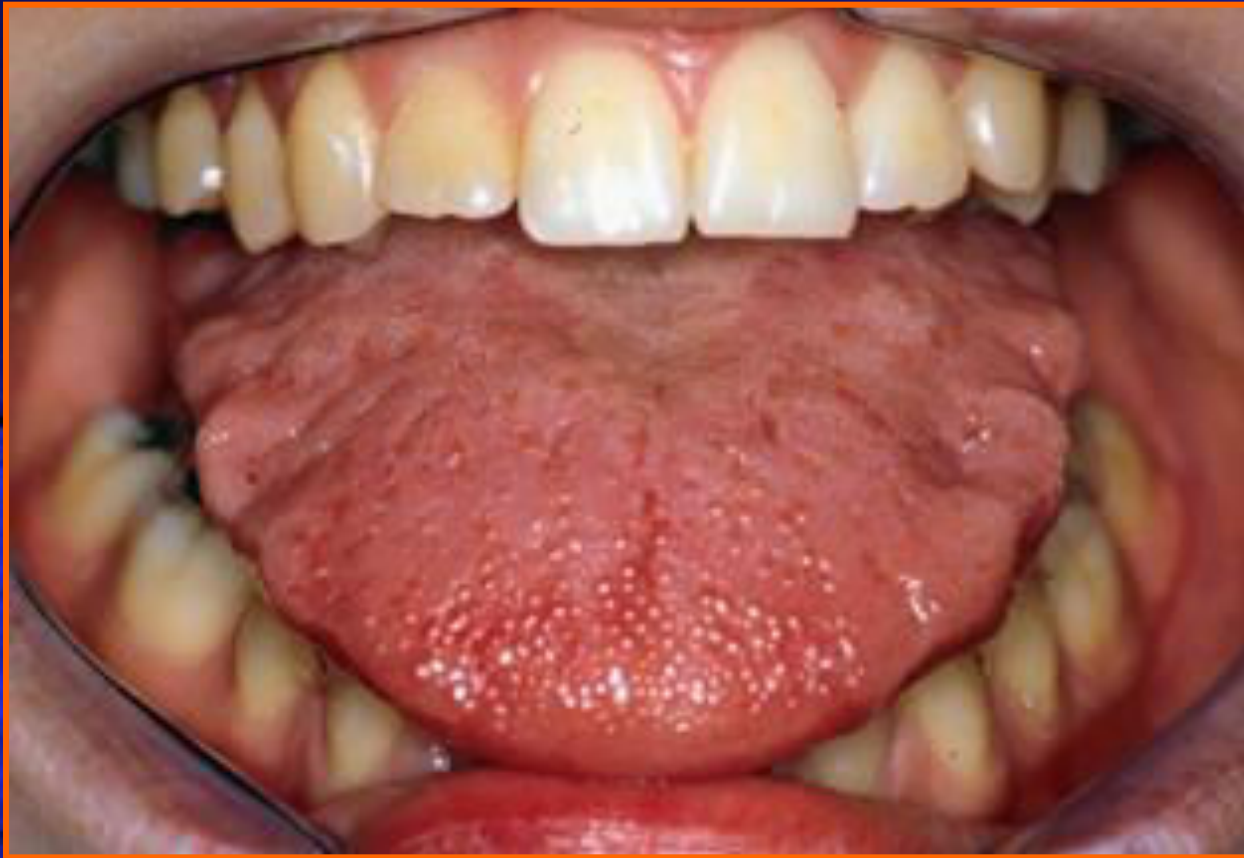

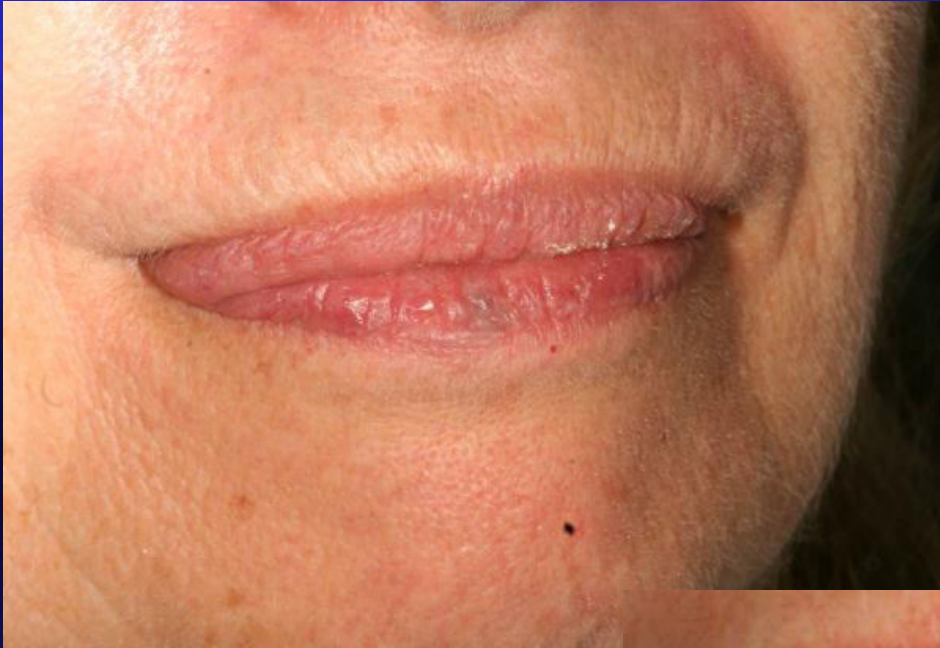If in talking face to face we can see a bit of tongue, we could infer that there is tongue thrust



“Lingua serrata”

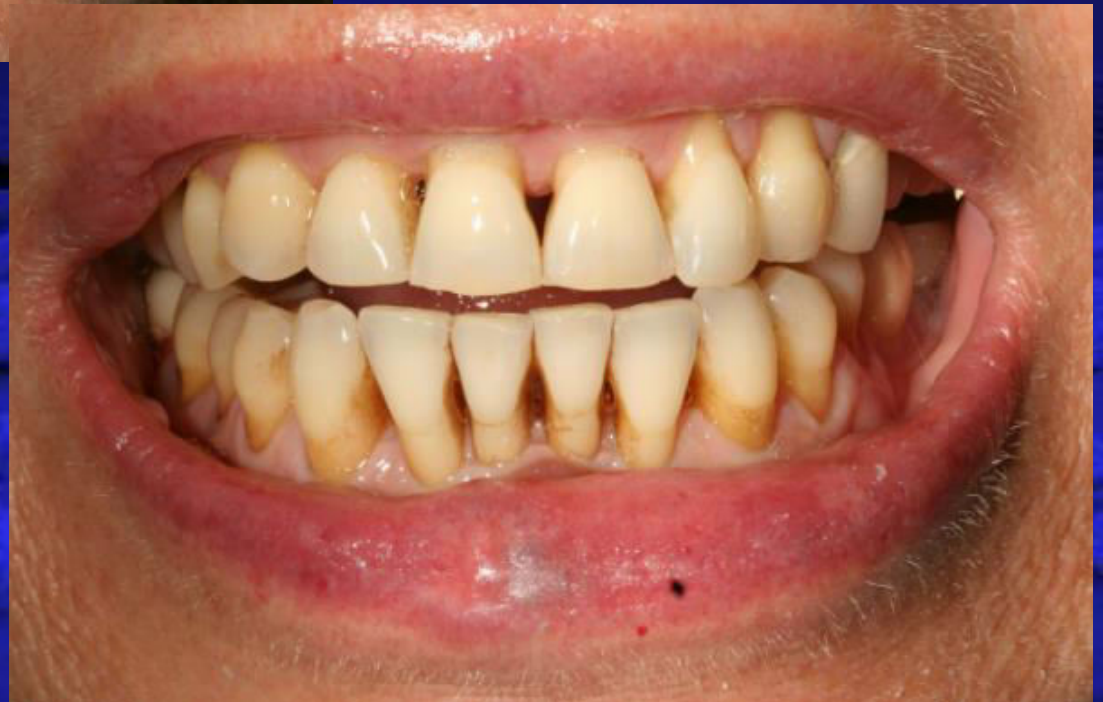The outer aspects of the tongue reproduces the inner aspects of the dental arch





If we see, when subject swallows, a contraction of the orbicularis m. like the one in the first image.

Frequently the display of the teeth is like this one.



Downward pull of the tongue

If normal; good adaptation of all the soft tissues, especially the gums to the teeth.

If excessive; suction, aspiration of the inner mucosa of the lips and cheeks, disappearance of papillae, extrusions.

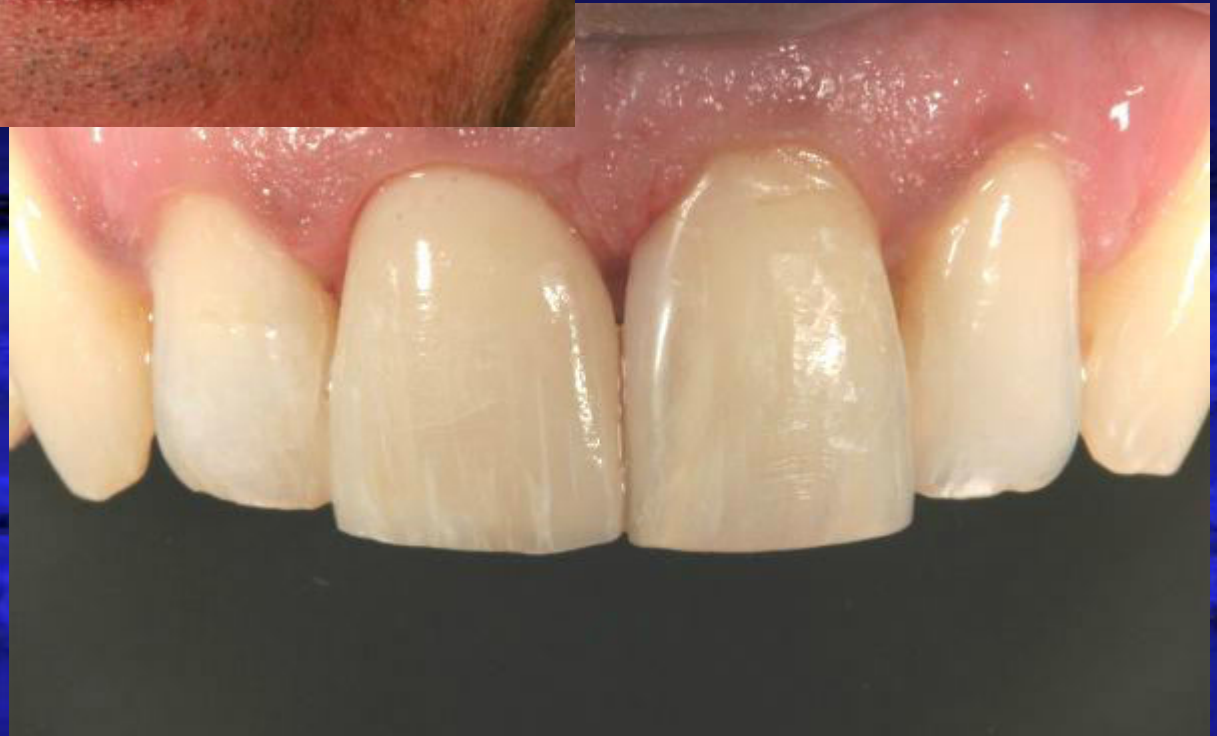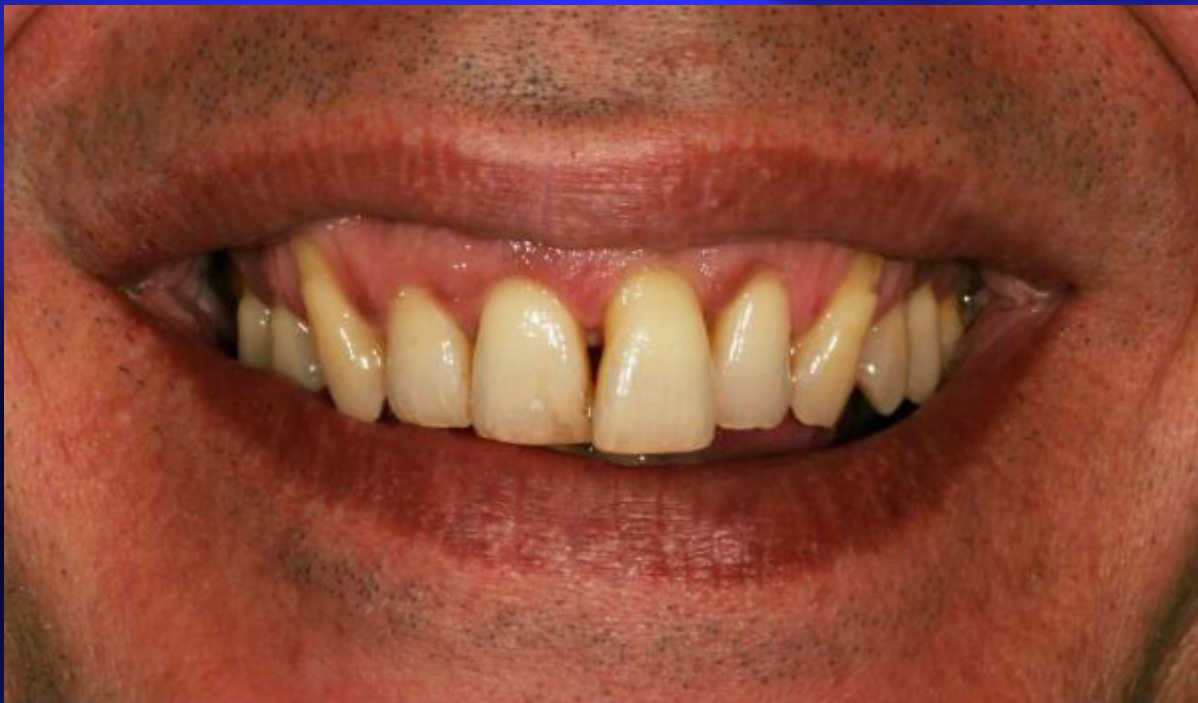Actions: Reeducation; and if it's possible download the contact point between teeth, stabilize the occlusal plane.

**Frontal, lateral or asymmetrical pull
of the tongue.**

Diastemas, extrusions, migrations, dehiscence.

Actions: Reeducation, orthodontics, stabilization, ferulization.

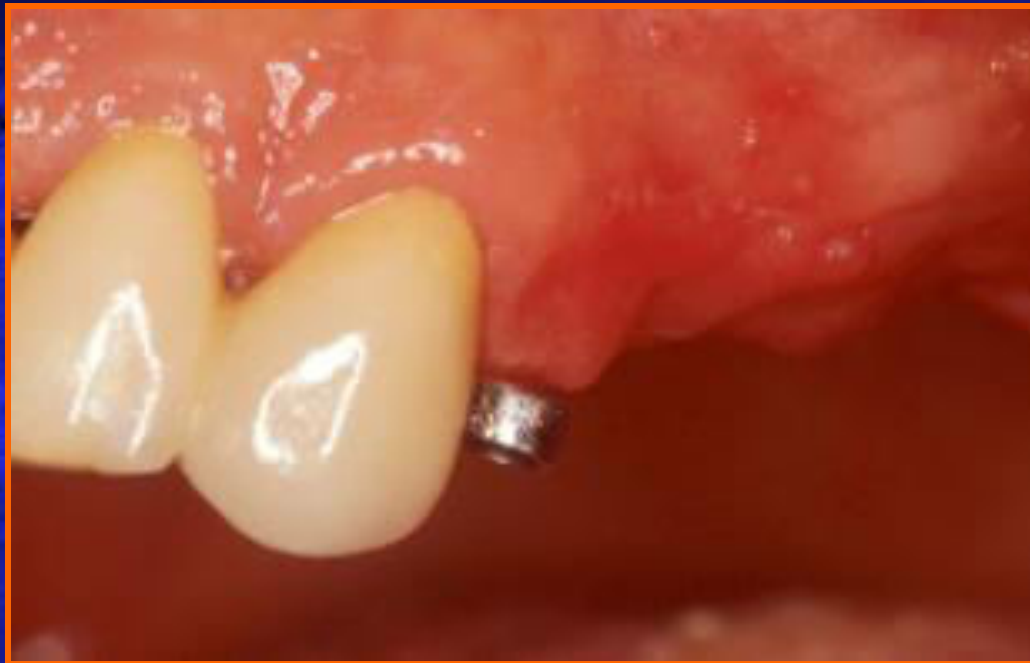**If nothing more is possible Dental plate with anterior rim or
vestibular arch.**

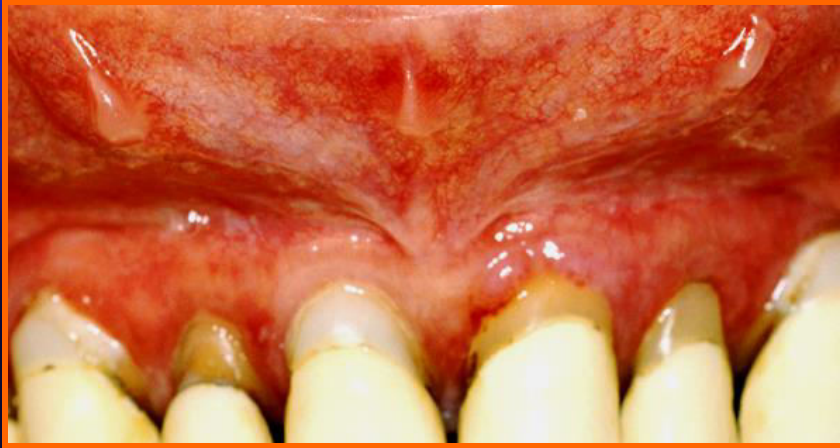

**Unforeseen effect of the
continuous suction on a
teeth.**

ELONGATION

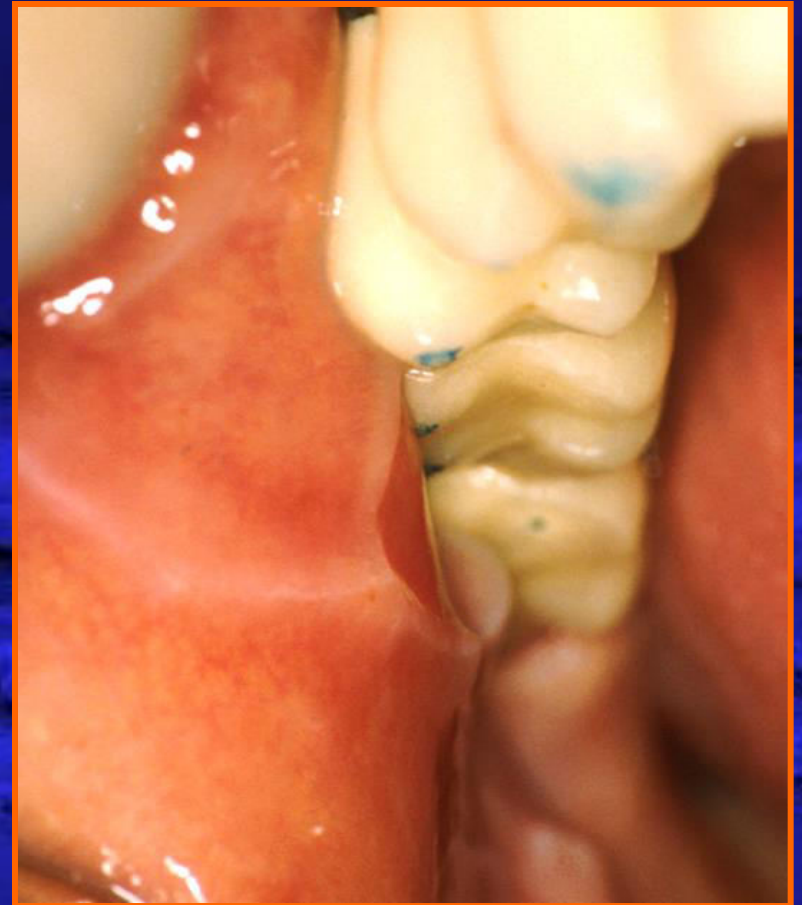The soft tissues adapt over the hard materials. Here molded gingiva under a external attachment

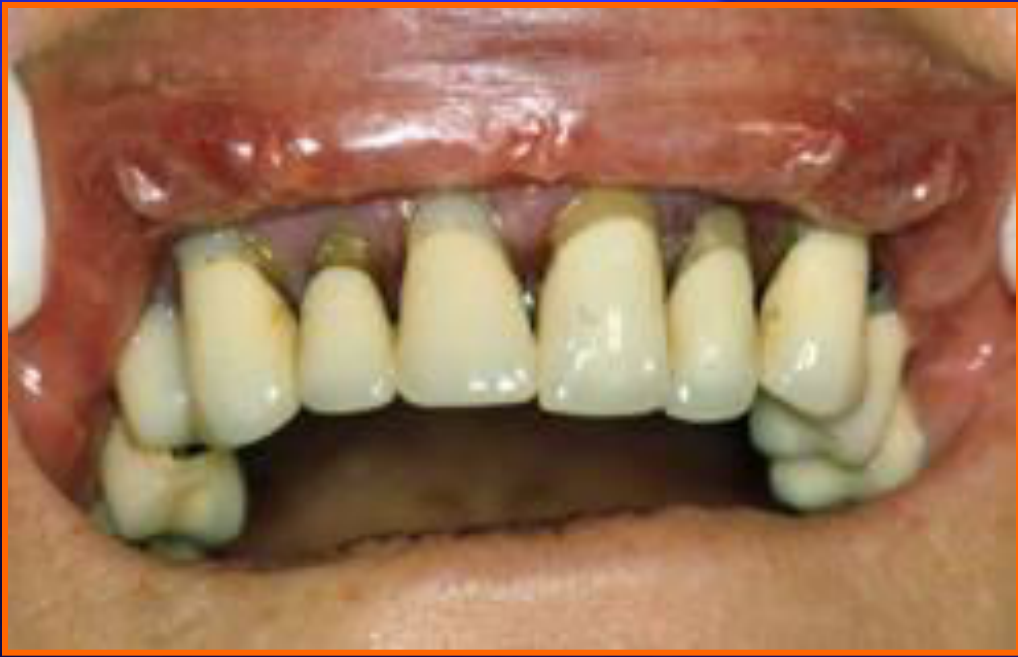



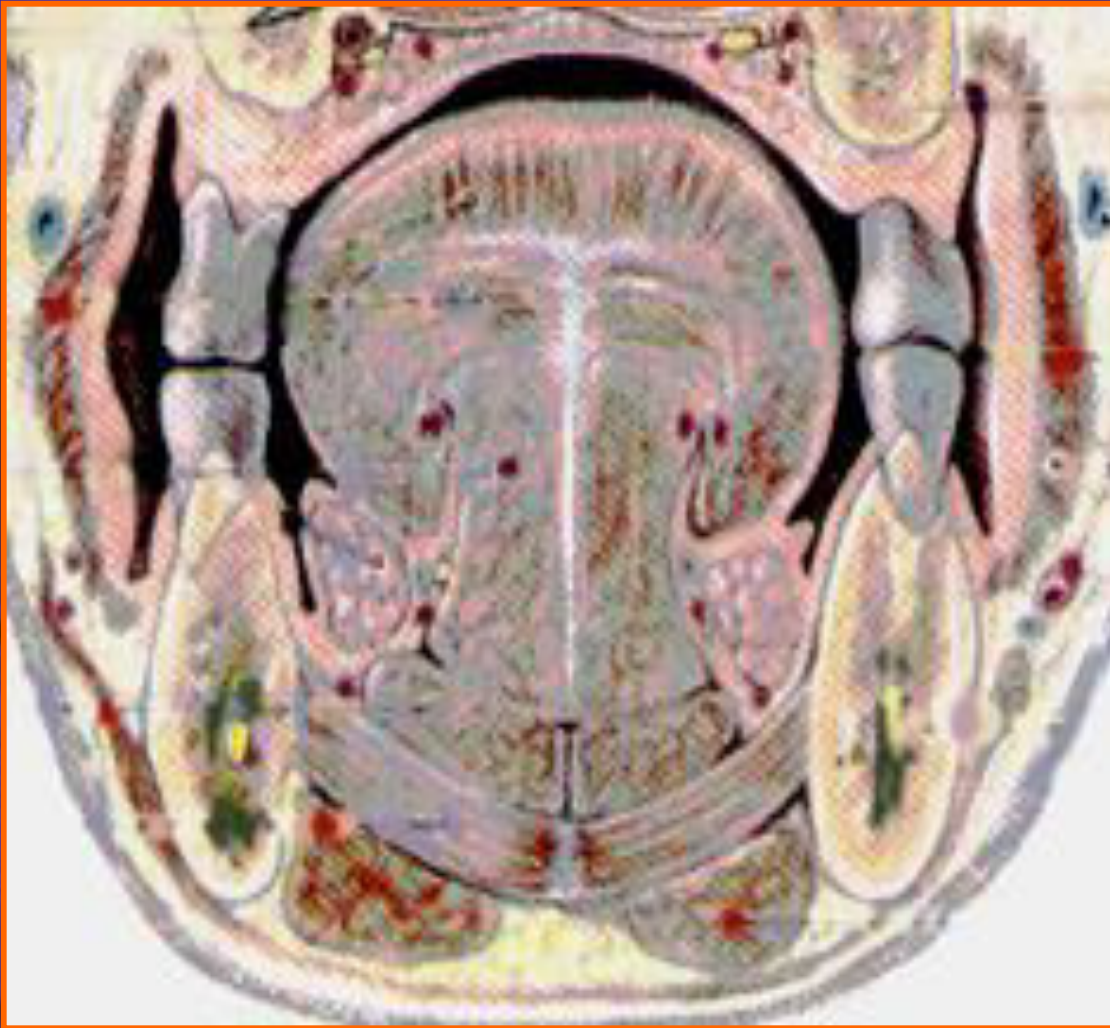Papilla are not on the gums
but in the inner aspect of
the lip.

Hipertrophic "linea molaris"



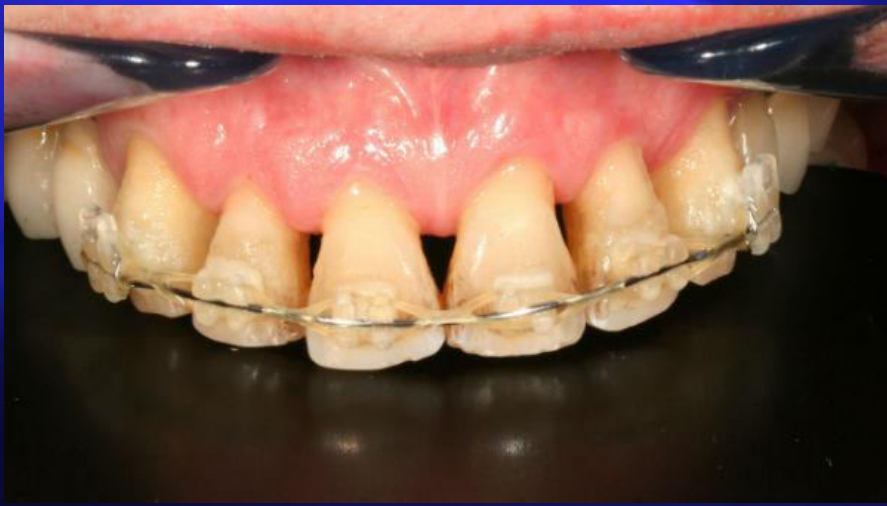

Glossodinitias, pharyngeal pain, geographic tongue, burning tongue, metallic taste, “lingua serrata”, lingual papilomas, stiffening of the horizontal “Linea molaris”, papilomas of the central bridle, every mucosal growth, pulpar papilomas included; can arise from a sole cause: “Diapneusias”. It is the same as saying: suction, local changes in the balance of intraoral vacuum.



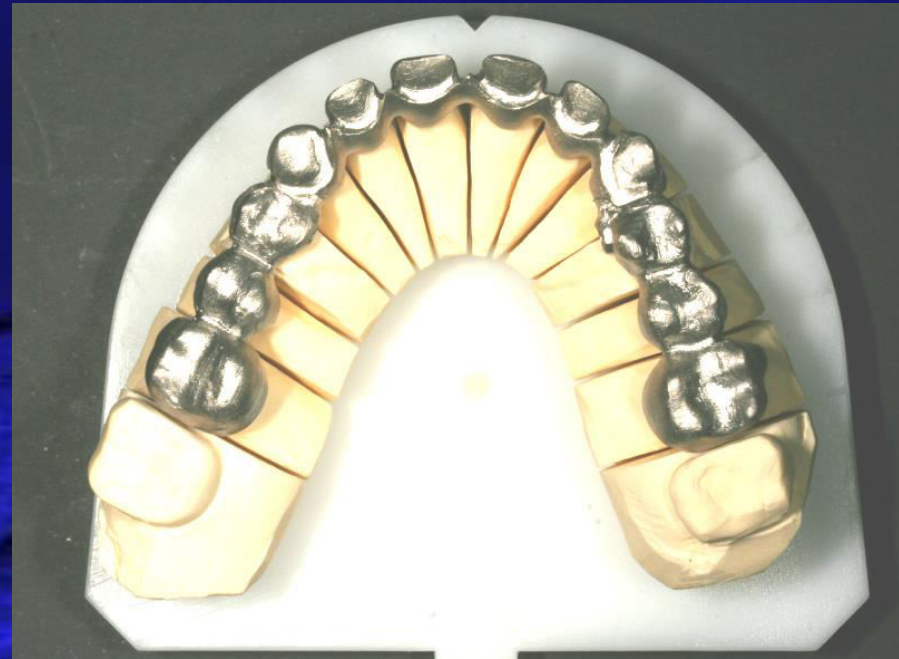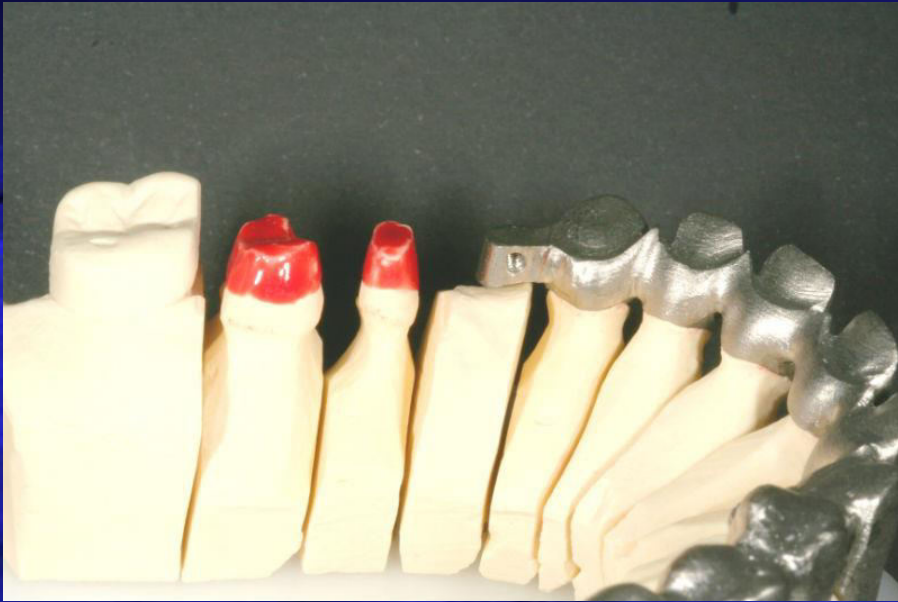
Oral pneumatic pump

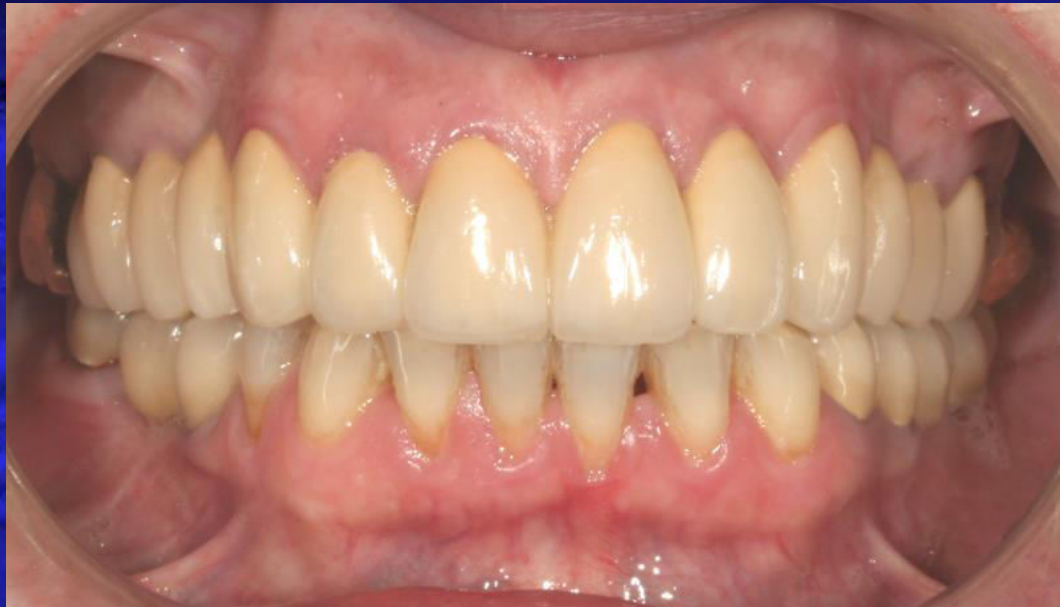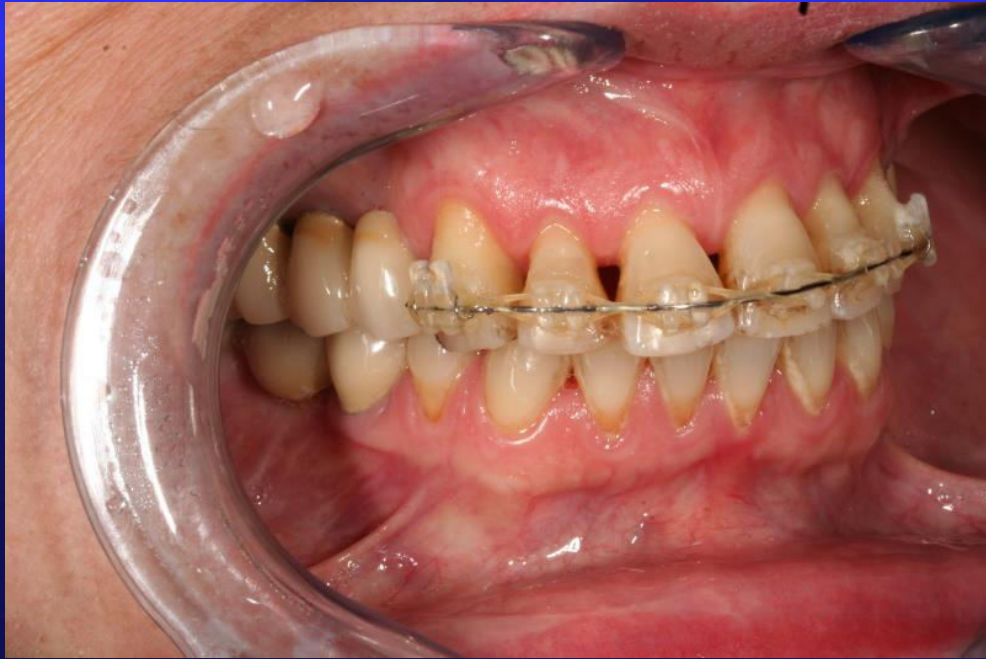The tongue is the “plug” when tractioned down by the activity of the infrahyoid mussels.

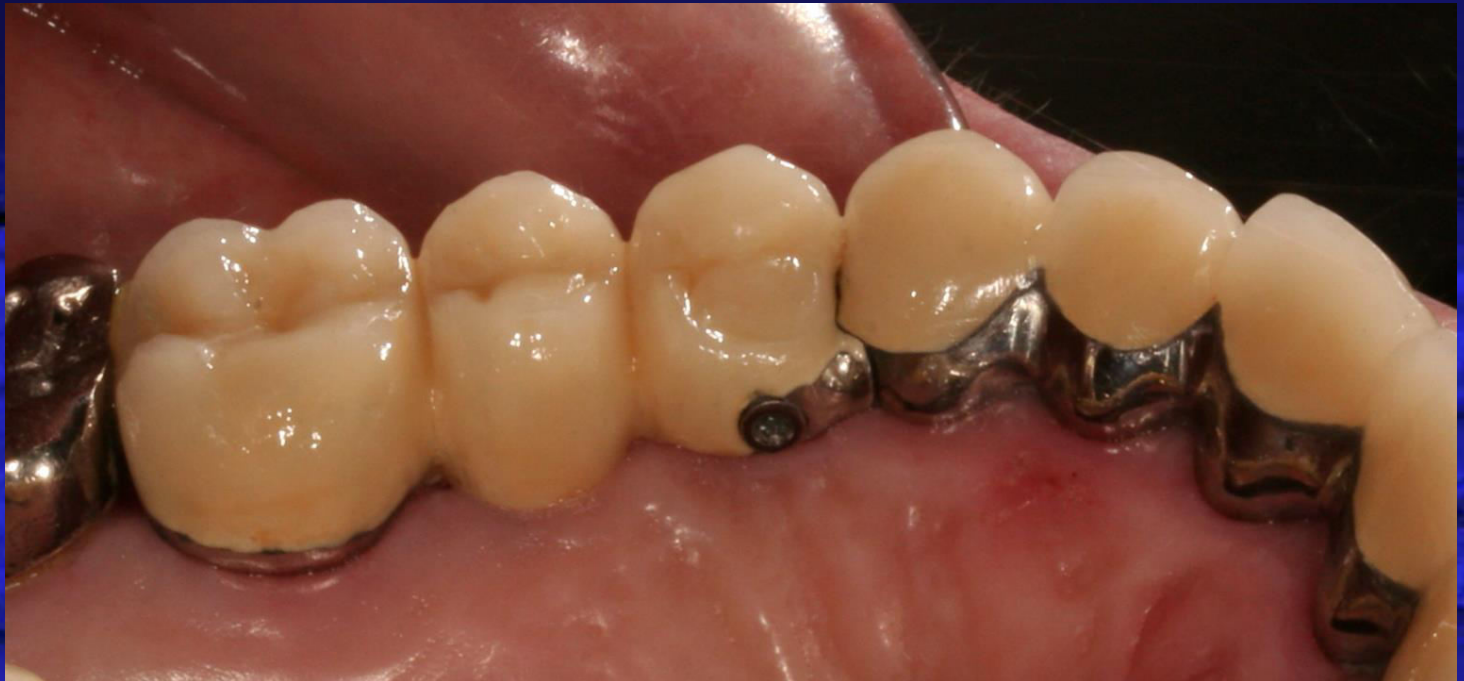
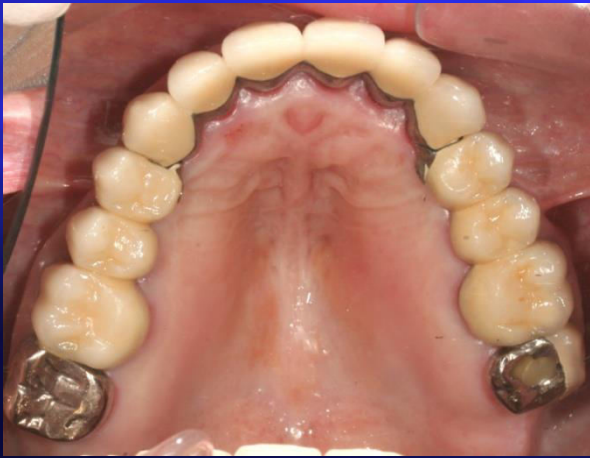
Fighting the tongue push.

- a) Orthodontic alignment.
- b) Metal ceramic contention.
- c) Segmentation: Three different segments united by semi rigid custom made connectors.



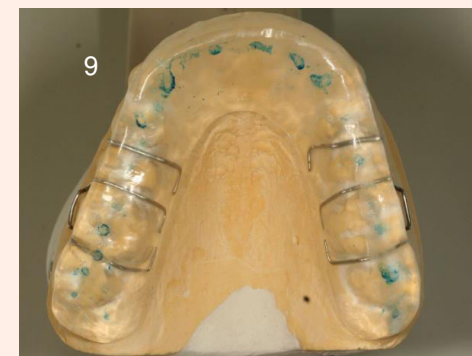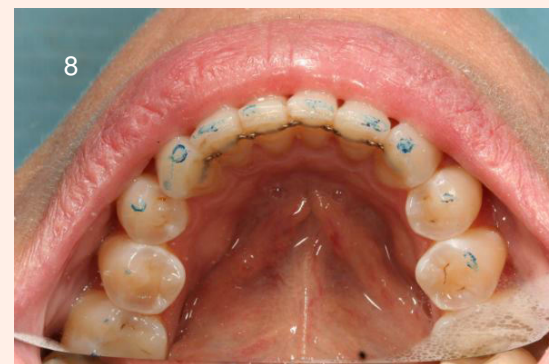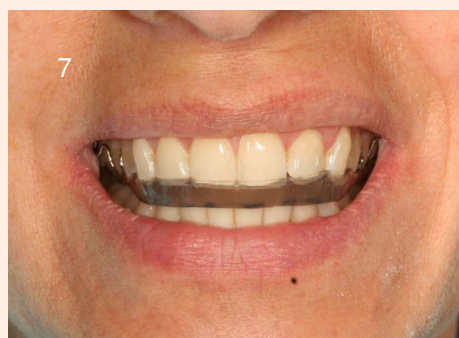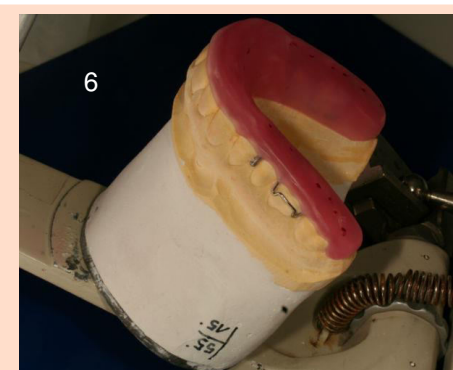
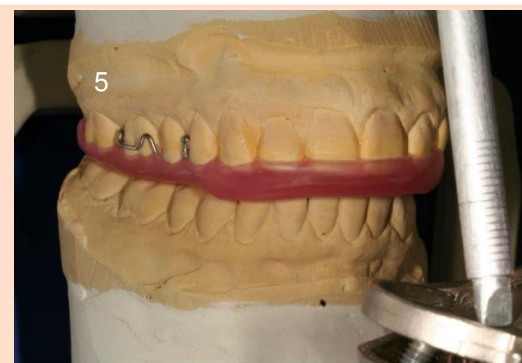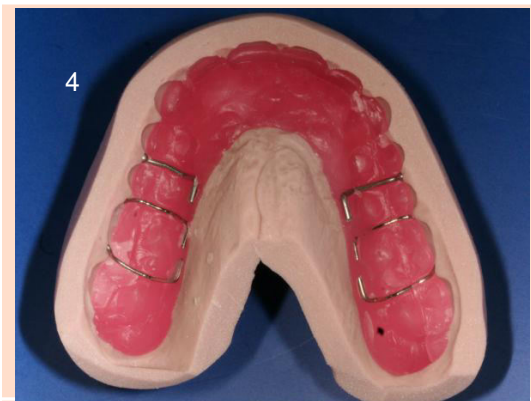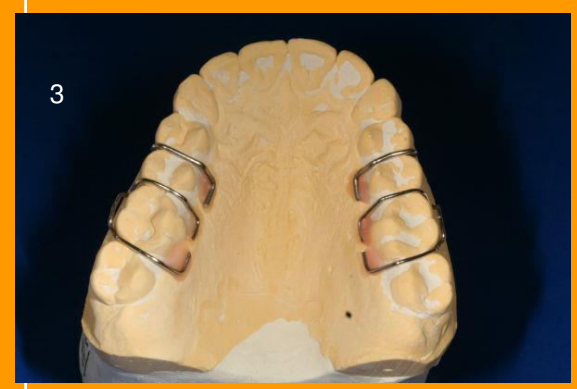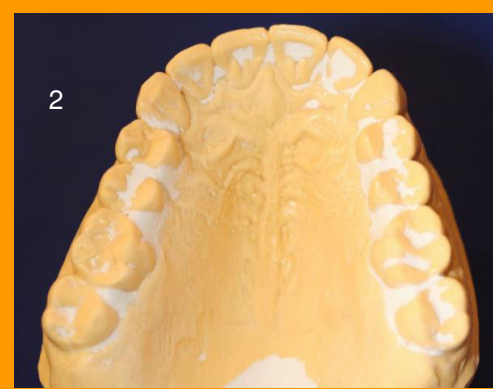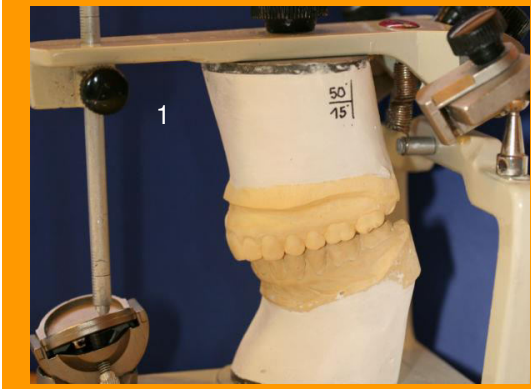




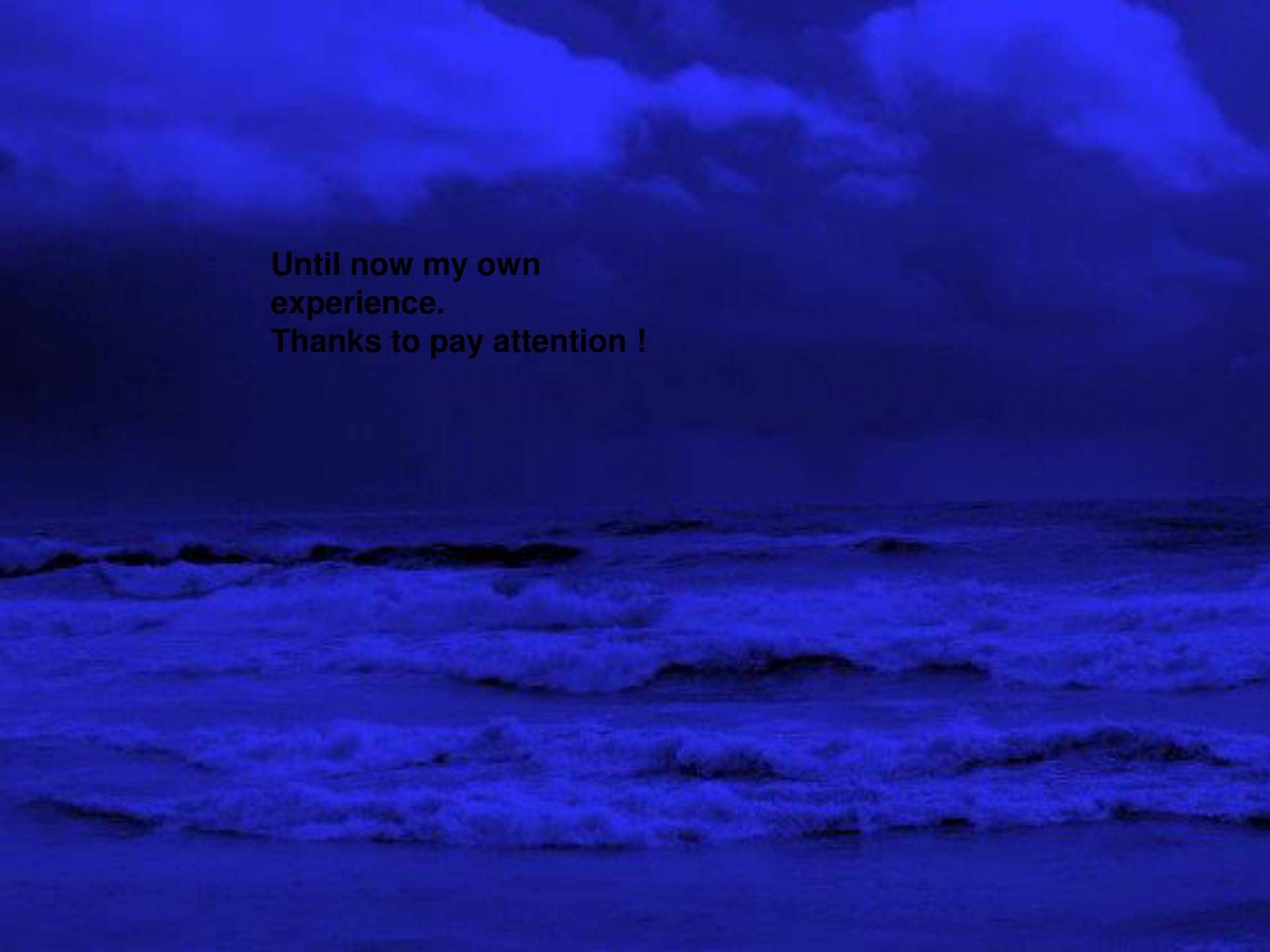


Most of parafunctional symptoms, specially the ones related to bruxism, can be alleviate by an occlusal bite plate but...

It has to be carefully build



1. **Good hart stone models, from alginate imprints (if possible booth vacuum mixed).**
2. **Duly mounted on a semiajustable articulator.**
3. **Retentive zones in the cast well obliterated with gypsum.**
4. **Retention by Adams clasp and ball ones.**
5. **Wax carefully modeled in the range of the articulator function.**
6. **Little Incisal edge if necessary to contain the push of the tongue.**
7. **Distributed contacts on a curved Wilson plane (avoid deep ones).**
8. **Process with acrylic under pressure and high temperature.**
9. **Adjust in mouth with watchful precision.**
10. **Obtain symmetrical an distributed contacts in near centric relationship.**

A blue-tinted photograph of a beach. The foreground shows the wet sand of the beach. In the middle ground, several waves are breaking, creating white foam. The background is a cloudy sky. The text is overlaid on the left side of the image.

**Until now my own
experience.
Thanks to pay attention !**