

## Amniotic Band Syndrome with Craniofacial Region Deformity - A Case Report

Solomon Gebre<sup>1</sup>, Ermias Abate<sup>2</sup> and Awol Yeman<sup>2</sup>

<sup>1</sup>Department of Integrated Emergency Surgery and Obstetrics (IESO), Mearg General Hospital, West Tigray, Ethiopia

<sup>2</sup>Department of Obstetrics and Gynecology, Ayder Comprehensive Specialized Hospital, Mekelle University, Tigray, Ethiopia

\*Corresponding authors: Solomon Gebre, Department of Integrated Emergency Surgery and Obstetrics (IESO), Mearg General Hospital, West Tigray, Ethiopia, Tel: 251911366834; E-mail: [solomonunlka@yahoo.com](mailto:solomonunlka@yahoo.com)

Received date: February 05, 2018; Accepted date: February 19, 2018; Published date: February 28, 2018

Copyright: © 2018 Gebre S, et al. This is an open-access article distributed under the terms of the Creative Commons Attribution License, which permits unrestricted use, distribution, and reproduction in any medium, provided the original author and source are credited.

### Abstract

Amniotic band syndrome is one of the uncommonly seen congenital deformity that can lead to a wide range of structural abnormalities mostly involves limbs but may affect the craniofacial region and trunk. In this report, we describe the case of A 30 years old Gravida 4 Para 3 who presented at gestational age of 28+4 weeks for Antenatal care follow up at Mearg general hospital, in Northern Ethiopia. The pregnancy was terminated after ultrasound showed a severely malformed fetus. Amniotic band syndrome is seen very uncommonly, but there should be high clinical suspicion in the presence of congenital deformity. In a setup where ultrasound is readily available Amniotic band syndrome can be diagnosed intrapartum, otherwise the defects are seen in the postpartum period. Surgical treatment with an Interdisciplinary approach to every single case is the main stay of therapy in managing Amniotic band syndrome. Fetus with deformities that are incompatible with extra uterine life, pregnancy should be terminated after informed consent is collected. We therefore report a case seen with the aim of highlighting its existence in this region and to point out diagnostic and therapeutic approaches inn pregnancy with Amniotic band syndrome in a low resource setting through this case report.

**Keywords:** Amniotic band syndrome; Congenital deformity

### Introduction

Amniotic band syndrome is a rare congenital deformity associated with wide range of structural abnormalities commonly involves limbs. Amniotic bands also called constriction bands, congenital ring, streeter dysplasia. Sequence bands and annular defects are anomalous bands that encircle either partially or completely a digit or an extremity [1].

The clinical presentation ranges from simple soft tissue constrictive bands to amputation of digits or more severely the whole limb due to dysplastic vasculature. The prevalence of Amniotic band syndrome is 7.7/10,000 live birth and as high as 178/10,000 among abortions [2,3]. In Nigeria there is a report 0.16-3% prevalence of Amniotic band syndrome [4,5]. In Ethiopia there are no reported cases of Amniotic band syndrome to date. We therefore report a case seen with the aim of highlighting its existence in this region.

### Case Report

A 30 years old Gravida 4 Para 3 (all alive and healthy) came for ANC follow up at a gestational age of 28<sup>+</sup>4 weeks. She had regular ANC follow up at Mearg General Hospital, in Northern Ethiopia. She had no history of drug intake and no history of chronic medical illness. Her laboratory investigations like VDRL were normal. Ultrasound finding were a severely malformed fetus. The detailed sonographic findings were, the fetus had anencephaly, grossly excessive amniotic fluid, gestational age by femoral length was 22 weeks.

After discussion with mother and written informed consent obtained pregnancy were terminated with misoprostol per the hospital protocol. The fetal was found to have absent cranial vault, cleft palate,

absent orbits, absent auricles, no abdominal wall defect, well-formed extremities, well-formed vertebral bones and 3 vessel umbilical cord. These defects are so divers that the pathogenesis of this condition cannot be explained by a single mechanism (Figure 1).

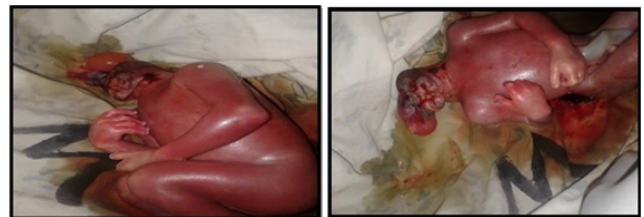


Figure 1: Amniotic band syndrome.

### Discussion

Amniotic band syndrome comprises of a spectrum of anomalies which vary in severity. The triad ABS includes amnion-denuded placenta; fetal attachment or entanglement by amniotic remnants; fetal deformation, malformation and/or disruption [6,7]. The malformations in the case described illustrate the wide range of defects seen in ABS. ABS etiopathogenesis is still unknown, but there are main theories [8-11]. Widely accepted "extrinsic model", proposed by Torpin and Faulkner in 1996 explains defect genesis by rupture of amnion in early pregnancy. With forming of amniotic band and amniotic liquids loss, following by extrusion of all or parts of the fetus in to the chorionic cavity. Band entrap the parts of the engrowing fetus, therefore fetus limbs and other body parts are subjected to compressions, which compromises fetal circulation and then fetal

growth and development by consecutive disturbances of fetal physiology and anatomy. The intrinsic model was proposed by Steeter in 1930 and suggests that the anomalies and the fibrous bands have a common origin, caused by a perturbation of developing germinal disc of early embryo. Beside ABS etiopathogenesis, risk factors which start such sequence of events are also poorly known. Most cases of ABS are not of genetic origin, and there is no recurrence in sibling or children of affected adults. However, there are some reports of ABS families with collagen disorders, more specifically Ehler-Danlos syndrome [12].

Some other possible etiology factors besides inheritance were explored in several studies none of which our patient had [13-17].

Beside all previously mentioned malformations caused by amniotic bands itself, a subset of cases manifest additional finding that are not consistent with that mechanism [18]. In the case presented polyhydramnios is not explained.

Amniotic band syndrome can be diagnosed by sonographic examinations in the prenatal period, which can sometimes amniotic bands, but more often malformations consistent with ABS, as well as oligohydramnios and reduction of fetal movements. Physical examination is the main stay of postnatal diagnosis of ABS [19,20].

Surgery is the main stay therapy in most cases ABS, with an individual approach to every single cases. Interdisciplinary consulting and work is very often needed (Plastic surgeon, Orthopedic surgeon, Orthodontist, Ophthalmologist and Neurologist) [21].

Like in this case when fetal anomalies incompatible with life are prenatally seen, pregnancy termination is advised [12].

## Conclusion

Fetal congenital deformities brings with the multiple challenges to the treating obstetrician/clinicians, that of detecting the congenital anomalies in the fetus, predicting the prognosis about them and informing the parents, terminating the pregnancy in appropriate situations. Prenatal sonographic examination helps us in diagnosing these anomalies in early pregnancy. Physical examination is the main stay postnatal diagnosis of Amniotic band syndrome.

## References

1. Bhagyashri Bora RR, Priti Mhatre (2016) Amniotic Band Syndrome-A Case Report. *Pravara Med Rev* 2: 20-24.
2. Buyse ML (1990) *Birth Defects Encyclopedia*. Cambridge (MA): Black Well scientific publications.
3. Seeds JW, Cefalo RC, Herbert (1982) Amniotic band syndrome. *Am J Obstet Gynecol* 144: 243.
4. Oyinbo CA, Dare NW, Amain ED (2009) Prevalence of Polydactyly, Syndactyly, Amniotic band syndrome, Cleft lip, Cleft Palate, and Talipes Equinovarus in Bayelsa state, Nigeria. *J Med inf Biomet epidemiol* 5: 1-5.
5. Barkare TIB, Sowande OA, Adejuyigbe OO, Chinda Y, Usang (2009) Epidemiology of External Birth Defect in Neonates in Southwest Nigeria. *Afr J Paediatr Surg* 6: 28-30.
6. Kulkarni ML, Gopal PV (1990) Amniotic Band Syndrome. *Indian Paediatr* 27: 471-476.
7. Higginbottom MC, Jone KL, Hall BD (1979) The Amniotic Band Disruption Complex: Timing of Amniotic Rupture and Variable Spectra of Consequent Defect. *J Paediatr* 96: 544-549.
8. Robin NH, Franklin J, Prucka S, Ryan AB, Grant JH (2005) Clefthifting, Amniotic Bands and Polydactyly: A Distinct Phenotype that Supports an Intrinsic Mechanism for Amniotic Band Sequence. *American Journal of Medical Genetics* 3: 298-301.
9. Lateo Sa, Taylor AE, Meggitt SJ (2006) Raised Limb Bands Developing In Infancy. *Br J Dermatol* 4: 791-792.
10. Werler MW, Louik C, Mitchell AA (2003) Epidemiological Analysis of Maternal Factors and Amniotic Band Defect. *Birth Defects Res A Clin Mol Teratol* 1: 68-72.
11. Fathallah ZF (2007) Unusual Presentation of Amniotic Band Syndrome. *Bas J Surg* 11: 77-79.
12. Burk CJ, Aber C, Connelly EA (2007) Ehlers-Danlos Syndrome Type Iv: Keloidal Plaques of the Lower Extremities, Amniotic Band Deformity and A New Mutation. *J Am Acad Dermatol* 2: S53-S54.
13. Dyer JA, Chamlin S (2005) Acquired Raised Bands of Infancy: Associated with Amniotic Bands. *Pediatric Dermatology* 22: 346-349.
14. Clarke JC, Becker EJ, Salonen DC (2000) Amniotic Band Syndrome. *Can Assoc Radiol J* 51: 134-136.
15. Ferns S, Sharma R, Narayanan P, Bhat BV (2001) Limb Amputation Defects in Utero- A Case Report. *J Anat Soc India* 2: 156-158.
16. Kanit H, Aslan D, Dicle N, Ugurel G (2001) Amniotic Band Syndrome After Cervical Cerclage. *Perinatoloji Dergisi* 9: 1-3.
17. Baltaci V, Akyol D, Gul D, Sayli BS (1998) Digital Amputations Caused by Amniotic Bands-A Case Report. *Tr J of Medical Sciences* 28: 701-703.
18. Robin NH, Franklin J, Prucka S, Ryan AB, Grant JH (2005) Lefting, Amniotic Bands and Polydactyly: A Distinct Phenotype the Supports an Intrinsic Mechanism for Amniotic Band Sequence. *American Journal of Medical Genetics Part A* 3: 298-301.
19. Allen LM (2007) Constriction rings and Congenital amputation of fingers and toes in mild case of Amniotic Band Syndrome. *Journal of Diagnostic Medical Sonography* 23: 280-285.
20. Merrimen JL, McNeely PD, Bendor-Samuel RL, Schmidt MH, Fraser. Congenital Placental-Cerebra Adhesion: An Usual Case of Amniotic Band Sequence *J Neurosurg* 5: 352-355.
21. Poeuf B, Samson P, Magalon G (2008) Amniotic Band Syndrome. *Chir Main Neurosurg* S1: S136-S147.