

# 7<sup>th</sup> World Nursing Education & Nursing Practice

December 12<sup>th</sup>, 2022 | Webinar

## Rare and interesting case of choroid melanoma presenting as a case of acute congestive glaucoma left eye in a 55 years old male patient

### Abstract

Choroid melanomas are one of the commonest intraocular tumors which are either benign or malignant Pigmented or non-pigmented more common in whites than blacks have got an early tendency for liver metastasis however if diagnosed and treated in time one can prevent liver metastasis. They are 6.5 per million in U S and 7 per million in Denmark and either Scandinavian country. They are 80 percent choroid 12 and 8 percent involve c body and iris respectively very difficult to diagnose due to their atypical manifestations however in most of cases present as solid or exudative retinal detachment on scan ultrasound or indirect OPTHALMOSCOPY. Malignant melanomas of c body yields poor results as far as treatment is concerned

### Results

A 55 years old male patient in year 2011 presented with a TYPICAL presentation of a c glaucoma with severe redness and pain and dyed loss of vision was put on ant glaucoma medication from an ophthalmic ER DEPT OF MEDECAL COLLEGE IN the form of Prostaglandin analogue with timiitol dots eye drops one and 2 drops respectively with topical installation of steroiddrops4vtimes a day with systemic administration of I v 500 ccs of 20 inj manitol and I v 500 mg of acetazolamide even after 6 to 8 hours patient did not show any relief in his signs and symptoms no scan ultrasound was done outwash advised admission which he refused HE REFUSED He went Lama and sought 2nd option of an ophthalmologist whom upon b can ultrasound picked solid retinal detachment was sent for MRI scan brain for radiological confirmation of MELANIMA. Unfortunately radiological report even after repeating 2nd time was so confusing that it created all the confusion so not was left untreated for 2vyears as a painful blind eye.

### Conclusion

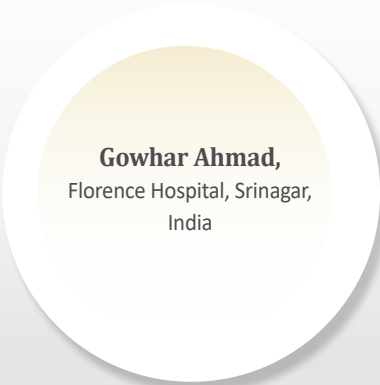
More than 8 years have passed obits happy pain free has a good looking prostheses CT and MRI scan brain normal ultrasound liver normal. If we deal with a case of a c glaucoma not responding to usual a glaucoma medication please does b scan a tonic up solid retinal detachment and subsequent mnrbi brain?

### Keywords:

Progress and painless visual field loss, Para central scotoma, Blued vision

### Biography

Dr.Gowhar Ahmad is a senior consultant from the Florence Hospital, Chanapora, and Srinagar Kashmir, India. He has published a lot of papers and attended conferences in different countries.



**Gowhar Ahmad,**  
Florence Hospital, Srinagar,  
India

**Received:** 26<sup>th</sup> October, 2022; **Accepted:** 31<sup>th</sup> October, 2022; **Published:** 13<sup>th</sup> December, 2022