

4th European Otolaryngology-ENT Surgery Conference

&

3rd International Conference on Craniofacial Surgery

August 15-17, 2019 Rome, Italy

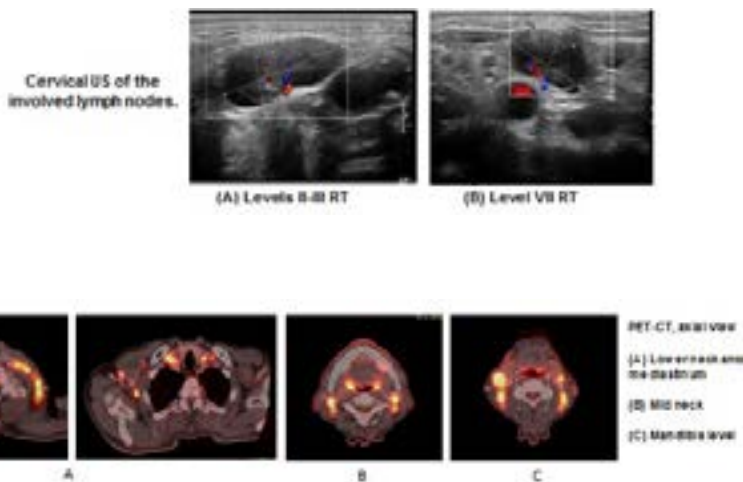
Mixed type tumor Histiocytic Sarcoma & Langerhans Cell Sarcoma

Wallach Leemor¹, El Khatib Nidal², Szvalb Sergio MD² and Merchavy Shlomo MD¹

Department of Otolaryngology and Head & Neck Surgery, Ziv Medical Center, Israel

Department of pathology, ZIV Medical Center, Israel

We present a case of a 70 Year-old man with night sweats, weight loss, bilateral leg pain and neuralgia with a single physical examination finding of bilateral enlarged cervical lymph nodes. He was diagnosed with a rare type of Langerhans Cell Sarcoma (LCS) mixed with Histiocytic Sarcoma (HS). Both malignancies are hard to diagnose because they are rare and have non-specific symptoms. Furthermore, HS has similar features as Non-Hodgkin's lymphoma and other B-cell Lymphomas. The diagnosis in this case was made by an open biopsy from the left neck, level IV, which revealed a 19mm hard lymph node without necrosis or adhesions. The pathology showed paracortical and interfollicular large cell neoplasm, with intermediate/divergent phenotype between HS (Lysozyme+/CD68-KP1+) and LCS (CD1a+/Langerin+). PET-CT showed a disseminated disease; therefore, the patient was not a candidate for surgery. In conclusion, although this diagnosis is extremely rare, we should always include it in the differential diagnosis process of a suspicious cervical lump or mass..



Biography

Leemor Wallach is an intern in Ziv Medical Center. She received her MD from Tel -Aviv University and B.Sc. in Animal Science from the Hebrew University. She graduated with honors. Leemor was an Army medic, worked as a vet's assistant in a veterinary hospital, a doctor's assistant in the ER and managed a surgeon's clinic. She intends on pursuing a career as an otolaryngologist.

leemor.wallach@mail.huji.ac.il