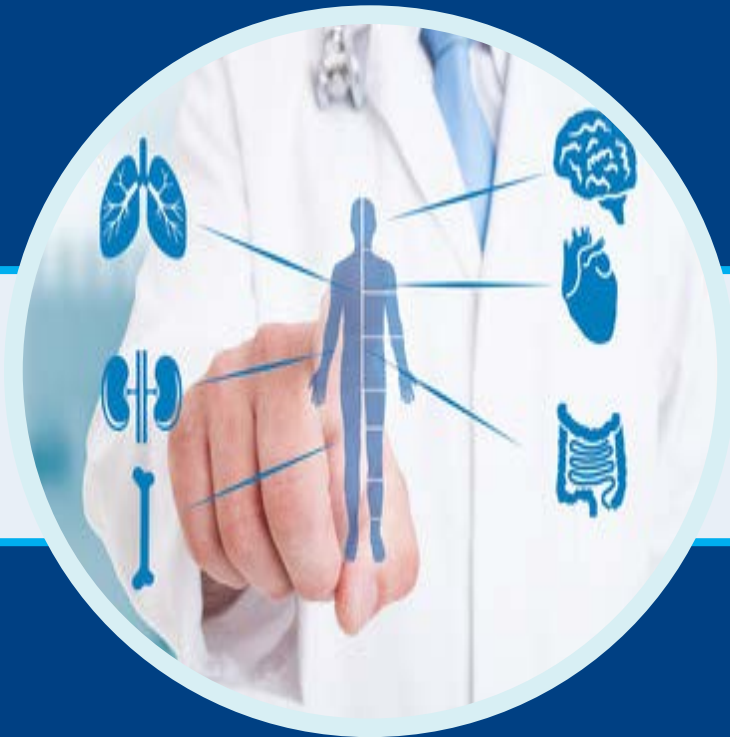

EuroSciCon



**Internal Medicine
2023**

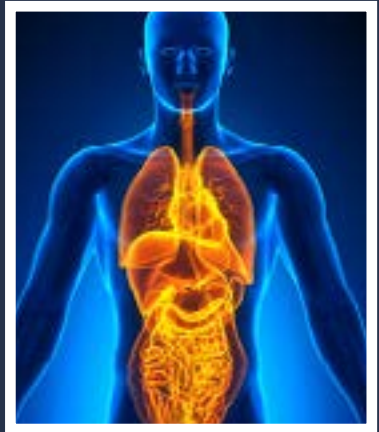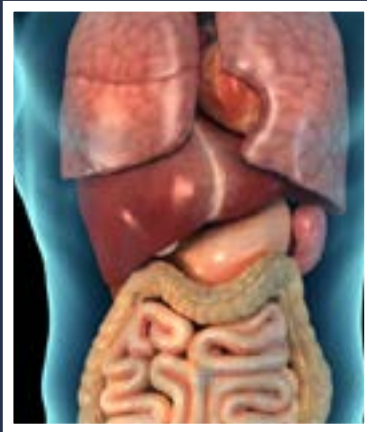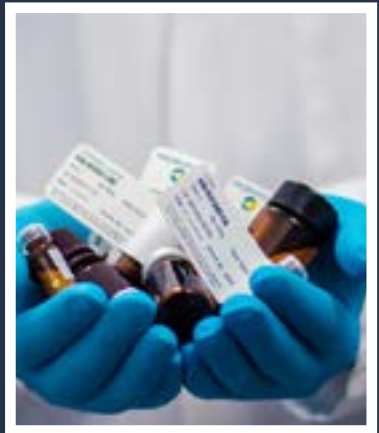
**11th International Conference on
Internal Medicine & Patient Care**

July 20, 2023 | Webinar



11th International Conference on Internal Medicine & Patient Care

Keynote Tracks



July 20, 2023
Webinar

July 20, 2023

Webinar

Journal of Palliative Care & Medicine

ISSN: 2165-7386

Satisfaction and Experiences in Telehealth of the Filipino Patient and Caregiver: A Sequential Explanatory Single-Center Study

Christine Gertrude Tan*University of Santo Tomas Hospital, Philippines***Abstract**

Introduction: The CoVID-19 pandemic paved a way for telehealth and was considered as the “new normal”. Satisfaction influences the decision making users, but satisfaction does not solely come from the patient but also from caregivers. This study determined patient and caregiver satisfaction and experiences with the use of telehealth services.

Methods: A cross-sectional sequential explanatory design was utilized. Patients and caregivers from May to August 2022 at the University of Santo Tomas Hospital Department Of Internal Medicine initially answered the Telemedicine Satisfaction Questionnaire (TSQ), followed by exploring their experiences with telehealth through key informant interviews. A score of ≥ 4 over 5 from the TSQ showed a higher satisfaction score. Pearson R correlation, Spearman Correlation, Fisher-Freeman-Halton Exact Test, and Mann Whitney U test were used in the quantitative phase, while inductive thematic analysis was utilized for the qualitative phase.

Results: A total of 182 patients and caregivers participated in the first phase, while 11 respondents were interviewed. There were 146 patients and 36 caregivers with mean age of 41.48 ± 12.7 . The TSQ scores ranges from 4.32 to 4.62, and 96.7% of the participants had overall score of ≥ 4 over 5. Age and location had significant association with telehealth services. The qualitative phase introduced three themes 1) Telemedicine: Improving Quality of Life in the Digital Age, 2) Limiting Consequences of the Primary Setup Shift in Consultations, and 3) Nuances of Traditional and Modern Health Services.

Conclusion: Telemedicine improved the overall quality of life of patients and caregivers. Creating a convenient, efficient, economical, safe, and comfortable health care service where actual needs of patients and caregivers are met.

Biography

Christine Gertrude Tan is resident in training in Internal Medicine at [University of Santo Tomas Hospital](#), Philippines. She is a graduate of Bachelor of Science in [Nursing](#) and Doctor of Medicine at the University of Santo Tomas Hospital.

christine_tan8@yahoo.com

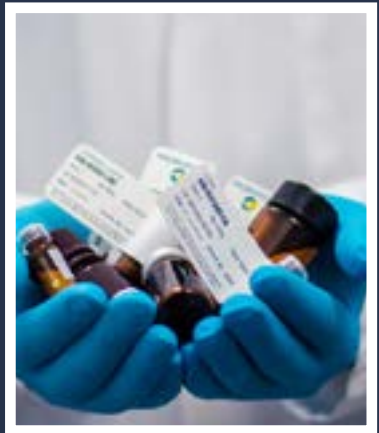
Received: February 11, 2023 | Accepted: February 14, 2023 | Published: August 17, 2023



11th International Conference on Internal Medicine & Patient Care

Scientific Tracks

July 20, 2023
Webinar



July 20, 2023

Webinar

Journal of Palliative Care & Medicine

ISSN: 2165-7386

Case Report: Cocaine toxicity causing a multi-organ failure and serotonin syndrome

Joshua Soggi*North Manchester General Hospital, UK***Abstract**

Cocaine use has seen an increase over the years and is associated with several life-threatening complications. The way in which this happens is by blocking the uptake of specific monoamine transporters leading to its accumulation and overstimulation within the post-synaptic receptors. It's important to distinguish the symptoms of acute cocaine toxicity early to ensure appropriate treatment is started as symptoms can manifest rapidly. Here we see a young gentleman presenting with findings of acute agitation and hallucinations manifesting into a cardiac arrest with a multi-organ failure and serotonin syndrome. After admission to ITU post cardiac arrest he was stepped down after a total of 55 days and made a good recovery. We aim to discuss the numerous pathophysiological effects cocaine can have on the body and the significance of these in acute toxicity.

Keywords: cocaine toxicity, multi-organ failure, dopamine, serotonin, norepinephrine

Biography

Joshua Soggi is a junior doctor currently working in [elderly medicine](#) at [North Manchester General Hospital](#). He is an international graduate, who has an MD from [Medical University Of Varna, Bulgaria](#).

joshuasoggi@hotmail.com**Received: June 12, 2023 | Accepted: June 14, 2023 | Published: August 17, 2023**

July 20, 2023
Webinar**Journal of Palliative Care & Medicine**
ISSN: 2165-7386

The readiness of medical students to take part in elimination of medical consequences of the earthquakes

Sofia Loginova*Pirogov Russian National Research Medical University, Russia***Abstract**

Statement of the Problem: Nowadays the world is seismic unresistant, earthquakes lead to the appearance of a large number of victims. First aid is extremely important due to destruction of medical infrastructure. Medical students can be involved in providing first aid and strengthening medical care. That's why a survey on the basis of first aid in earthquakes is important. The survey was completed by 55 students: 52,73% - first, 10,91% - second, 25,45% - third year, 7,27% - fifth and 3,64% of the sixth years. Among all, 50 students do not work. Only 36 are ready to participate in the elimination of the consequences of the emergency, among these 25 are the first year students. Perhaps, this is because they just started to study and do not understand completely what an emergency situation is. 90% know about earthquake safety rules. Approximately 73% know the causes of irretrievable and health losses, incorrect answers were in the first year students. But 20 of them know that approximately 15-25% among injured are children, which is the best result among all students. Everybody knows the crash-syndrom and combined injury, only half of students know that renal failure and shock is a part of them. 53%, mainly of the first year, know about necessity of a tourniquet before removing victims from the rubble. 91% knows that the best position to transport victims is supine on the rigid stretcher.

Conclusion

The first year students know first aid theory better but without experience, while senior students have more specific information. To strengthen the readiness of all students, a thematic practice is required.

Loginova S.D., student of the third year of N.I. Pirogov Russian National Research Medical University; ORCID: 0000-0002-9633-2506

Kovaleva E.M., student of the fifth year of N.I. Pirogov Russian National Research Medical University; ORCID: 0000-0001-6779-3146

Muradova M.M., student of the third year of N.I. Pirogov Russian National Research Medical University; ORCID: 0000-0002-1007-8034

Kostyuchenko M.V., Doctor of Medical Sciences of the Disaster Medicine department of N.I. Pirogov Russian National Research Medical University; SPIN-code: 8198-2090, AuthorID: 691432, ORCID: 0000-0003-1069-7190

All of us have scientific interests in the field of emergency medicine and disaster medicine.

Biography

Sofia Loginova is affiliated to [Pirogov Russian National Research Medical University](#). She is a recipient of many awards and grants for her valuable contributions and discoveries in major area of [emergency medicine](#) research.

feklasv@icloud.com**Received: February 11, 2023 | Accepted: February 14, 2023 | Published: August 17, 2023**

July 20, 2023

Webinar

Journal of Palliative Care & Medicine

ISSN: 2165-7386

DVT with citalopram induced SIADH in a patient with Parkinson's disease: A case report

Afaf Albalawi,
Tabuk University, Saudi Arabia

Abstract

Introduction: Citalopram is effective for dementia-related agitation, but little evidence supports its use for dementia with Lewy bodies. Hyponatremia and other SSRI side effects increase venous thromboembolism (VTE) risk. SSRI use can directly (platelet aggregation, venous stasis) or indirectly (obesity, sedation) cause DVT

Case presentation: An 86-year-old woman functionally declined with Parkinson's disease, hypertension, diabetes mellitus, hyperlipidemia, and osteoporosis presented to the emergency department with altered mental status, decreased oral intake, generalized weakness, and left lower leg swelling. Medications included gliclazide, metformin, valsartan, and atorvastatin, with no medications for Parkinson's disease. No history of deep vein thrombosis (DVT) or pulmonary embolism was noted. Echocardiogram 5 months prior showed normal systolic function; ejection fraction, 55%–60%; and Grade 1 diastolic dysfunction. At presentation, the patient was disoriented and lethargic. Blood pressure: 104/51 mmHg; random blood glucose: 125 mg/dl; and sodium: 123 mg/dl. Other parameters were normal, including adrenal function, with no sign of malignancy or autoimmune disease. Brain computed tomography showed age-related changes. Doppler ultrasound revealed DVT in the left lower leg. Four weeks prior, the selective serotonin reuptake inhibitor (SSRI) citalopram was started for behavioral changes (agitation, resistance to care, hallucinations, repetitive vocalizations, and

insomnia), resulting in restlessness and vocal changes (low-volume speech). Two days prior, citalopram was discontinued

due to excessive fatigue. The patient was admitted and managed with hypertonic solution and intravenous heparin, with other medications held. After 3 days, sodium normalized. The patient was discharged on oral apixaban (2.5 mg, BID), and all home medications were resumed except gliclazide. At follow-up, plasma sodium remained normal.

Conclusions and significance: SSRIs should not be first-line

treatments for behavioral symptoms in Parkinson's disease with Lewy body dementia. SSRIs combined with sulfonyleurea increase hyponatremia risk. In older patients with functional decline, VTE prophylaxis should be initiated prior to SSRIs.

Recent Publications

Mirghani, Hyder, Samar Aljohani, and Afaf Albalawi. "Dementia and adherence to anti-diabetic medications: a meta-analysis." *Cureus* 13.4 (2021);

Afaf Albalawi MD, Flavia Brancusi MHS, Frederic Askin MD, Robert Ehsanipoor MD, Jiangxia Wang MS, MA, Irina Burd MD, PhD, Priya Sekar MD, MPH. Placental Characteristics of Fetuses with Congenital Heart Disease. *Placental Characteristics of Fetuses with Congenital Heart Disease*. 2017 Mar; 36(5): 965-972. Pub Status: Published.

Afaf Albalawi MD1, Asha Marhatta MD2, Johns A. Farens MD1. (October 2017). Diet-induced Hypercarotenemia: A case report Poster presented at: 2017 ANNUAL SCIENTIFIC MEETING, ACP Connecticut Chapter; Southington, CT, USA.

Sapna Raghunathan, MD1, Afaf Albalawi, MD1, Yiannis Apergis, MD1 and Jonathan Fillmore, MD2, (April 2017). Mifepristone Prior to Surgery for the Management of ACTH Dependent Cushing's Syndrome of Unknown Etiology Poster presented at: 99th Annual Meeting of the Endocrine Society; Orlando, FL, USA.

Afaf Albalawi MD and Christina Prather MD. (May 2019). Were depression meets aggression: The intersection of SSRI use and Parkinson's disease Poster presented at American Geriatric Society 2019 Annual Scientific Meeting; Portland, OR, USA

Biography

Afaf Albalawi is a consultant in [internal medicine](#), geriatric and [palliative hospice medicine](#) at Tabuk University, Saudi Arabia

afaf.albalawi@ut.edu.sa

Received: February 24, 2023 | Accepted: February 27, 2023 | Published: August 17, 2023

July 20, 2023
Webinar**Journal of Palliative Care & Medicine**
ISSN: 2165-7386

High Risk ileal mesenteric gastrointestinal stromal tumor masquerading as intestinal fistula & intra abdominal abscess formation: A Case Report

Ramon Jr. Guelos*The Medical City, Philippines*

Abstract

Gastrointestinal Stromal Tumors (GISTs) occur in less than 1% of all digestive tract tumors. Tumor perforation, GIST related fistulas and intra-abdominal abscess phenomenon are rare and occur as a result of GISTs' propensity to cause mucosal ulceration. This allows gut bacteria to enter the systemic circulation which increases the risk for bacteremia.

This case report investigated a 53-year-old male whose initial symptoms included fever, chills, leukocytosis, abdominal pain and a palpable right lower quadrant mass. Enhanced computed tomography (CT) scan of the abdomen revealed necrosis and abscess formation at the right lower quadrant. An ileal mass (7x10.7x12.5 cm) that formed a fistula between the tumor & small bowel with mesenteric thickening. Patient underwent exploratory laparotomy, segmental jejunal resection with end-to-end anastomosis, excision of mesenteric mass and drains. Imatinib mesilate 400mg orally once a day was initiated as adjuvant treatment.

Findings of intestinal fistula and intra-abdominal abscess formation in association with an Ileal GIST should raise a concern both for metastatic disease and possible infectious complication or sequelae. A timely and appropriate initiation of intravenous (IV) antibiotics and resection of the intraabdominal mass is tantamount to increase chances of survival.

Biography:

Dr. Ramon Guelos Jr is a 2nd year Medical Resident in Internal Medicine at [The Medical City Iloilo](#), Philippines. He is a graduate of Bachelor of Science in [Nursing](#), Cum Laude last 2015 from West Visayas State University, Iloilo City and his Doctor of [Medicine](#) from Central Philippine University, Iloilo City last 2019. He underwent his Post Graduate Internship at Jose R. Reyes Memorial Medical Center, Sta. Cruz, Manila.

monguelos@gmail.com

RecReceived: March 15, 2023 | Accepted: March 17, 2023 | Published: August 17, 2023, 2022

July 20, 2023
Webinar**Journal of Palliative Care & Medicine**
ISSN: 2165-7386

Treatment outcomes with tocilizumab in adult patients with severe and critical COVID-19 pneumonia of mariano marcos memorial hospital and medical center: A Retrospective Study

Sheryll J. Pascual*Mariano Marcos Memorial Hospital & Medical Center, Philippines*

Objectives: As SARS-Cov-2 infection leads to the development of cytokine storm syndrome, Tocilizumab, a biological agent that inhibits the cytokine interleukin 6, was seen to have clinical effects in COVID-19. Hematological markers used to determine clinical severity based on current literature revealed that ALC, CRP, Ferritin, LDH and D-dimer levels were associated with COVID severity. We aimed to determine the association of recovery and mortality rate with Tocilizumab based on inflammatory markers significant in COVID-19 infection such as CRP, LDH, D-dimer, Ferritin, Absolute Lymphocyte Count and associate comorbidities of patients to mortality.

Methods: This was a single-center retrospective study which includes 101 t patients diagnosed with COVID-19 Severe and Critical Pneumonia. Independent Sample T-test, Mann-Whitney U test and Fisher's Exact/Chi-square test was used. Odds ratio was computed to determine significant predictors for mortality.

Results: Diabetic patients were 5.3 times more likely to and Chronic Kidney Disease was 18 times more likely to have mortality. For every unit increase in patient's D-dimer and CRP during admission, the odds of mortality also increase by 0.02% and 0.73%,

0.01, unit decrease in patient's Absolute

0.02,w Lymphocyte Count during admission, the odds of

Mortality decrease by 17.86%. Every 0.01-unit increase in patient's ABG PaO₂/FiO₂ during admission, the odds of mortality decrease by 10.1%. In patient's D-dimer, Ferritin, CRP and LDH prior to discharge, every unit increase, the odds of mortality also increase by 0.03%, 0.18%, 2.29% and 0.58, respectively. Every 0.01-unit increase in patient's ALC prior discharge, mortality decrease by 13.35%.

Conclusion: Tocilizumab treatment was associated with reduction in the mortality of patient with Severe and Critical COVID

Pneumonia in association with inflammatory markers, LDH, Ferritin, D-dimer and CRP, improvement of ABG PaO₂/FIO₂ and decreased infiltrates by chest x-ray. Mortality from COVID-19 Pneumonia was associated with CKD, DMT2, and HCVD

Recent Publications

Manalo, G., Lu-Reyes, J., Carabacan C.,

Santos, M., Pascual, S. Therapeutic Plasma

Exchange as a Treatment for Central Pontine

Myelinolysis in a 41 year old Male with Chronic Renal Insufficiency: A Case Report; Philippine Journal of Internal Medicine (Volume 60 No. 4)

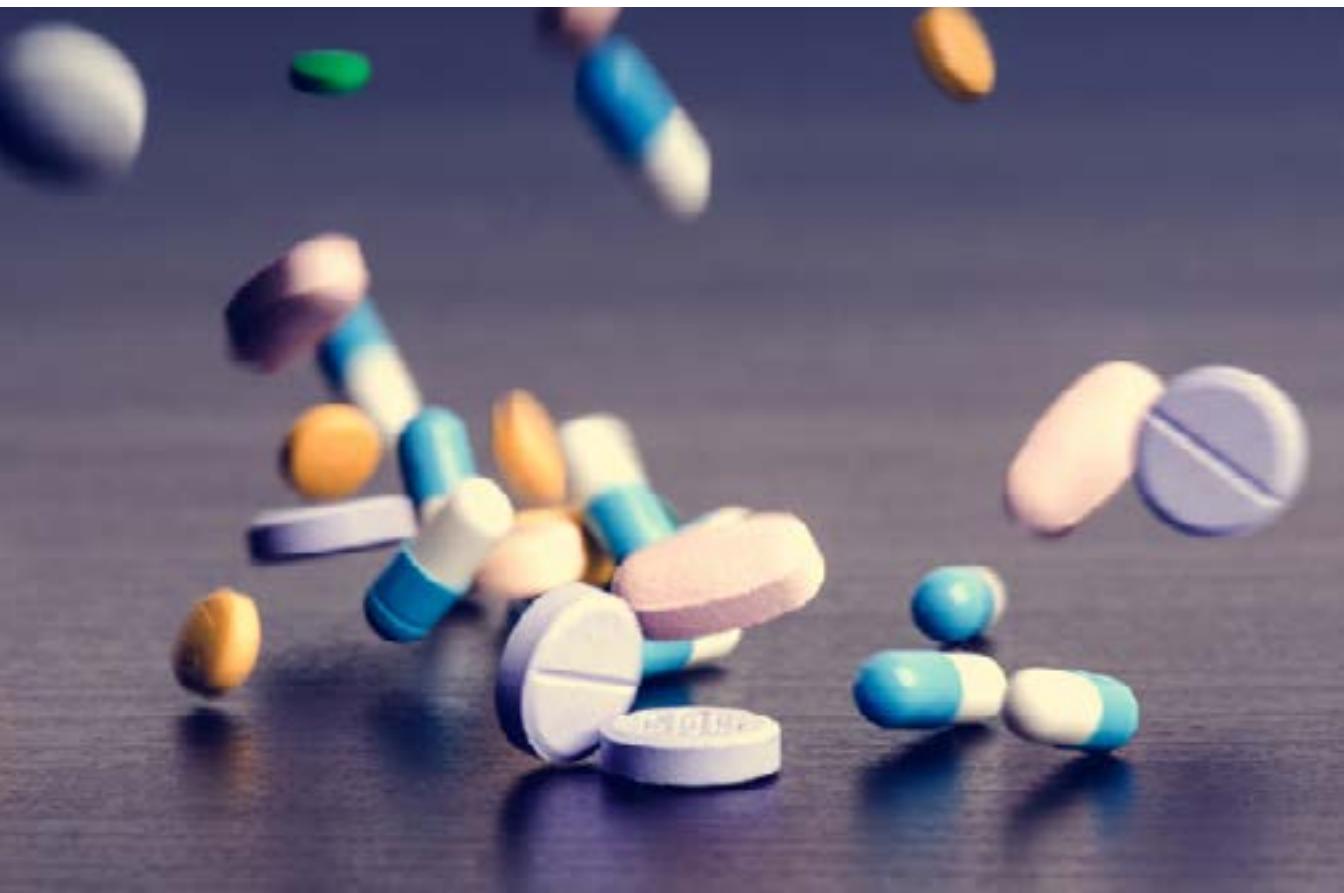Biography

Sheryll J.Pascual MD in Internal Medicine Physician at [Mariano Marcos Memorial Hospital and Medical Center](#), Philippines. She finished her residency training in [internal medicine](#) last December 2022 and Currently Medical Officer on the said institution.

pascual.sheryll2293@gmail.com

Received: April 12, 2023 | Accepted: April 14, 2023 | Published: August 17, 2023²





Book Mark Dates

12th International Conference on
Internal Medicine & Patient Care

Apr 04-05, 2024 | Madrid, Spain

Internal Medicine 2023